

Clinicopathological profile and outcome of Infection-related glomerulonephritis (IRGN): A Single Center Experience.

Senthilkumar Kasi*

Department of Physics, NIT Meghalaya, India

*Corresponding author: Senthilkumar Kasi, Department of Physics, NIT Meghalaya, India, Tel: 8056659065; E-mail: senthilvand@gmail.com

Received date: March 28, 2021; Accepted date: September 8, 2021; Published date: September 18, 2021

Citation: Kasi S K (2021) Clinicopathological profile and outcome of Infection-related glomerulonephritis (IRGN): A Single Center Experience. J Nephrol Urol Vol.5 No.4.

ABSTRACT

Aim

Infection-related glomerulonephritis (IRGN) is an immunological renal injury due to current or recent infections. With the changing face of IRGN over the years, renal biopsy has attained an important role in diagnosing and differentiating this disease from others as well as prognosticating the long-term outcomes.

Materials and Methods

This prospective study conducted in a tertiary health care center in south India includes patients with biopsy proven IRGN who presented between October 2017 to August 2019 and their outcomes at 6 months were analyzed.

Results

All the patients whose kidney biopsy was suggestive of IRGN were included. Of the 105 patients suspected and screened, eighty two (82) patients were proved to have IRGN. Mean age of presentation was 49.6 years with slight male preponderance (male 43, female 39). About 31.8 % (26) of patients had diabetes. The skin was the most common site of infection 39% (32) followed by respiratory tract infection 22% (18). Hypocomplementemia was present in 90% of patients. Nephrotic range proteinuria was seen in 54.9% (45) cases. About 4.8% cases were proven to have IgA dominant IRGN. 69.5 % (57) of patients had renal failure at presentation, among them 28% (16) required renal replacement therapy. Complete renal recovery was seen in 67% (55) of patients, 14.09% (11) of the patients progressed to chronic kidney disease at 6 months of follow-up and 9.75% (8) of patients reached end-stage renal disease. Oral steroids were given in 37.8 % (31). Around 10.75% (9) patients had persistent proteinuria despite normal renal function. IRGN in adults may no longer be considered as a glomerular disease with favorable outcome and significant number of patients (23.75%) progress to chronicity following this disease.

Keywords: Infection-related glomerulonephritis, renal biopsy, renal failure.

Introduction

Infections have long been known to be associated with renal injury. As early as the 17th century, bloody urine and in some cases death were observed in association with scarlet fever. In the 19th century, Wells, Bright, and Miller all independently reported anasarca or clinical findings of nephritis in patients with scarlet fever [1-4]. Bright recognized that patients with this form of renal disease (acute nephritis) were more likely to have a benign outcome than those with nephrotic syndrome or uremia. In 1881, the streptococcus bacteria was isolated and recognized independently by Pasteur and Sternberg. In the past, the majority of such cases was related to recent infection with nephritogenic streptococcal strains and was referred as post infectious glomerulonephritis (PIGN) [5]. As the incidence of *Streptococcus pyogenes* infection in developed countries declined, other causative pathogens were recognized more frequently and renal involvement was observed with ongoing infection. Infection related glomerulonephritis (IRGN) is an immunologically mediated glomerular injury triggered by renal or extra renal infection [6]

Emerging risk factors for IRGN identified in the recent studies include diabetes mellitus, alcoholism, HIV infection, malignancy, and parenteral drug abuse. With the changing picture of IRGN over the years, renal biopsy definitely has an important role in differentiating this disease and defining long term outcome.

MATERIALS AND METHODS

In this prospective, observational study, consecutive patients with suspected IRGN presented to the Department of Nephrology, in a single tertiary care hospital at Chennai, Tamilnadu between October 2017 and August 2019, included in this study based on the presence of at least two out the three criteria given below:

- Clinical or laboratory evidence of preceding (4 weeks) or ongoing infection
- Low complement levels C3 (<80mg/dl) & C4 (<10mg/dl) at presentation

- Active urinary sediments (red blood cells [RBCs], RBC casts, and white blood cell casts) with or without renal dysfunction.

The patients with clinical or laboratory evidence of secondary GN (ANA /symptoms and signs of systemic disease) or a past history of other GN or chronic kidney disease (CKD) were excluded from the study.

Their outcome at six month was analyzed.

Indications for kidney biopsy

- Presentation as RPGN (Rapidly Progressive Glomerulonephritis)
- AdultonsetNephroticsyndromewith/withoutrenal failure.
- Acute Nephritic Syndrome without obvious ongoing/preceding infections, negative ASO titers, normal C3 and C4.
- Need for RRT on presentation with normalized kidneys & Proteinuria.

All the biopsies were performed under real-time ultrasonography guidance using the Bard® Max-Core disposable Core Biopsy Instrument. At least, two cores were taken and sent for light microscopy (LM) and IF in all cases.

All renal biopsy samples were processed according to the standard techniques of LM and IF. For each patient, six slides, stained with hematoxylin and eosin, Masson's trichrome, periodic acid schiff (PAS), and Jones methanamine silver were reviewed. Systematic analysis on the morphologic changes of glomeruli, tubules, interstitium, and vessels was done according to the practical standardization in renal biopsy reporting. IF staining was performed on 3 µm cryostat sections using polyclonal fluorescein-isothiocyanate conjugated antibodies to IgG, IgM, IgA, C3, C1q, , kappa and lambda. The histopathological LM diagnosis of IRGN was made by the presence of typical endocapillary or endocapillary with mesangial proliferation with or without the presence of neutrophilic infiltration depending on the stage of the disease when the patient underwent the biopsy.

This was coupled with the IF findings of typically high intensity staining for C3 with or without the presence of staining for other Immunoglobulins. The diagnosis of IgA dominant IRGN was made on the basis of staining on IF, in which IgA staining was the sole or dominant Ig deposited in glomeruli, with or without weaker staining for IgG and/or IgM. There was typically high intensity staining for C3 in these cases, which was either stronger than or equal to IgA in all the cases. The patients were followed up clinically and with relevant laboratory investigations every weekly for the first month, every monthly till six months.

RESULT

A total of 105 patients were suspected and screened for IRGN out of which 82 patients were confirmed to have IRGN and included in the final analysis. Eight patients were excluded as they did not have a minimum 6 months follow-up and eleven patients had an alternate diagnosis after biopsy. Four patients were found to have underlying CKD and hence were not included in the final analysis. Among the 82 patients who underwent a renal biopsy, four patients showed glomerular

dominant or codominant IgA deposits and were classified as IgA dominant IRGN.

Age at presentation in years (age range)	40-55 years
Male: female	1.1:1
Number of adults (>18 years of age)	70
Nephritic syndrome	26.8%(22)
Nephrotic syndrome	54.9%(45)
Subnephrotic	15.8%(13)
Nephritic-nephrotic syndrome	2.5%(2)
Hypertension	42.6(35)
Diabetes mellitus	31.8% (26)
Renal failure requiring RRT	19.6% (16)
Documented preceding infection	74.2%(61)

Table 1. Demographic details and clinical features of patients at initial presentation.

57 patients out of 82 (69.5%) had renal failure at presentation of which 16 (28 %) patients required RRT. The mean creatinine at presentation was 2.87 ± 1.65 mg/dl) with an average proteinuria of 3 g/24 h. 90.2 % (74) of patients had low C3 levels and C4 levels were low in 18.3% (15) at presentation.

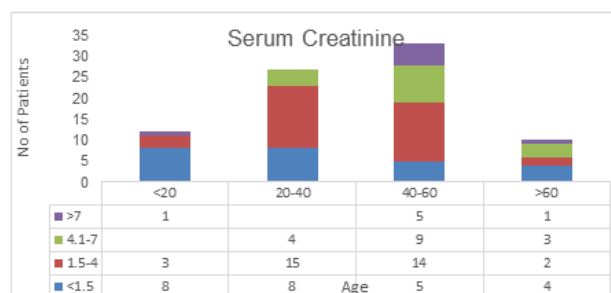


Figure 1: Renal function on admission based on serum creatinine

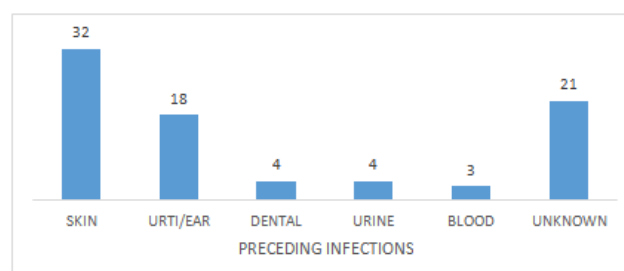


Figure 2: Sites of preceding infections in patients with infection related glomerulonephritis

Histopathology

Of the 105 cases included in the final analysis, 82 patients fulfilled one of the indications for renal biopsy. The most common indication for biopsy was nephrotic range proteinuria [Figure 3].

The most common histopathological presentation was the typical endocapillary proliferation as described in the classical poststreptococcal GN. Diffuse proliferative changes, which included mesangial proliferation and endocapillary proliferation, were seen in 81.8 % (71) of patients. Crescentic glomerulonephritis (>50% crescents) was seen in 9.75 % (8) of patients. Occasional cellular crescents (<50%) were seen in 21.9 % (18) of patients. On IF, the most common staining was C3 with IgG. [Figure 3]. Of the total 82 patients included in this study, 23.1% (19) patients showed the presence of predominant C3 deposition with absent Ig staining. 4.8 % (4) patients showed IgA dominant IRGN, 58 % (48) patients had codominant C3 and IgG deposition.

Light microscopy	Age			
	<20	20-40	40-60	>60
Crescentic IRGN>50% crescents	-	2	4	2
DPGN	11	20	18	4
DPGN with <50% crescents	1	3	9	1
DPGN+DN +crescents	-	-	3	1
MES.PGN	-	2	1	-

Table 2: Light microscopy

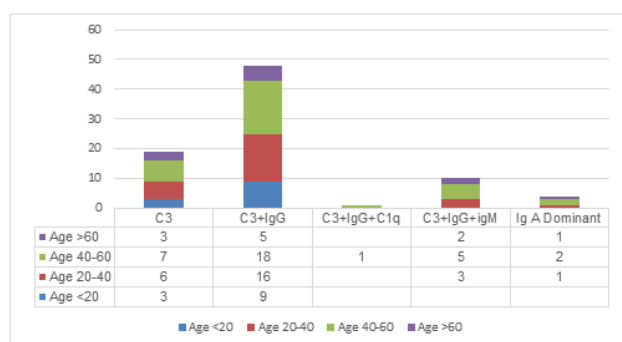


Figure 3: Frequency of immune deposits in renal biopsy

Clinical outcome and follow up

The most common clinical outcome was complete recovery 67% (55) with no sequelae (defined as persistent proteinuria >500 mg/day for ≥6 months, hypertension, or hematuria). Persistent renal dysfunction was seen in 33 % (27) patients. Among these 9.75 % (8) patients reached ESRD at six months.

Comparison of the patients who progressed to chronic kidney disease (CKD)(eGFR <60 ml/min/1.73m² ≥3 months of presentation) with the patients who showed complete recovery,

revealed no significant characteristic differences except that the patients who progressed to CKD had higher blood pressure, nephrotic proteinuria and required RRT at presentation. Patients who presented as RPGN or had persistent renal failure received immunosuppression in the form of steroids, in many case even before biopsy diagnosis was available. Thirty one patients received steroids of these 58 % (18) had complete recovery.

DISCUSSION

Infection related glomerulonephritis is an immune-mediated renal injury, caused by previous/ongoing infections, most commonly of bacterial origin. In the past, most cases of IRGN had been described predominantly in the paediatric population usually after a bout of pyoderma or sore throat. However, over the last three decades, there has been a growing concern over the appalling shift in the epidemiology, microbiology, and ultimate clinical outcomes of the IRGN [6]

In this modern era, the developed countries have seen a progressive change in the face of this GN with larger number of adults being affected, particularly the elderly and the immunocompromised. The developing countries have a large burden of IRGN, with a relatively small numbers of the actual cases, reaching health-care facilities. The true incidence of IRGN is likely much higher as compared to the numbers described in literature as epidemiologic studies include only symptomatic patients, and it is known that subclinical IRGN is at least four times more common than clinically evident disease.[15]

Most reported series of IRGN from around the world report male predominance with male: female ratio ranging from 1.4:1 to 3:1[7-9]. Our population had a slight male predominance with the male: female ratio at 1.1:1. In the pediatric age group, the sites of infection are usually the throat or skin; however, the adult population shows a much varied site of preceding infection including upper respiratory tract, skin, lung, heart, urinary tract, teeth/oral mucosa, bone, and deep seated visceral, or somatic abscesses [6] In one study of 109 elderly patients from the United States, the four most common sites were skin (28%), lung (16%), urinary tract (13%), and upper respiratory tract (10%) [10].The teeth and gums were a common site of infection in two series of adult IRGN from Europe. In our series, the most common infection was skin 39%, unknown source 25.8% and upper respiratory tract 22%. Of note, in a majority of adult cases, the infection is not clinically evident and some patients with clinically evident infection may have negative cultures, especially following antibiotics.

In contrast to children in whom the latent period between infection and onset of renal disease is typically 1–6 weeks, in a significant percentage of adults and particularly elderly patients the infection is only discovered at the time diagnosis of IRGN, indicating that the infection may go unrecognized for some time. Hypertension is present in majority of adult patients with IRGN at presentation.[7-9] In our study patients 35 (42.6%) patients had hypertension and 26 (31.8%) who had pre-existing Diabetes. The degree of proteinuria varies from 1 to 3 g/day, Nephrotic syndrome 54.9 % (45) is the commonest clinical presentation as majority of our study population had diabetes .In our patient

series majority had microhematuria and only four patients had macrohematuria. In previous studies hypocomplementemia was seen in 35%–80% of adult patients and in 90% of the children. [6-9,10] In most patients, C3 is depressed with a normal level of C4. In our series, nearly 90 % of patients had low C3 at presentation.

The most common LM finding on renal biopsy is diffuse proliferative and exudative GN with abundant intracapillary neutrophils. In one study of 86 patients, this pattern was seen in 72% of patients, followed by focal endocapillary proliferative GN in 12% and mesangial proliferative GN in 8% of patients. Crescentic and necrotizing glomerulonephritis with >50% crescents is rare, and affected only 5% of cases in the above study [6], although focal crescents involving 20% of glomeruli are encountered in up to a quarter of cases [6-9]. In our series, the most common LM pattern was the typical diffuse endocapillary proliferative GN seen in 81.8% (71) of the patients.

The next most common pattern seen was a diffuse endocapillary proliferation with crescents (<50%) seen in 21.9% (18) of the patients. Crescentic GN >50% crescents was seen in 9.7% (8) of the patients. We had underlying diabetic nephropathy in 4 (4.8%) biopsy specimens. We also had 7 (8.6%) patients who had underlying kidney dysfunction superimposed by IRGN resulting in worsening of renal failure. 3 (40%) patients of this population had progression to ESRD over a period of 6 months after the episode of IRGN. In our series majority of patients had renal failure (> 90%) on presentation, and it is higher in elderly patients than younger adults. In contrast to children in whom the need for dialysis for severe acute renal failure is uncommon, close to a half of elderly patients required dialysis at the initial presentation for uremic symptoms and/or fluid overload [11-14]. In our study 19.6% (16) needed dialysis. Of the patients whom dialysis was initiated nine patients had recovery of renal function whereas seven had either partial or non recovery or progression to CKD. In the study by Sakthirajan et al [16] in patients with crescentic IRGN, renal replacement therapy was given in 53.2% of patients, steroids were given in 78.7% of patients along with appropriate antibiotic therapy, but steroid therapy had no significant impact over the renal outcome. The complete renal recovery occurred only in 25.5% of cases, progression to CKD was found in 40.4%. We had treated 37.8% of patients with steroids as they had presented as RPGN or persistent renal failure. In this cohort of adult patients had severe form of IRGN, hence there was a need for RRT and immunosuppression.

CONCLUSION

IRGN is common in developing countries and it usually presents as acute nephritic syndrome. Clinical diagnosis is often difficult in adults & older patients as infection may be ongoing or its site may not be obvious. IRGN can present with severe renal impairment requiring dialysis or can have worsening of pre-existing renal dysfunction. Renal biopsy plays an important role to diagnose the underlying GN and to assess the prognosis and should be considered early, especially in patients with renal failure or an initial requirement of RRT or severe proteinuria/

persistent proteinuria. Initial RRT requirement and crescentic IRGN in biopsy may predict a poor outcome and greater chances of progression to CKD. This study is limited by the fact that it may not be a true representation of the disease in the community and represents only the tip of the iceberg. We were unable to subject the biopsy samples for electron microscopic examination, which may have throw light on various other histopathological features of this disease.

REFERENCES

1. Von Poelnitz MA, De Scarlatina T III, (1762), Opera Medico-Physica, Tract
2. III. Vienna, Austria: Trattner.
3. Miller J, (1849), The kidney in its relation to scarlatina. *Lancet*, 54, 1, 57, 113, 124, 197, 281, 524, 685.
4. Bright R, (1836), Tabular view of the morbid appearances in 100 cases connected with albuminous urine. *Guy's Hosp Rep*, 380-489.
5. Wells CD, (1812), Observations on the dropsy that succeeds scarlet fever. *Trans Soc Improve Med Chir Knowledge*, 3:167-186.
6. Montseny JJ, Meyrier A, Kleinknecht D, Callard P, (1995), The current spectrum of infectious glomerulonephritis. Experience with 76 patients and review of the literature. *Medicine (Baltimore)*, 74:63-73.
7. Nasr SH, Radhakrishnan J, D'Agati VD, (2013), Bacterial infection-related glomerulonephritis in adults. *Kidney Int*, 83:792-803.
8. Montseny JJ, Meyrier A, Kleinknecht D, Callard P. (1995), The current spectrum of infectious glomerulonephritis. Experience with 76 patients and review of the literature. *Medicine (Baltimore)*, 74:63-73
9. Moroni G, Pozzi C, Quaglini S, Segagni S, Banfi G, Baroli A, et al. (2002), Long-term prognosis of diffuse proliferative glomerulonephritis associated with infection in adults. *Nephrol Dial Transplant*, 17:1204-11.
10. Haas M, Racusen LC, Bagnasco SM, (2008), IgA-dominant postinfectious glomerulonephritis: A report of 13 cases with common ultrastructural features. *Hum Pathol*, 39:1309-16
11. Nasr SH, Fidler ME, Valeri AM, Cornell LD, Sethi S, Zoller A, et al, (2011), Postinfectious glomerulonephritis in the elderly. *J Am Soc Nephrol*; 22:187-95.
12. Keller CK, Andrassy K, Waldherr R, Ritz E, (1994), Postinfectious glomerulonephritis – Is there a link to alcoholism? *Q J Med*; 87:97-102.
13. Luo C, Tang Z, Chen D, Liu Z, (2011), Long-term prognosis for Chinese adult patients with acute postinfectious glomerulonephritis. *Clin Nephrol*; 76:186-94.
14. Sorger K, Gessler U, Hübner FK, Köhler H, Schulz W, Stühlinger W, et al. (1982), Subtypes of acute postinfectious glomerulonephritis. Synopsis of clinical and pathological features. *Clin Nephrol*; 17:114-28.
15. Wen YK, (2009), The spectrum of adult postinfectious glomerulonephritis in the new millennium. *Ren Fail*; 31:676-82.
16. Rodríguez-Iturbe B, Rubio L, García R, (1981), Attack rate of poststreptococcal nephritis in families. A prospective study. *Lancet*; 1:401-3.