

DAY 1

Scientific Tracks & Abstracts



3rd Edition of World Congress & Exhibition on

Vascular Surgery

May 24-25, 2018 | London, UK

DAY 1

May 24, 2018

Sessions

Abdominal Aortic Aneurysms | Techniques of Open Vascular Surgery | Thoracic Aortic Vascular Surgery | Anesthesia For Vascular Surgery

Session Chair
Geng-Long Hsu
Hsu's Andrology, Taiwan

Session Co-Chair
Wei-liang Chen
Sun Yat-sen University, China

Session Introduction

- Title:** Acupuncture aided local anesthesia for penile vascular surgeries
Chun-Kai Hsu, Taipei Tzu chi Hospital, Taiwan
- Title:** Venous insufficiency is the pivotal contributor in erectile dysfunction in males younger than 30 years
Geng-Long Hsu, Hsu's Andrology, Taiwan
- Title:** Salvage surgery for patients with recurrent oral and oropharyngeal squamous cell carcinoma involving the carotid artery
Wei-liang Chen, Sun Yat-sen University, China
- Title:** Lack of transcriptional activity of Nrf2 affects TGFb1 expression and alters collagen I and III localization within mice aortic aneurysm
Witold Nowak, Jagiellonian University, Poland
- Title:** Insight into single-nucleotide polymorphisms of toll-like receptors and the risk of abdominal aortic aneurysm formation
Agnieszka Jabłońska, Polish Academy of Sciences, Poland
- Title:** Computational fluid dynamic approach to mimic changes of blood hemodynamic in patients with acute type IIIb aortic dissection treated with TEVAR
Andrzej Polanczyk, Medical University Vienna, Austria
- Title:** Novel pilot films providing indispensable information in pharmaco-cavernosography
Chi Can Huynh, The Male Clinic, Australia
- Title:** Histone citrullination of neutrophil extracellular traps is a novel biomarker and target to inhibit progression of abdominal aortic aneurysms
Christoph Neumayer, Medical University of Vienna, Austria
- Title:** Bovine pericardial grafts for the management of aortic graft infections: Single center experience
Ihor Huk, Medical University Vienna, Austria
- Title:** A comparison of major amputation rates and outcomes for indigenous and non-indigenous Australians in a major tertiary hospital
Tejas P. Singh, James Cook University, Australia
- Title:** Locked temporary vascular shunt
Haibo Lu, Hospital to the People's Liberation Army Hong Kong Garrison, China

DAY 1
May 24, 2018

Sessions

Abdominal Aortic Aneurysms | Techniques of Open Vascular Surgery | Thoracic Aortic Vascular Surgery | Anesthesia For Vascular Surgery

Session Chair
Geng-Long Hsu
Hsu's Andrology, Taiwan

Session Co-Chair
Wei-liang Chen
Sun Yat-sen University, China

Session Introduction

Title: Critical appraisal of international guidelines for the screening and treatment of asymptomatic periphery artery disease: who decides the non-evidence corner

Qinchang Chen, Sun Yat-sen University, China

Title: Affecting factors of residual stenosis after carotid artery stenting

Lingyun Jia, Xuanwu Hospital of Capital Medical University, China

Title: The aXurge© project. Feasibility of a mathematical platform for abdominal aortic aneurism (AAA) sizing, risk assessment and surgical planning

Maurizio Domanin, University of Milan, Italy

Title: Structured resistance exercise and remote ischemic preconditioning for moderate intermittent claudication

Shannon Hernon, National University of Ireland, Ireland

Title: New developments in the treatment of carotid body tumors from Ecuador where they are common what is the etiology and the best treatment tricks

Oscar Ojeda, Hospital Eugenio Espejo, Ecuador

Title: Post-PTA dissection repair above and below the knee

Luboš Kubíček, Masaryk University, Czech Republic

EuroSciCon

Vascular Surgery 2018

May 24-25, 2018
London, UK

Chun Kai Hsu et al., J Vasc Endovasc Therapy 2018, Volume 3
DOI: 10.21767/2573-4482-C1-002

ACUPUNCTURE AIDED LOCAL ANESTHESIA FOR PENILE VASCULAR SURGERIES

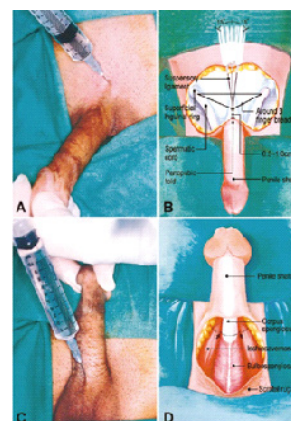
Chun Kai Hsu¹ and Geng Long Hsu^{2,3}

¹Taipei Tzu chi Hospital, Taiwan

²Hsu's Andrology, Taiwan

³National Taiwan University, Taiwan

Despite topical anesthetic blockage for penile surgeries has been substantially reported in the medical literature, a heavy intravenous sedation is unexceptionally used. We sought to report an acupuncture assisted pure local anesthesia on the ambulatory basis under several methods of topical blocks. From 1989 to 2017, 3223 men (ages 19 to 91 years) received our ambulatory penile vascular surgeries. They were categorized into the venous (n= 2867), patch (n= 323), and arterial groups (n= 33) in accordance with penile venous stripping, penile autologous venous patches, and penile arterial reconstruction surgery respectively. The chosen acupoints involve Hegu (LI4), Shou San Li (LI10), Quchi (LI11), and either Waiguan (SJ5) or Neiguan (PC6). In tandem with our advanced penile anatomy, the topical blocks include proximal dorsal nerve block, peripenile infiltration, bilateral crural blockage and topical infiltration. These blockages are sufficient local anesthesia for patients with varied vascular surgeries unless a penile implant which requires bilateral cavernous nerve block. The anesthetic effects when a visual analog scale of 100 mm was used, and postoperative results were satisfactory. Common immediate side effects included puncture of the corpus spongiosum or the deep dorsal vein as well as the innominate vessel, subcutaneous ecchymosis, transient palpitations, and acceptable low level of pain. There were no significant late complications. A booster injection is advised by 4 hours before the patient registers pain again. Overall 2635 men (81.5%) require 1 to 2 booster injections. In recent three years, 23 American and European males have successfully received this acupuncture-aided local anesthesia despite they insisted general anesthesia in threads of internet consultations before their attendances. Topical nerve blockades proved to be reliable, simple, and safe, with minimal complications. They offer the advantages of less morbidity, reduced effects of anesthesia, protection of privacy, and a rapid return to preoperative daily activity.



Recent Publications

1. Hsu GL, Hsieh CH, Wen HS, Hsieh JT and Chiang HS (2003) Outpatient surgery for penile venous patch with the patient under local anesthesia. *Journal of Andrology* 24:35-39.
2. Hsieh CH, Liu SP, Hsu GL, Chen HS, Molodysky E, Chen YH, Yu HJ. (2012) Advances in our understanding of mammalian penile evolution, human penile anatomy and human erection physiology: Clinical implications for physicians and surgeons *Medical Science Monitor* 18: RA118-125.
3. Hsu GL, Molodysky E, Liu SP, Hsieh CH, Chen HC, Chen YH (2013) A Combination of Penile Venous Stripping, Tunical Surgery and Varicocelectomy for Patients with Erectile Dysfunction, Penile Dysmorphology and Varicocele under Acupuncture-aided Local Anesthesia on Ambulatory Basis. *Surgery: current research* S12:008.
4. Hsu GL, UX, Hsieh CH, Huang SJ (2013) Acupuncture assisted regional anesthesia for penile surgeries.

May 24-25, 2018
London, UK

Translation Andrology and Urology 2:291-300.

5. Hsu GL, Molodysky E, Liu SP, Chang HC, Hsieh CH, Hsu CY (2013) Reconstructive surgery for idealizing penile shape and erectile functional restoration on patients with penile dysmorphism and erectile dysfunction Arab Journal Urology 11:375–383.
6. Hsu GL, Hill JW, Hsieh CH, Liu SP and Hsu CY (2014) Venous ligation: A novel strategy for glans enhancement in penile prosthesis implantation. BioMedical Research International (2014), Article ID 923171, 7 pages <http://dx.doi.org/10.1155/2014/923171>
7. Hsu GL, Liu SP (2018) Male Reproduction Tract: Penile Structure, Chapter 63, in Volume 1: Male Reproduction, Reproduction Encyclopedia, 2018.
8. Hsu GL, Lu HC (2018). Male Reproduction Tract: Penile Structure-Erection, Chapter 64, in Volume 1: Male Reproduction, Reproduction Encyclopedia, 2018.
9. Hsu GL, Lu HC (2018). Male Reproduction Tract: Penile Structure-Erection, Chapter 64, in Volume 1: Male Reproduction, Reproduction Encyclopedia, 2018.

10. Huang PC, Hsu GL (2018). Male Reproduction Tract: Vascular surgery for erectile dysfunction, Chapter 89, in Volume 4: Reproduction Medicine, Reproduction Encyclopedia, 2018.

Biography

Since 1986, Geng-Long Hsu, formerly a clinical professor at China Medical University, has developed and refined a series of penile reconstructive surgeries, including penile venous surgery, corporoplasty and penile implantation, in tandem with advanced the penile anatomy and erection physiology. In 1993, he was promoted to the first Chair of Urology at Taiwan Adventist Hospital; he held that position until 1997 and then served as vice-superintendent of Po-Jen General Hospital until 2001. From 2001 to 2003, Dr. Hsu was a director of microsurgery potency reconstruction at Taipei Medical University Hospital. Afterward, he established his private practice—Hsu's Andrology—which serves as both a clinical practice and research center. In 2012, Dr. Hsu's latest method of penile venous stripping, administered via an ambulatory basis, was granted a USPTO patent. He hopes this surgery will be studied and practiced worldwide. I, Chun-Kai Hsu, am pleasurable to conduct this report in fellowship.

svevi0614@gmail.com

May 24-25, 2018

London, UK

Geng Long Hsu et al., J Vasc Endovasc Therapy 2018, Volume 3
DOI: 10.21767/2573-4482-C1-002

VENOUS INSUFFICIENCY IS THE PIVOTAL CONTRIBUTOR IN ERECTILE DYSFUNCTION IN MALES YOUNGER THAN 30 YEARS

Geng Long Hsu^{1,2}¹Hsu's Andrology, Taiwan²National Taiwan University, Taiwan

Erectile dysfunction (ED) concomitant with psychosis is common in adults younger than 30 years. Most cases are considered entirely psychogenic in nature. Given that penile erection-related veins constitute the principal components in erectile rigidity in defrosted cadaveric hemodynamic studies; do venogenic factors dominate psychogenic factors in males with ED? Although phospho-di-esterase-5 inhibitors have clarified current ED medical treatment, resulting in a consensus on ED pathophysiology, the understanding of the erection process may yet be just at a fledgling stage. Clinically, the psychological factor plays a significant role because placebo effect affects approximately 40% of participants in clinical trials. Based on a novel penile venous anatomy and physiological osmolality and viscosity, an apagogical hemodynamic study was conducted on defrosted cadavers. Implying penile veins themselves are the most crucial factors in erection physiology and that obviously venogenic factors are inappropriately considered cavernosal factor in the list of ED contributors. According to our vast clinical experience, the penile venous stripping method proves to be an exclusive and naturally viable treatment option. The term young ED refers to males with ED who is younger than 40 years, whereas it strictly referred to males younger than 30 years in the three publications in our evidence based report. Those young ED males account for 10.3% (35/341) to 14.3% (5/35) (average, 12.1%) of the total patients with ED who underwent penile venous stripping. Erectile function is the seamless interplay of psychological and physiological health in adult males. Penile erection related veins play a principal role in erectile rigidity in cadaveric hemodynamic studies, and veno-occlusive dysfunction is prevalent in males with ED. However, psychological factors contribute some extent in ED and they should not be ignored during ED treatment. The role of the contribution also cannot be underestimated in impotence in males younger than 30 years.

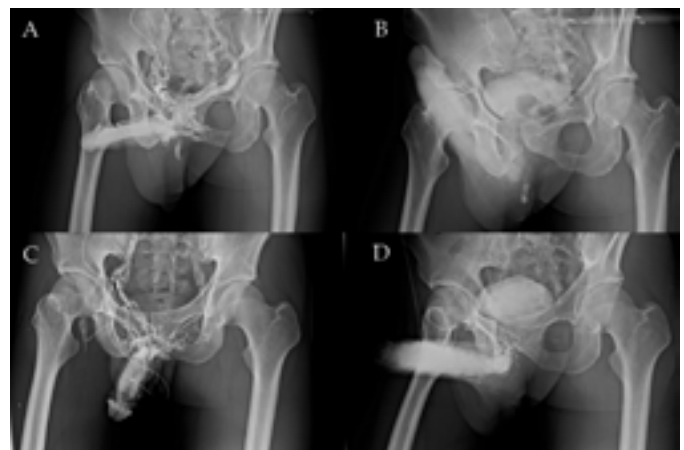


Figure 1: Excessive penile veins in impotent male younger than 30 years. (A) In this 29-year-old man, a 30°, oblique-view cavernosogram discloses extraordinary excessive penile veins which ought to be the cause of primary impotence. The first set of dual cavernosogram (anteri-or-posterior view) is obtained while a 10-ml diluted iohexol solution is intracavernously injected via a 19 G scalp needle. The preprostatic plexus shows immediately with the contrast medium. Rapid filling of the internal pudendal and then to internal iliac veins. Implies the drainage veins of the cavernosal sinusoids is tremendously speedy. (B) An oblique view of the pharmacocavernosogram documents the veno-occlusive dysfunction despite a rigid erection ensues. The prostaglandin E1 is intracavernously injected via the same needle. (C) In this 30-year-old male, similar to the panel A, the preprostatic plexus demonstrates immediately after a 10-ml diluted iohexol solution is injected. Thus the extraordinary complex veins are commensurate with drainage speed. (D) A veno-occlusive dysfunction was documented because venous channel exited despite rigid erection.

Vascular Surgery

May 24-25, 2018
London, UK

Recent Publications

1. Hsu G L, Chen H S, Hsieh C H, Lee W Y, Chen K L and Chang C H (2010) Clinical experience of a refined penile venous surgery procedure for patients with erectile dysfunction: is it a viable option? *Journal of Andrology* 31:271-280.
2. Hsieh C H, Liu S P, Hsu G L, Chen H S, Molodysky E, Chen Y H and Yu H J (2012) Advances in our understanding of mammalian penile evolution, human penile anatomy and human erection physiology: Clinical implications for physicians and surgeons. *Medical Science Monitor* 18(7):RA118-125.
3. Hsu G L, Hung Y P, Tsai M H, Hsieh C H, Chen H S, Molodysky E, Huynh C C, and Yu H J (2012) Penile veins are the principal component in erectile rigidity: a study of penile venous stripping on defrosted human cadavers. *Journal of Andrology* 33:1176-1185.
4. Molodysky E, Liu S P and Hsu G L (2013) Penile vascular surgery for treatment of erectile dysfunction: current role and future direction. *Arab Journal Urology* 11:254-266.
5. Hsu G L, Huang Y P, Tsai M H, Chang H C, Liu S P, Molodysky E and Hsu M C Y (2013) The venous drainage of the corpora cavernosa in the human penis. *Arab Journal Urology* 11:384-391.

Biography

Since 1986, Geng-Long Hsu, formerly a clinical professor at China Medical University, has developed and refined a series of penile reconstructive surgeries, including penile venous surgery, corporoplasty and penile implantation, in tandem with advanced penile anatomy and erection physiology. In 1993, he was promoted to the first Chair of Urology at Taiwan Adventist Hospital; he held that position until 1997 and then served as vice-superintendent of Po-Jen General Hospital until 2001. From 2001 to 2003, Dr. Hsu was a director of microsurgical potency reconstruction at Taipei Medical University Hospital. Afterward, he established his private practice—Hsu's Andrology—which serves as both a clinical practice and research center. In 2012, Dr. Hsu's latest method of penile venous stripping, administered via an ambulatory basis, was granted a USPTO patent. He hopes this surgery will be studied and practiced worldwide.

genglonghsu@gmail.com

May 24-25, 2018

London, UK

Wei Liang Chen, J Vasc Endovasc Therapy 2018, Volume 3
DOI: 10.21767/2573-4482-C1-002

SALVAGE SURGERY FOR PATIENTS WITH RECURRENT ORAL AND OROPHARYNGEAL SQUAMOUS CELL CARCINOMA INVOLVING THE CAROTID ARTERY

Wei Liang Chen

Sun Yat-sen University, China

Background: Involvement of the carotid artery (CA) is classified as a stage IVb disease, which is considered to be unresectable. Outcomes of salvage surgery and carotid artery (CA) management were evaluated in patients with oral and oropharyngeal cancer.

Patients & Methods: Thirty-six patients with advanced recurrent oral and oropharyngeal SCC involving the CA underwent salvage surgeries and reconstruction with flaps. The age range of the 28 males and eight female patients was 46–72 years. Four patients suffered carotid blowout requiring emergency surgery. They underwent wide resection of the tumor with CA resection. Reconstruction with a vascular prosthesis was performed in eight (22.2%) patients; eight (22%) others underwent subadventitial dissection of the CA; four patients (11.1%) were treated by CA subadventitial dissection and encapsulation with a vascular prosthesis; and 16 patients (44.4%) underwent CA resection alone. Reconstruction of the major defect was performed in 22 patients (61.1%) with an extended vertical lower trapezius island myocutaneous flap or folded flap; 10 (27.8%) had a pectoralis major myocutaneous flap; two (5.6%) had a submental flap; and two (5.6%) had a forearm free flap.

Results: All rCS IVb tumors were completely removed, and the tissue defects were successfully reconstructed with flaps. Postoperative transient hemiplegia occurred in two patients who underwent CA resection, but it resolved completely within 6 weeks. Four patients who underwent CA resection and reconstruction with a vascular prosthesis or CA subadventitial dissection suffered carotid blowout during the perioperative period; both were treated by ligating the CA. Two patients who underwent CA resection and reconstruction with a vascular prosthesis had a carotid embolism. None of the patients developed neurologic sequelae. After 3–46 months of follow-up, 24 patients (66.7%) had no evidence of disease, four (11.1%) showed evidence of disease, and eight (22.2%) died of local recurrence or distant metastases at 5–36 months.

Conclusions: Although these percentages are far from optimal, salvage surgery currently offers effective treatment without major complications for patients with rCS IVb oral and oropharyngeal SCC involving the CA. CA sacrifice offers a viable treatment strategy. Major defects can be reconstructed with a trapezius flap.

Recent Publications

1. Chen W L, Yang Z H, Huang Z Q, et al. (2017) Craniofacial resection and reconstruction in patients with recurrent cancer involving the craniomaxillofacial region. *Journal of Oral and Maxillofacial Surgery* 75(3):622-631.
2. Chen W L, Yang Z H, Zhou B, et al. (2016) Salvage surgery for patients with recurrent oral and oropharyngeal squamous cell carcinoma involving the carotid artery. *Journal of Oral and Maxillofacial Surgery* 74(7):1483-93.
3. Chen W L, Wang Y Y, Zhang D M, et al. (2016) Extended vertical lower trapezius island myocutaneous flap versus pectoralis major myocutaneous flap for reconstruction in recurrent oral and oropharyngeal cancer. *Head Neck*. 38(S1):E159-E164.
4. Chen W, Yang Z, Zhang D, et al. (2014) Second salvage surgery with extended vertical lower trapezius island myocutaneous flap reconstruction for advanced re-recurrent oral and oropharyngeal squamous cell carcinoma. *International Journal of Oral and Maxillofacial Surgery* 43(5):531-8

Biography

Wei Liang Chen is a Professor, Chief Surgeon and Director, Center of Cranio-Maxillofacial Surgery of Sun Yat-sen University. He focus on the diagnosis and surgical treatment of oral and cranio-maxillofacial tumors including craniofacial resection and reconstruction in patients with recurrent cancer involving the craniomaxillofacial region, salvage surgery for patients with recurrent oral and oropharyngeal cancer involving the carotid artery and comprehensive treatment of hemangiomas, vascular malformation, arte-

rioavenous malformations and lymphatic malformations. He has received 14 grants from national and provincial research funds and has holding the national medical education on comprehensive treatment of oral and cranio-maxillofacial tumors from 2001 to 2017. More than 100 papers were published in international peer-reviewed journals.

drchen@vip.163.com

May 24-25, 2018
London, UK

Aleksandra Piechota Polanczyk et al., J Vasc Endovasc Therapy 2018, Volume 3
DOI: 10.21767/2573-4482-C1-002

LACK OF TRANSCRIPTIONAL ACTIVITY OF *NRF2* AFFECTS *TGFB1* EXPRESSION AND ALTERS COLLAGEN I AND III LOCALIZATION WITHIN MICE AORTIC ANEURYSM

Aleksandra Piechota Polanczyk¹, Ewa Werner^{1,2}, Karolina Hajduk¹, Aleksandra Kopacz¹, Damian Kloska¹, Anna Grochot Przeczek¹, Ihor Huk³ and Alicja Jozkowicz¹

¹Jagiellonian University, Poland

²University of Agriculture in Krakow, Poland

³Medical University of Vienna, Austria

Statement of the Problem: Nuclear factor (erythroid-derived 2)-like 2 (NRF2) is a global antioxidant gene inducer whose activity may regulate metabolism of extracellular matrix proteins including collagen. It was shown that human abdominal aortic aneurysm has increased deposition of collagen I and reduced of collagen III in tunica media and adventitia. The synthesis of collagen I is controlled by transforming growth factor beta 1 (TGFB1). Therefore, the purpose of this study was to describe localization of structural collagens within the aorta and aortic aneurysm in transcriptional knockouts of Nrf2 and to verify the mechanism behind those changes.

Methodology & Theoretical Orientation: We used a model of angiotensin II (Ang II)-induced abdominal aortic aneurysm in old adult mice (6 mo.) with transcriptional knockout of Nrf2 (Nrf2 ^{-/-}) and with normal activity of Nrf2 (Nrf2 ^{+/+}). Mice were administrated with Ang II (1000 ng/kg/min) or saline (sham group) for 28 days via osmotic minipumps placed subcutaneously. After 28 days tissue specimens were collected for immunofluorescence and analysis of gene expression.

Findings: Ang II-treatment caused a significant increase of collagen I mRNA expression in tunica adventitia and a strong increase of collagen III expression in tunica media. The observed upregulation of collagen type I and III was significantly higher in mice lacking transcriptional Nrf2. An increase in collagens was associated with significantly higher TGFB1 only in the Nrf2 ^{-/-} mice.

Conclusion & Significance: Transcriptional factor Nrf2 may play a significant role in collagen deposition during abdominal aortic aneurysm formation and excessive collagen synthesis

may be associated with TGFB1 activation in the Nrf2^{-/-} mice.

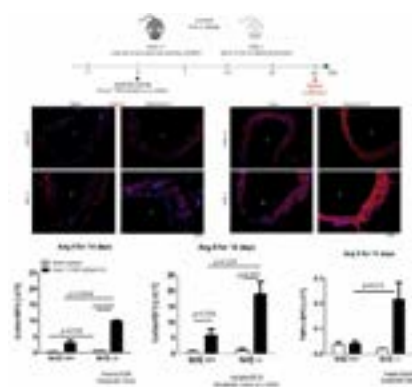


Figure 1: Altered localisation of collagen I and collagen III within the aortic aneurysm of transcriptional knockouts of Nrf2 mice. L-lumen.

Recent Publications

1. Loboda (2017) Role of Nrf2/HO-1 system in development, oxidative stress response and diseases: an evolutionarily conserved mechanism. Cellular and Molecular Life Sciences 73(17):3221-47.
2. Rodella (2016) Abdominal aortic aneurysm and histological, clinical, radiological correlation. Acta Histochemica 118(3):256-62.

May 24-25, 2018
London, UK

3. Song (2015) Molecular hydrogen stabilizes atherosclerotic plaque in low-density lipoprotein receptor-knockout mice. *Free Radical Biology and Medicine* 87:58-68.
4. Fiaschi (2014) Hyperglycemia and angiotensin II cooperate to enhance collagen I deposition by cardiac fibroblasts through a ROS-STAT3-dependent mechanism. *Biochimica et Biophysica Acta* 1843:2603-10.
5. Florczyk (2014) Nrf2 regulates angiogenesis: effect on endothelial cells, bone marrow-derived proangiogenic cells and hind limb ischemia. *Antioxidants & Redox Signaling* 20(11):1693-708

Biography

Aleksandra Piechota Polanczyk is currently employed as an Associate Professor in the Department of Medical Biotechnology, at the Jagiellonian University in the frame of the project entitled "Role of heme oxygenase 1 in the development and progression of abdominal aortic aneurysm". She received her PhD in Medicine with specialty of Medical Biology in 2011. She was a leading researcher in Prof. Ihor Huk research group (VASLAB) at the Medical University of Vienna, Austria with whom she is now cooperating. Her research interests focuses on finding of new anti-oxidative and anti-inflammatory proteins that could be potential markers and/or targets in treatment of gastrointestinal and cardiovascular diseases, as well as the role of Nrf2 and heme oxygenase 1 in cellular adaptation to oxidative stress and inflammatory reactions..

piechota.aleksandra@gmail.com

May 24-25, 2018
London, UK

Agnieszka Jabłońska, J Vasc Endovasc Therapy 2018, Volume 3
DOI: 10.21767/2573-4482-C1-002

INSIGHT INTO SINGLE NUCLEOTIDE POLYMORPHISMS OF TOLL-LIKE RECEPTORS AND THE RISK OF ABDOMINAL AORTIC ANEURYSM FORMATION

Agnieszka Jabłońska

Polish Academy of Sciences, Poland

Statement of the Problem: Toll-like receptors (TLRs) are a family of highly conserved, transmembrane proteins that recognize a wide spectrum of pathogen-associated molecular patterns (PAMPs) and activate innate immune response. It was recently shown that TLR2, TLR3, and TLR4 signaling contributes to abdominal aortic aneurysm (AAA) formation and development. However, there are no studies regarding the association between single nucleotide polymorphisms within TLR genes and the incidence of AAAs. The aim of this study was to determine the prevalence of TLR2, TLR3, and TLR4 polymorphisms, and investigate the relationship between these polymorphisms and AAA risk.

Methodology & Theoretical Orientation: The presence of the seven TLR SNPs was studied using polymerase chain reaction-restriction fragment length polymorphism (PCR-RFLP), whereas a selected cytokine levels were quantified by enzyme-linked immunosorbent assays (ELISAs).

Findings: The heterozygous genotype of the SNP rs121917864 of TLR2 was detected more frequently in patients with AAA and was associated with an almost six-fold increased risk of AAA ($P < 0.001$) and larger aneurysm size ($P = 0.037$). In contrast, a relationship between the heterozygous CA genotype of TLR3 SNP rs3775296 and diminished risk of AAA formation and development was found ($P < 0.001$).

Conclusion & Significance: The heterozygous genotype of TLR2 SNP rs121917864 may be a predictor of AAA formation, while TLR3 SNP rs3775296 seems to exert an independent protective effect. It is therefore essential to identify the host determinants of aneurysm formation in humans and understanding the role of the selected TLRs SNPs in the pathogenesis of AAA.

Recent Publications

1. Lai C H, Wang K C, Lee F T, Tsai H W, Ma C Y, Cheng T L, Chang B I, Yang Y J, Shi G Y and Wu H L (2016) Toll-like receptor 4 is essential in the development of abdominal aortic aneurysm. PLoS One 11:e0146565.
2. Vorkapic E, Lyrundberg A M, Mäyränpää M I,

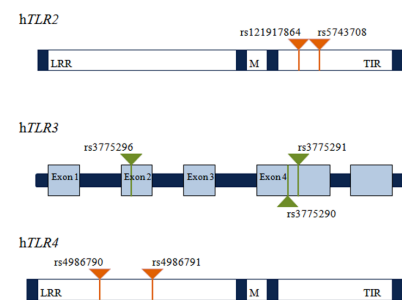


Figure 1: Schematic representation of the different SNPs in TLR genes.

Eriksson P and Wågsäter D (2015) TRIF adaptor signaling is important in abdominal aortic aneurysm formation. Atherosclerosis 241:561-568.

3. Yan H, Cui B, Zhang X, Fu X, Yan J, Wang X, Lv X, Chen Z and Hu Z (2015) Antagonism of toll-like receptor 2 attenuates the formation and progression of abdominal aortic aneurysm. Acta Pharm Sin B 5:176-187.
4. Aoyama N, Suzuki J, Ogawa M, Watanabe R, Kobayashi N, Hanatani T, Ashigaki N, Sekinishu A, Izumi Y and Isobe M (2013) Toll-like receptor-2 plays a fundamental role in periodontal bacteria-accelerated abdominal aortic aneurysms. Circ J 77:1565-1573.
5. Koch A, Pernow M, Barthuber C, Mersmann J, Zacharowski K and Grottemeyer D (2012) Systemic inflammation after aortic cross clamping is influenced by Toll-like receptor 2 preconditioning and deficiency. J Surg Res 178:833-841.

Biography

Agnieszka Jabłońska of the Institute of Medical Biology of the Polish Academy of Sciences has an experience in Molecular Virology. In her studies, she is aiming to understand the detailed molecular mechanism of viral infection and the host-pathogen interactions. Elucidation of biological significances of pattern-recognition receptors (PRRs) signaling pathways in which viruses are implicated is also one of her goals. Furthermore, she has tried to reveal the associations between the PRRs expression, single nucleotide polymorphism within TLR genes and the predisposition for abdominal aortic aneurysm development.

ajablonska@cbm.pan.pl

May 24-25, 2018
London, UK

Andrzej Polanczyk et al., J Vasc Endovasc Therapy 2018, Volume 3
DOI: 10.21767/2573-4482-C1-002

COMPUTATIONAL FLUID DYNAMIC APPROACH TO MIMIC CHANGES OF BLOOD HEMODYNAMIC IN PATIENTS WITH ACUTE TYPE IIIB AORTIC DISSECTION TREATED WITH TEVAR

Andrzej Polanczyk^{1,2}, Aleksandra Piechota Polanczyk³, Martin Funovics¹, Christoph Domenig¹, Josif Nanobashvili¹, Christoph Neumayer¹ and Ihor Huk¹

¹Medical University of Vienna, Austria

²Lodz University of Technology, Poland

³Jagiellonian University, Poland

Introduction: We aimed to verify the accuracy of computational fluid dynamics (CFD) algorithm for blood flow reconstruction for type IIIB aortic dissection (TBAD) before and after thoracic endovascular aortic repair (TEVAR).

Methods: 3D models of the aorta with adjacent arteries were prepared using pre- and post-operative CT data from five patients treated for TBAD. The displacement forces acting on the aortic wall in the areas of endograft, mass flow rate/velocity and wall shear stress (WSS) was calculated with CFD technique. Results were verified with ultrasonography (USG) data.

Results: CFD results indicated that TEVAR procedure caused 7-fold improvement in overall blood flow through the aorta ($p=0.0001$). The accuracy of CFD calculations for pre-TEVAR vs. post-TEVAR were 90% and 96%, respectively. Results from CFD also indicated a significant increase in flow rate for thoracic trunk and renal arteries, which was in accordance with USG data (accuracy 90% and 99.9%). Additionally, a significant decrease in wall shear stress (WSS) values within the whole aorta after TEVAR compared to pre-TEVAR was showed (1.34 ± 0.20 Pa vs. 3.80 ± 0.59 Pa, respectively, $p=0.0001$). This decrease was provided by a significant reduction in WSS and WSS contours in the thoracic aorta and renal arteries.

Conclusions: CFD technique confirmed that post-operative remodeling of the aorta after TEVAR for TBAD improved hemodynamic patterns reflected by flow, velocity and WSS with accuracy of 99%.

Recent Publications

1. Polanczyk A, Podyma M, Trebinski L, Chrzastek J, Zbicinski I and Stefanczyk L (2016) A novel attempt to standardize results of CFD simulations basing on

spatial configuration of aortic stent-grafts. PLoS One 11:e0153332.

2. Polanczyk A, Podyma M, Stefanczyk L, Szubert W and Zbicinski I (2015) A 3D model of thrombus formation in a stent-graft after implantation in the abdominal aorta. J Biomech. 48:425-431.
3. Duvernois V, Marsden A L and Shadden S C (2013) Lagrangian analysis of hemodynamics data from FSI simulation. Int J Numer Method Biomed Eng. 29:445-461.
4. Cheng Z, Juli C, Wood N B, Gibbs R G and Xu X Y (2014) Predicting flow in aortic dissection: comparison of computational model with PC-MRI velocity measurements. Med Eng Phys. 36:1176-1184.5.
5. Yu S C, Liu W, Wong R H, Underwood M and Wang D (2016) The potential of computational fluid dynamics simulation on serial monitoring of hemodynamic change in type B aortic dissection. Cardiovasc Intervent Radiol. 39(8):1090-1098.

Biography

Andrzej Polanczyk is a Researcher and a Team Leader at the Lodz University of Technology (Poland). He earned a PhD in Medical Engineering in 2013. He participated in scientific grants in which he build the installation to simulate the blood flow through the abdominal section of the aorta. Recently he received a grant funded by the National Centre for Research and Development. His research areas comprise biomedical, chemical and environmental engineering.

andrzej.polanczyk@gmail.com

May 24-25, 2018
London, UK

Chi Can Huynh et al., J Vasc Endovasc Therapy 2018, Volume 3
DOI: 10.21767/2573-4482-C1-002

NOVEL PILOT FILMS PROVIDING INDISPENSABLE INFORMATION IN PHARMACO-CAVERNOSOGRAPHY

Chi Can Huynh¹ and Geng Long Hsu^{2, 3}

¹The Male Clinic, Australia

²Hsu's Andrology, Taiwan

³National Taiwan University, Taiwan

Conventional pharmaco-cavernosography including CT-cavernosography provides little information on penile venous anatomy, although it is acceptable in documenting veno-occlusive erectile dysfunction (ED). We report an innovative method, which can exclusively provide penile venous anatomy for guiding penile venous stripping. From July 2010 to November 2017, 896 impotent men, aged 20 to 75 years, underwent this method of pharmaco-cavernosography in which two sets of 60mL of 50% omnipaque solution were administered intracavernously. The first set of pilot cavernosograms was taken at intervals of five, ten, twenty and thirty seconds after the commencement of the injection. The second set of cavernosograms was taken in the same intervals within 30 minutes following the pilot set, preceded by the injection of 20 µg prostaglandin E1 (PGE1). For comparison, the pilot cavernosograms were routinely performed immediately postoperative on the patient undergoing penile venous stripping. An analysis was conducted on the drainage veins including deep dorsal vein (DDV), cavernosal veins (CVs) and para-arterial veins (PAVs) accordingly. The veins demonstrated in the pilot cavernosograms, and the second set was compared in terms of venous numbers and presentation percentage. A radio-opacity of the penile crura and that of the femoral cortex was made. There was a statistically significant difference ($P < 0.001$) between the total number of independent venous drainage channels and the presentation percentage of DDV, CVs and PAVs observed in the pilot cavernosograms, and those in second set (4.5 vs. 2.1; 97.48%, 60.35%, and 38.93% vs. 57.08%, 29.37%, and 19.07%, respectively). A stronger radio-opacity of the penile crura is unexceptional noted. Compared with conventional pharmaco-cavernosography methods, pilot cavernosograms are readily able to show detailed penile venous anatomy which is indispensable for guiding venous stripping surgery. It is, therefore, may be concluded that pilot cavernosograms are an exclusively valuable addition to conventional of pharmaco-cavernosography and CT-c protocols cavernosography.

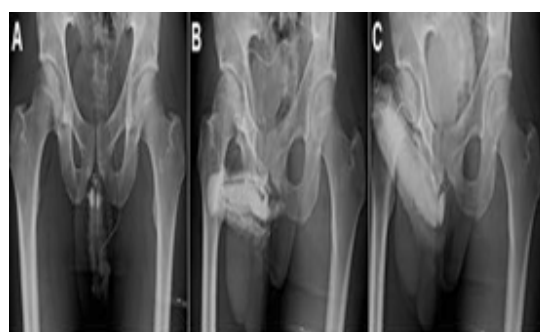


Figure 1: Dual pharmaco-cavernosography. (A) An anterior-posterior view was first used for the first set of our dual cavernosography. The complex distribution of the erection related veins was characteristic. Note at least 7 significant veins drained sinusoidal blood away from the corpora cavernosa. (B) A 30-degree right oblique position was then used to see the lateral view of the erection related veins. (C) A pharmacocavernosogram showed a veno-occlusive dysfunction (VOD) despite the rigid erection exist 15 minutes after artificially induced erection by intracavernous prostaglandin E1

Recent Publications

1. Hsu G L, Chen H S, Hsieh C H, Lee W Y, Chen K L and Chang C H (2010) Clinical experience of a refined penile venous stripping surgery procedure for patients with erectile dysfunction: is it a viable option? *Journal of Andrology* 31:271-280.
2. Hsu G L, Chen H S, Hsieh C H, Lee W Y, Chen K L and Chang C H (2010) Salvaging penile venous stripping surgery. *Journal of Andrology* 31:250-260.
3. Hsieh C H, Liu S P, Hsu G L, Chen H S, Molodsky E, Chen Y H and Yu H J (2012) Advances in our understanding of mammalian penile evolution, human penile anatomy

May 24-25, 2018
London, UK

and human erection physiology: clinical implications for physicians and surgeons. Medical Science Monitor 18:RA118-125.

4. **Hsu G L, Hung Y P, Tsai M H, Hsieh C H, Chen H S, Molodysky E, Huynh C C and Yu H J (2012) Penile veins are the principal component in erectile rigidity: a study of penile venous stripping on defrosted human cadavers. Journal of Andrology 33:1176-1185.**

Biography

Chi Can Huynh graduated from Sydney University in 1999. During his senior years in Medical School he completed a Surgical Research Term with Tom DeMeester at the University of Southern California. He was accepted into

the Advanced General Surgical training scheme in 2003 and then onto the Advanced Urology Training Program in 2005. He was the inaugural Robotic Fellow at St. Vincent's Prostate Cancer Centre in 2008. Following this, he spent 18 months in Manchester (United Kingdom) completing a laparoscopic prostate fellowship. He has interests in erectile restorative surgery and robotic prostate surgery and was the first in Australia to perform a robotic assisted radical nephro-ureterectomy and penile erection restorative vein surgery. His research interests are in erectile dysfunction and he is a part time fellow in erectile restorative surgery overseas. He co-authored papers in peer reviewed medical journals and presented multiple international conferences on the topic. He also holds teaching positions with the Rural Medical School of the Australian National University and the Australian School of Advanced Medicine.

urocch@gmail.com
genglonghsu@gmail.com

May 24-25, 2018
London, UK

Branislav Zagrapan et al., J Vasc Endovasc Therapy 2018, Volume 3
DOI: 10.21767/2573-4482-C1-002

AN IMPROVED DIAGNOSTIC SCORE FOR ABDOMINAL AORTIC ANEURYSMS BASED ON A COMPREHENSIVE ANALYSIS OF MYELOID CELL PARAMETERS

Branislav Zagrapan, Christoph Neumayer, Wolf Eilenberg, Katharina Muench, Renata Rajic, Patrick Kirchweiger, Bernd Jilma, Christoph Domenig, Ihor Huk, Georg Heinze and Christine Brostjan

Medical University of Vienna, Austria

Background: The pathogenesis of abdominal aortic aneurysm (AAA) involves a central component of chronic inflammation which is predominantly mediated by myeloid cells. Both, neutrophils and monocytes are recruited to the AAA wall and intraluminal thrombus and contribute to vessel destruction by the release of proteases and reactive oxygen species.

Purpose: We hypothesized that the local activation of myeloid cells may be reflected in systemic alterations of neutrophil and monocyte populations as well as in associated soluble factors which might serve as biomarkers to diagnose the often-asymptomatic disease.

Methods: The methods of this study were to establish their diagnostic marker potential, neutrophil and monocyte subsets were measured by flow cytometry in peripheral blood samples of 41 AAA patients and 38 healthy controls matched for age, sex, body mass index and smoking habit. Comparably, circulating factors relating to myeloid cell activation and recruitment were assayed in plasma by multicytokine array and ELISA.

Results: Significantly elevated levels of CD16+ monocytes, activated neutrophils and newly released neutrophils were recorded for AAA patients compared to controls. In line, the monocyte chemoattractant protein 1 and myeloperoxidase were significantly increased in patients' plasma. The diagnostic value was highest for myeloperoxidase, a mediator which is released by activated neutrophils as well as CD16+ monocytes. Comparison of the investigated myeloid factors with established AAA parameters by multivariable logistic regression identified myeloperoxidase and D-dimer as highly significant, independent variables. These two biomarkers were combined to yield a potent diagnostic score which was subsequently confirmed in a validation cohort.

Conclusions: Based on a comprehensive comparison of myeloid cell activation parameters, plasma myeloperoxidase

was identified as the most potent AAA biomarker. Since D-dimer and myeloperoxidase represent two sensitive markers of AAA which reflect distinct components of the AAA pathomechanism (thrombus formation and inflammation) they may be combined to yield an improved diagnostic score.

Recent Publications

1. Takagi H, Manabe H, Kawai N, et al. (2009) Plasma fibrinogen and D-dimer concentrations are associated with the presence of abdominal aortic aneurysm: a systematic review and meta-analysis. *European Journal of Vascular and Endovascular Surgery* 38:273-277.
2. Sidloff D A, Stather P W, Choke E, et al. (2014) A systematic review and meta-analysis of the association between markers of hemostasis and abdominal aortic aneurysm presence and size. *Journal of Vascular Surgery* 59:528-535.
3. Golledge J, Muller R, Clancy P, et al. (2011) Evaluation of the diagnostic and prognostic value of plasma D-dimer for abdominal aortic aneurysm. *European Heart Journal* 32:354-364.
4. Houard X, Touat Z, Ollivier V, et al. (2009) Mediators of neutrophil recruitment in human abdominal aortic aneurysms. *Cardiovascular Research* 82:532-541.
5. Dale Ma, Ruhlman M K and Baxter B T (2015) Inflammatory Cell Phenotypes in AAAs. *Arteriosclerosis, Thrombosis, and Vascular Biology* 35:1746-1755

Biography

Branislav Zagrapan is pursuing his PhD on the topic of molecular and cellular diagnostic and prognostic markers of abdominal aortic aneurysms. He is a Pathologist in training at the Academic Teaching Hospital Feldkirch, Austria

branislav.zagrapan@meduniwien.ac.at

May 24-25, 2018
London, UK

Wolf Eilenberg et al., J Vasc Endovasc Therapy 2018, Volume 3
DOI: 10.21767/2573-4482-C1-002

HISTONE CITRULLINATION OF NEUTROPHIL EXTRACELLULAR TRAPS IS A NOVEL BIOMARKER AND TARGET TO INHIBIT PROGRESSION OF ABDOMINAL AORTIC ANEURYSMS

Wolf Eilenberg, Christoph Neumayer, Branislav Zagrapan, Luca Martelanz, Marie-Therese Grasl, Alexandros Potosidis, Paimann Nawrozi, Patrick Kirchweiger, Christoph Domenig, Ihor Huk and Christine Brostjan

Medical University of Vienna, Austria

Neutrophil extracellular traps (NETs) have been implicated in the pathogenesis of abdominal aortic aneurysms (AAAs). NET formation involves histone modifications such as citrullination allowing for DNA decondensation and DNA release into extracellular space. NETs have been detected in the adventitia and intraluminal thrombus (ILT) of AAAs and the associated proteins have been proposed to promote the inflammatory reaction that drives aneurysm development. Our study has addressed the notion that NET components might serve as AAA biomarkers or novel targets of AAA therapy. Parameters of neutrophil activation as well as NET formation were determined in blood and tissue samples collected from 40 AAA patients (scheduled for surgical repair) and 40 healthy controls matched for age, sex, body mass index and smoking habit. Neutrophil and NET components were determined by ELISA in patient plasma or conditioned medium of resected tissue. NETs were visualised in aortic wall and ILT by immunofluorescence microscopy. In a model of AAA formation based on angiotensin II administration to ApoE null mice, inhibition of NET formation was tested by applying a citrullination blocker. Among the tested parameters of neutrophil activation and NET formation, citrullinated histone H3 was found to be significantly increased in blood (median 362 vs. 309 ng/ml $p=0.004$) and aortic tissue (50.9 vs. 3.7 ng/mg $p=0.001$) of AAA patients compared to healthy controls. Furthermore, NETs were highly prevalent in the intraluminal thrombus (corresponding to 642.3 ng citrullinated histone H3 per mg ILT). Plasma levels of citrullinated histone H3 decreased significantly after surgical repair. In vivo application of a citrullination inhibitor significantly reduced the capacity of mouse neutrophils to undergo NET formation. Furthermore, when aneurysm formation was initiated by angiotensin II application, disease progression was prevented in mice treated with the NET inhibitor (N=5) as compared to controls (N=5; $p=0.014$). Histone citrullination which occurs during the

formation of neutrophil extracellular traps was revealed as a biomarker of AAA formation and a potential therapeutic target to control aneurysm progression in established disease (as would be required for clinical application).

Recent Publications

1. Eilenberg W, Stojkovic S, Piechota-Polanczyk A, Kaun C, Rauscher S, Groger M, et al. Neutrophil Gelatinase-Associated Lipocalin (NGAL) is Associated with Symptomatic Carotid Atherosclerosis and Drives Pro-inflammatory State In Vitro. *Eur J Vasc Endovasc Surg.* 2016 May;51(5):623-31. PubMed PMID: 26947538. Epub 2016/03/08.
2. Eilenberg W, Stojkovic S, Kaider A, Kozakowski N, Domenig CM, Burghuber C, et al. NGAL and MMP-9/NGAL as biomarkers of plaque vulnerability and targets of statins in patients with carotid atherosclerosis. *Clin Chem Lab Med.* 2017 Jun 26. PubMed PMID: 28672747. Epub 2017/07/05. eng.
3. W. Eilenberg, S. Stojkovic, A. Piechota-Polanczyk, A. Kaider, N. Kozakowski, W. Weninger, J. Nanobachvili, J. Wojta, I. Huk, S. Demyanets, C. Neumayer Neutrophil Gelatinase Associated Lipocalin (NGAL) is elevated in type 2 diabetics with carotid artery stenosis and reduced under metformin treatment *Cardiovascular Diabetology* (2017) 8;16 (1):98

Biography

Wolf Eilenberg is a surgeon at the Department of Surgery at the Medical University Vienna. His research focus and expertise involves the role of neutrophils in carotid atherosclerotic disease and biomarkers of vulnerable carotid plaque. During the last few years, his primary interest was NGAL

Vascular Surgery

(Neutrophil gelatinase associated lipocalin), where he was able to show, that NGAL may identify the vulnerable plaque by a simple ELISA test in peripheral blood. For this work he was awarded the Finlandia prize 2016. Recently his field of interest widened towards the role of neutrophils in abdominal aortic aneurysm. Neutrophils, which were citrullinated may expulse their inside

DNA, forming neutrophil extracellular traps (=NETs), which are associated with significant inflammatory processes in the abdominal aortic wall and intraluminal thrombus. He extended his experience by murine AAA models investigating possible treatment options in AAA by applying NET-inhibitors

wolf.eilenberg@meduniwien.ac.at

May 24-25, 2018
London, UK

Ihor Huk et al., J Vasc Endovasc Therapy 2018, Volume 3
DOI: 10.21767/2573-4482-C1-002

BOVINE PERICARDIAL GRAFTS FOR THE MANAGEMENT OF AORTIC GRAFT INFECTIONS: SINGLE CENTER EXPERIENCE

Ihor Huk, Christoph M Domenig, Markus Klinger, Christopher Burghuber, Wolf Eilenberg, Christoph Neumayer and Josif Nanobachvili

Medical University of Vienna, Austria

Aim: We aimed to evaluate short and mid-term results of commercially available prefabricated vascular grafts made of bovine pericardium. Herein, we report on our institutional experience with the use of these grafts.

Methods: Six patients underwent Aorto- Iliac repair with commercially available grafts made of bovine pericardium (BPG), in an additional patient a BPG was utilized for the management of an infected PTFE fem-pop bypass graft, for the management of graft infection or in the presence of systemic infection. Comorbidities, procedure related details, postoperative mortality and mid-term follow up were assessed and analyzed. The seven patients treated with BPGs form the base of this study.

Results: 71% (5) were male, mean age was 61.4±10.9 years. Comorbidities: arterial hypertension 100% (7), smoking 71% (5), coronary artery disease 43% (3), peripheral arterial disease 86% (6) and chronic renal disease 29% (2). Indications for surgery were: i) graft infection 71% (5), ii) arterial reconstruction in the presence of systemic infection 29% (2). Five patients (71%) had a history of previous vascular surgery. In 86%, polymicrobial cultures were available (6), amongst the isolated pathogens were Staph aureus, Pseudomonas aeruginosa and E. coli. For direct repair a bifurcated graft configuration was used in all aortic cases. Median follow-up: 107 days (max: seven months). Thirty-day mortality was 14% (1) – congestive heart failure – a patient operated successfully for an infected graft, undergoing surgery for control of infection prior to intended cardiac surgery, overall mortality was 14%.

Conclusion: Our data support the conclusion that the use of BPGs represents an excellent conduit for the management of: i) aortic graft infections, ii) aortic reconstruction in the presence of systemic infection, and iii) infected prosthetic grafts utilized in peripheral arterial reconstructive surgery.

Recent Publications

1. Piechota Polanczyk A, Demyanets S, Mittlboeck M, Hofmann M, Domenig C M, Neumayer C, Wojta J, Klinger M, Nanobachvili J and Huk I (2015) The influence of simvastatin on NGAL, matrix metalloproteinases and their tissue inhibitors in human intraluminal thrombus and abdominal aortic aneurysm tissue. *European Journal of Vascular and Endovascular Surgery* 49(5):549-55.
2. Fokkema M, Vrijenhoek J E, Den Ruijter H M, Groenwold R H, Schermerhorn M L, Bots M L, Pasterkamp G, Moll F L and De Borst G J; TREAT CARE study group (2015) Stenting versus endarterectomy for restenosis following prior ipsilateral carotid endarterectomy: an individual patient data meta-analysis. *Ann Surg.* 261(3):598-604.
3. Domenig C Linni K, Mader N, Kretschmer G, Magometschnigg H and Hölzenbein T J (2008) Subclavian to carotid artery transposition: medial versus lateral approach. *European Journal of Vascular and Endovascular Surgery* 35(5):551-7.
4. Kinstner C, Teufelsbauer H, Neumayer C, Domenig C, Wressnegger A, Wolf F and Funovics M (2014) Endovascular repair of thoracoabdominal aortic aneurysms with a novel multibranched stent-graft design: preliminary experience. *Journal of Vascular Surgery (Torino)* 55(4):543-50.
5. Piechota Polanczyk A, Goraca A, Demyanets S, Mittlboeck M, Domenig C, Neumayer C, Wojta J, Nanobachvili J, Huk I and Klinger M (2012) Simvastatin decreases free radicals formation in the human abdominal aortic aneurysm wall via NF-κB. *European Journal of Vascular and Endovascular Surgery* 44(2):133-7

Biography

Ihor Huk is the Chairman of Division of Vascular Surgery since 2013 and Director of Vascular Laboratory since 1994, Department of Surgery Medical

Vascular Surgery

May 24-25, 2018
London, UK

University Vienna. He completed his Post-graduate education from University of Chicago, Heidelberg. His expertise in Transplant Surgery: since 1984 - kidney, liver transplantations And Vascular Surgery: clinical, experimental research (SPACE-Study, L-arginine study), Carotid Study (Lancet 2010). His is a member of Austrian Society of Surgery, Austrian Society of Angiology, Austrian Society of Vascular Surgery, Ukrainian Academy of High Education, Ukrainian Academy of Sciences, Member of Senats - Zaporizhzhia Medical, Postgraduate Academy. He has been given Honorary titles of: Professor Honoris Causa Universities Medicinalis Leopoliensis No. 009, University of Lwiw, Ukraine und Med. Universitat in Ternopil, Ukraine. He has more than 320 Scientific publications in German, English and Ukrainian national and

international. A comprehensive list of publications of journal articles provides an overview of Prof. Huk's research activities. Concurrently, the expert in vascular surgery also gives many international lectures at the most distinguished vascular surgery and medical conferences.

ihor.huk@meduniwien.ac.at

May 24-25, 2018
London, UK

Tejas P Singh et al., J Vasc Endovasc Therapy 2018, Volume 3
DOI: 10.21767/2573-4482-C1-002

A COMPARISON OF MAJOR AMPUTATION RATES AND OUTCOMES FOR INDIGENOUS AND NON-INDIGENOUS AUSTRALIANS IN A MAJOR TERTIARY HOSPITAL

Tejas P Singh^{1,2}, Samantha Peden¹, Ammarah Tahir¹, Vikram Iyer^{1,2}, Ramesh Velu¹, Joseph V Moxon¹, Yvonne Cadet James³ and Jonathan Golledge^{1,2}

¹Queensland Research Centre for Peripheral Vascular Disease - JCU, Australia

²Townsville Hospital, Australia

³James Cook University, Australia

Aim: Indigenous Australians are at high risk of developing diabetes-related foot complications requiring major lower limb amputations. The aim of this study was to assess the incidence and outcome for Indigenous Australians and non-Indigenous Australians undergoing major amputations (MA) at the main tertiary hospital in North Queensland, Australia over a 16-year period.

Methods: This was a retrospective study assessing all patients who underwent a MA at The Townsville Hospital between 2000 and 2015. Clinical characteristics were compared using Pearson's χ^2 test and Mann Whitney U test. MA rates (per 100,000) were calculated using the census data as the standard population. Kaplan Meier survival analysis and Cox proportional hazard analysis compared the incidence of all-cause mortality among both groups.

Results: A total of 374 MA occurred between 2000 and 2015. Seventy MA occurred in Indigenous Australians and 304 occurred in non-Indigenous Australians. Indigenous patients were younger ($p < 0.005$), more likely to be females ($p = 0.002$), have diabetes ($p < 0.005$), end-stage renal failure ($p = 0.003$), and were more likely to die during follow-up ($p = 0.028$). Overall rates of MA in Indigenous and non-Indigenous patients with diabetes were 291.9 and 70.1 per 100,000 respectively. MA rates increased in Indigenous (~15%) and non-Indigenous patients (~50%) with diabetes between 2000-2007 and 2008-2015 ($p = 0.505$). Indigenous patients were at a ~2-fold greater risk of all-cause mortality ($p = 0.027$) compared to non-Indigenous patients. This association was lost in the multivariate analysis (HR 1.24 [0.82-1.89], $p = 0.314$).

Conclusion: The burden of MA has increased in North Queensland and is greater in Indigenous Australians.

Recent Publications

1. Singh T P, Morris D R, Smith S, Moxon J V and Golledge J (2017) Systematic review and meta-analysis of the association between C-reactive protein and major cardiovascular events in patients with peripheral artery disease. *European Journal of Vascular and Endovascular Surgery* 54(2):220-33.
2. Morris D, Singh T, Moxon J, Smith A, Stewart F, Jones R, et al. (2017) Assessment and validation of a novel angiographic scoring system for peripheral artery disease. *British Journal of Surgery* 104(5):544-54.
3. Singh T P, Vangaveti V N, Kennedy R L and Malabu U H (2016) Role of telehealth in diabetic foot ulcer management - a systematic review. *Australian Journal of Rural Health* 24(4):224.
4. Nair J J and Singh T P (2017) Sjogren's syndrome: Review of the aetiology, pathophysiology & potential therapeutic interventions. *Journal of Clinical and Experimental Dentistry* 9(4):e584-e589.
5. Singh T P, Vangaveti V N and Malabu U H (2015) Dipeptidyl peptidase-4 inhibitors and their potential role in the management of atherosclerosis - a review. *Diabetes & Metabolic Syndrome: Clinical Research & Reviews* 9(4):223-9

Biography

Tejas P Singh is a Resident Medical Officer at the Vascular Surgery Department of the Townsville Hospital and a Junior Research Fellow at the Queensland Centre for Peripheral Vascular Disease

tejas.singh@my.jcu.edu.au

May 24-25, 2018
London, UK

Haibo Lu et al., J Vasc Endovasc Therapy 2018, Volume 3
DOI: 10.21767/2573-4482-C1-002

LOCKED TEMPORARY VASCULAR SHUNT

Haibo Lu¹ and Shibi Lu²

¹Hospital to the People's Liberation Army Hong Kong Garrison, China

²People's Liberation Army General Hospital, China

Statement of the Problem: To reduce the ischemia time of injured limbs in wartime, temporary vascular shunts (TVS) are commonly used. However, TVS are stabilized at the ends of the injured vessels using manual suture ties, the risk of dislodgement is high, and tightening manual suture ties is too time consuming.

Methodology & Theoretical Orientation: Locked temporary vascular shunts (LTVS) were designed, and each was composed of a silicone tube with a threaded outer surface and smooth inner surface in addition to two nylon buckle switches. The buckle switches were used to stabilize the silicone tube of the LTVS with respect to the vessel walls. This job was performed with two manual suture ties with the current TVS.

Findings: The mean bursting pressure value of the veins shunted with the LTVS was 114.3% higher than that of the veins shunted with the TVS (0.045 ± 0.008 MPa vs. 0.021 ± 0.012 MPa; $p = .00$). Although the mean shunting time of the LTVS was reduced by 60.4% compared with that of the TVS (138.89 ± 18.22 seconds vs. 350.48 ± 52.20 seconds; $p = .00$), there was no significant difference in the patency times between the two types of devices (8.20 ± 9.01 hour vs. 8.40 ± 8.85 hour; $p = .98$).

Conclusion & Significance: The LTVS, which was designed to treat wartime vascular injuries, might be safer and more efficient than the current TVS.

Recent Publications

1. Guoxian Pei and Haibo Lu (2010) Bone Allograft Transplantation. Beijing: Scientific and Technical Literature Publishing House 2010. ISBN: 9787502356392.
2. Haibo Lu, Quanyi Guo, Shibi Lu, and Yong Xu (2010) Systematic review of extremity vascular injury in modern wars. Prospero 2011, review protocol, CRD42011001729.
3. Haibo Lu, Guoxian Pei, Peiran Zhao, Shuangwu Liang, Dan Jin, and Shan Jiang (2010) Cyclosporine-impregnated allograft bone sterilized with low-temperature plasma. Journal of Tissue Engineering and Regenerative Medicine 4(8):638-51.
4. Haibo Lu, Xin Wang, Wenlong Gou, Jian Zhang, and Shibi Lu (2016) Locked temporary vascular shunt for wartime vascular injuries. EJVES Short Reports 2016. 33: 9-12.
5. Haibo Lu, Haoye Meng, Shibi Lu, Ling Qin, Bin Zhao, Aiyuan Wang, Jiang Peng, Wenjing Xu, Quanyi Guo, and Jian Zhang (2017) Freeze-dried and irradiated allograft bone combined with fresh autologous coagula promotes angiogenesis in an ectopic bone allograft implantation model. Connective Tissue Research doi: 10.1080/03008207.2017.1353977

Biography

Haibo Lu has his expertise in wartime extremity vascular injury rescue, surgical treatment for senior hip fracture and bone-allograft scaffolded tissue engineering. Most of his innovations are derived from clinic problems and factual demands from combat environment. His contexture innovation of vascular shunt might be a novel attempt to vascular repairing

luhaibo304@163.com

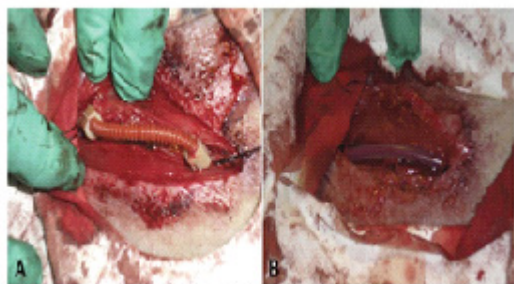


Figure 2. Injured arteries shunted using (A) a locked temporary vascular shunt (LTVS) or (B) a temporary vascular shunt.

May 24-25, 2018
London, UK

Qinchang Chen et al., J Vasc Endovasc Therapy 2018, Volume 3
DOI: 10.21767/2573-4482-C1-002

CRITICAL APPRAISAL OF INTERNATIONAL GUIDELINES FOR THE SCREENING AND TREATMENT OF ASYMPTOMATIC PERIPHERY ARTERY DISEASE: WHO DECIDES THE NON-EVIDENCE CORNER

Qinchang Chen¹ and Huang Kai²

¹Sun Yat-sen University, China

²Sun Yat-Sen Memorial Hospital, China

Statement of the Problem: More than 200 million patients have periphery artery disease (PAD) worldwide and the number of asymptomatic PAD patients were several times larger than that in the symptomatic PAD patients. Without obvious clinical symptoms, asymptomatic PAD have the similar risk of cardiovascular mortality and the mortality is much higher than the health. Though the asymptomatic PAD was observed with high morbidity and great hazard, sufficient attention has not been paid. We aimed to systematically appraise the guidelines on the screening and treatment of asymptomatic PAD and find out the agreements and the different in the recommendations.

Methodology & Theoretical Orientation: Clinical guidelines and consensus statements in English to November 2017 were searched using MEDLINE, EMBASE and some websites of guideline organizations. Three reviewers appraised the quality of the included guidelines by using AGREE II instrument. The recommendations were also fully extracted and compared.

Findings: Of 3245 citations identified, 14 guidelines were included. The AGREE score ranged from 35 to 75, mainly due to poor quality in "rigour of development" domain and "Editorial Independence" domain. For screening, 10 guidelines contained the recommendations, among which, 8 supported, one opposed and one guidelines considered insufficient evidence. For the treatment, most area was blank and the controversy was in the use of antiplatelet therapy. The guidelines with financial relationships with pharmaceutical industry or without clear statement for conflicts of interest, seemed to be more aggressive in the screening or treatment.

Conclusion & Significance: The quality of most guidelines for the management of asymptomatic PAD should be improved. More clinical studies with high quality are needed to provide the clear-cut evidence to answer the controversy and the clear statement for conflicts of interest should be provided.

Recent Publications

1. Kai H, Xixia L, Miaoyun L, et al. Intraoperative nerve monitoring reduces recurrent laryngeal nerve injury in geriatric patients undergoing thyroid surgery[J]. *Acta oto-laryngologica*, 2017, 137(12): 1275-1280.
2. Huang K, Luo D, Huang M, et al. Protection of parathyroid function using carbon nanoparticles during thyroid surgery[J]. *Otolaryngology--Head and Neck Surgery*, 2013, 149(6): 845-850.
3. Tang Y, Chen J, Huang K, et al. The incidence, risk factors and in-hospital mortality of acute kidney injury in patients after abdominal aortic aneurysm repair surgery[J]. *BMC nephrology*, 2017, 18(1): 184.
4. Luo D, Chen H, Lu P, et al. CHI3L1 overexpression is associated with metastasis and is an indicator of poor prognosis in papillary thyroid carcinoma[J]. *Cancer Biomarkers*, 2017, 18(3): 273-284.
5. Jiang Y, Wang M, Huang K, et al. Oxidized low-density lipoprotein induces secretion of interleukin-1 β by macrophages via reactive oxygen species-dependent NLRP3 inflammasome activation[J]. *Biochemical and biophysical research communications*, 2012, 425(2): 121-126

Biography

Huang Kai is the expert in the surgery of peripheral vascular surgery and thyroid surgery. Chen Qinchang, Male, born in January 1995, student of Dr Huang Kai, has been studying in Clinical Medicine Major of Zhongshan School of Medicine in Sun Yat-sen University from August 2013. Without any unexpected accident, he will be awarded the bachelor's Degree in medicine. Though he is the undergraduate at Grade 5, he has been the expert at data mining, gene chip analysis and clinical research

huangk37@mail.sysu.edu.cn

May 24-25, 2018
London, UK

Sanjay Singh et al., J Vasc Endovasc Therapy 2018, Volume 3
DOI: 10.21767/2573-4482-C1-002

DOES DUPLEX SURVEILLANCE AFTER FEMORO-POPLITEAL BYPASS GRAFTING AFFECT LONG TERM GRAFT PATENCY?

Sanjay Singh, Rushmi Purmessur and Arun Nair

Heart of England NHS Foundation Trust, UK

Introduction: Duplex scanning is currently the best method to detect stenotic lesions that threaten bypass graft patency. The correction of these lesions may improve long term patency of grafts and limb salvage rates. The aim of this study is to investigate the effects of duplex surveillance post femoro-popliteal bypass graft for chronic limb threatening ischemia (CLTI) in terms of graft patency and limb salvage.

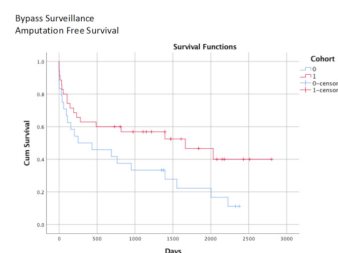
Methodology: A retrospective analysis of 59 patients who had underwent femoro-popliteal bypass graft for CLTI between Jan 2009 and April 2014. Data was collected from the electronic computer record and analyzed using SPSS v24.

Results: Of 59 patients; 49 (83.1%) had autologous vein graft, 8 (13.6%) prosthetic vein grafts and 2 (3.4%) composite graft. Mean follow up was 13.6 (0-64) months. Mean age was 77 (58-96) years. Duplex scan surveillance was performed in 35 (71.4%) patients at 3, 6, 9, 18 and 24 months post operatively; 27 in autologous vein, 7 in prosthetic graft and 1 in composite. Positive findings of occluded graft were noted in 10 duplex scans; all blocked grafts were autologous vein grafts. Out of the 17 patent vein grafts, stenosis was noted in 9 veins requiring angioplasty. Two patients needed amputation after angioplasty. Primary patency at 1 and 2 yrs. for duplex surveillance group was 71.4% and no surveillance group was 54.2%. Within two years 21 patients needed major amputation. Total amputation rate was 35.5%. Ten amputations in patient who were on surveillance were 28.5% and eleven who had no surveillance were 45.8%. At 7 years amputation free survival (AFS) was 48.6% vs. 16.7% in no surveillance group (HR 0.52 95% CI 0.28-0.99 p=0.047); Limb salvage was 71.4% vs. 54.2% (HR 0.57 95% CI 0.24-1.35 p=0.203) and overall survival was 71.4% vs. 33.3% (HR 0.37 95% CI 0.168-0.817 p=0.14).

Conclusion: In our cohort the important clinical outcomes following bypass surgery for chronic limb threatening ischemia are far better if patients were enrolled in a local graft surveillance protocol.

Recent Publications

1. Davies A H, Hawdon A J, Sydes M R and Thompson A G (2005) Is Duplex surveillance of value after leg vein bypass grafting? *Circulation* 112:1985-1991.
2. Hawdon A J, et al. (2003) Vein graft surveillance: is the yield worth the effort? *Acta Chir Belg* 103:379-382.
3. Baril D T and Marone L K (2012) Duplex evaluation following femoropopliteal angioplasty and stenting: criteria and utility of surveillance. *Vascular and Endovascular Surgery* 46:353-357.
4. Bui T D, Mills J L Sr, et al. (2012) The natural history of duplex detected stenosis after femoropopliteal endovascular therapy suggests questionable clinical utility of routine duplex surveillance. *Journal of Vascular Surgery* 55:346-352.
5. Abu Dhabri A M, Mohammed K, et al. (2017) Systemic review and meta-analysis of duplex ultrasound surveillance for infrainguinal vein bypass grafts. *Journal of Vascular Surgery* 66:1885-1891.



Biography

Sanjay Singh has his expertise and passion in Vascular and Endovascular Surgery. He has done complex aortic endovascular fellowship and is a Vascular Consultant working in United Kingdom. His open and contextual surgical techniques are based on researched and practiced models which helped to create new pathways for innovation. He has achieved this aptitude after years of experience in research and teaching in university hospitals and institutions. The ever-responsive and adapting field of Endovascular Surgery has improved the survival rates of high risk patients

dr_sanjaysingh@hotmail.com

May 24-25, 2018
London, UK

Lingyun Jia et al., J Vasc Endovasc Therapy 2018, Volume 3
DOI: 10.21767/2573-4482-C1-002

AFFECTING FACTORS OF RESIDUAL STENOSIS AFTER CAROTID ARTERY STENTING

Lingyun Jia, Yang Hua, Yunlu Tao, Liqun Jiao, Lili Wang, Beibei Liu and Weihong Hou
Xuanwu Hospital of Capital Medical University, China

Objective: To study the relevance between the incidence of residual stenosis and carotid artery stent (CAS) characteristics by color duplex flow imaging (CDFI).

Methods: Five hundred and seventy two cases (576 stents, open or closed-cell stents) who underwent CAS from January 2013 to December 2015 were retrospectively enrolled in this study. The location of carotid stenosis (common carotid artery or internal carotid artery), characteristics of plaques (regular morphology or not; with calcification or not), the length of stent, types of carotid stent (closed or open cell), rate of stent expansion (ratio of radial expansion and axial expansion) were detected one month before and one week after stenting by CDFI. Residual stenosis is defined as the stenosis rate is equal to or greater than 30% by DSA immediately after stenting.

Results: All of 576 stents, the incidence of residual stenosis was significantly higher in group of closed loop stent (28.3%, 46/163) than in group of open loop stent (20.4%, 84/413) ($\chi^2=4.15, P=0.04$). There were positive correlation between the occurrence rate of residual stenosis and closed-cell stent (odd ratios, 1.54; 95% confidence interval, 1.02-2.23) and negative correlation with the radial expansion rate (odd ratios, 0.02; 95% confidence interval, 0.01-0.06). The location of carotid stenosis and the lengths of stents were not affecting the incidence of residual stenosis. Irregularly shaped plaques (odd ratios, 9.72; 95% confidence interval, 5.65-16.76) and the plaques with calcification (odd ratios, 5.21; 95% confidence interval, 3.32-8.17) were the independent risk factors of residual stenosis after CAS.

Conclusions: This study suggests that choosing a more adaptable stent based on the types of stents and the characteristics of plaques and trying to increase the radial expansion of stenting may further decrease incidence rates of residual stenosis.

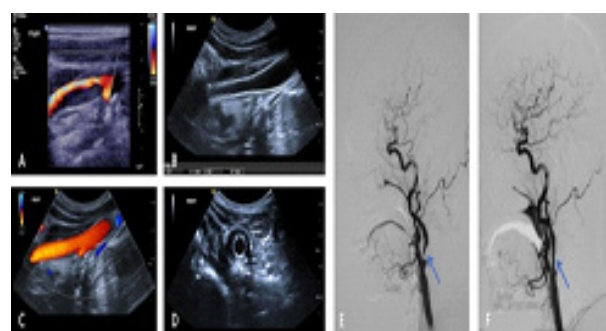


Figure 1: A: CDFI showed a severe (70-99%) stenosis at the proximal internal carotid artery; B & D: 2-D images of longitude view and cross-section view showed residual stenosis after CAS; C: CDFI showed the blood flow within the stent was smooth; E: DSA before CAS showed a severe stenosis at the proximal internal carotid artery (blue arrow); F: DSA immediately after CAS showed a residual stenosis of the stent (blue arrow).

Recent Publications

1. Csobay Novak C, Barany T, Zima E et al. (2015) Role of stent selection in the incidence of persisting hemodynamic depression after carotid artery stenting. *J Endovasc Ther* 22(1):122-129.
2. Fujii K, Carlier S G, Mintz G S, et al. (2005) Stent underexpansion and residual reference segment stenosis are related to stent thrombosis after sirolimus-eluting stent implantation: an intravascular ultrasound study. *J Am CollCardiol* 45(7):995-998.
3. Tsutsumi M, Kodama T, Aikawa H, et al. (2010) Fragmentation of calcified plaque after carotid artery stenting in heavily calcified circumferential stenosis.

May 24-25, 2018
London, UK

Neuroradiology 52(9):831-836.

4. Itami H, Tokunaga K, Okuma Y, et al. (2013) Novel 3D-CT evaluation of carotid stent volume: greater chronological expansion of stents in patients with vulnerable plaques. *Neuroradiology* 55(9):1153-1160.
5. Katano H, Mase M, Nishikawa Y, et al. (2014). Surgical treatment for carotid stenosis with highly calcified plaques. *J Stroke Cerebrovasc Dis* 23(1):148-154.

Biography

Dr. Lingyun Jia, associate professor of the Department of Vascular Ultrasonography, Xuanwu Hospital, the Capital Medical University, has excellent expertise in carotid artery ultrasound, transcranial color-coded sonography (TCCS) and transcranial Doppler (TCD). Her research focuses on the following areas: 1) Systemical evaluation of the vessel structures and hemodynamics in intracranial artery and extracranial artery by multiple-modes of ultrasound in patients with ischemic cerebrovascular diseases. 2) Evaluation of the vessel structures and hemodynamic alterations before and after carotid artery stenting and carotid endarterectomy. 3) Evaluation of internal jugular veins abnormalities by ultrasound

lingyunjia2012@163.com

May 24-25, 2018
London, UKDomanin M et al., J Vasc Endovasc Therapy 2018, Volume 3
DOI: 10.21767/2573-4482-C1-002

THE AXURGE® PROJECT. FEASIBILITY OF A MATHEMATICAL PLATFORM FOR ABDOMINAL AORTIC ANEURISM (AAA) SIZING, RISK ASSESSMENT AND SURGICAL PLANNING

Maurizio Domanin¹, **Colciago C**², **Riccobene C**³, **Deparis S**², **Quarteroni A**⁴, **Schenone E**³, **Crivaro**³ and **Prati L**⁵

¹University of Milan, Italy

²Ecole Polytechnique de Lausanne, Italy

³Moxoff, Italy

⁴Mox - Politecnico di Milano, Italy

⁵Yottacle, Italy

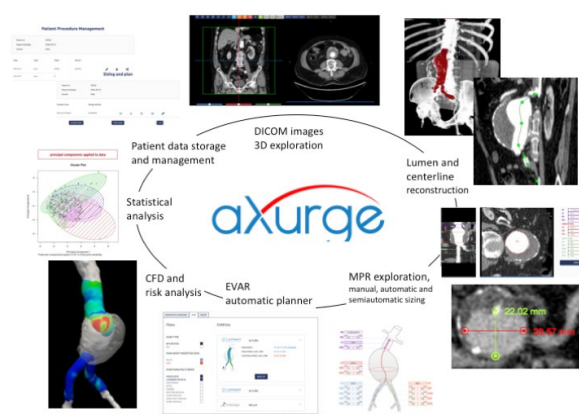
BACKGROUND: Aortic Abdominal Aneurysm (AAA) management requires to deal with different tasks: clinical evaluation, analysis and forecast risk of rupture, analysis of radiological imaging, evaluation of the feasibility for endovascular repair (EVAR), sizing and planning.

OBJECTIVE: aXurge® is the ultimate web platform for the treatment of AAA. Combining advanced mathematical techniques in the fields of imaging, numerical and statistical analysis, aXurge® provides an advanced valuable tool for:

- Vascular specialists, as it assists them during every step of the decision procedure: from the analysis of the DICOM images to an insightful and aware assessment of the patient condition, and the planning for EVAR configuration of the surgical operation.
- EVAR manufacturers, as it offers a dedicated space to interact with vascular specialists and to access a rich statistical database that will be continuously updated with new clinical cases.

MATERIAL AND METHODS: aXurge® web-platform provides the following features:

- Private case history database.
- Image processing and sizing. Our application guides clinicians to obtain from medical imaging AAA sizing and morphological characterization.
- Statistical classification and enhanced morphological and biomechanical assessment in order to produce a statistical classification of AAA.



- Patient-specific numerical simulations with haemodynamics and biomechanical models of the risk of rupture tailored on each case
- EVAR devices configuration planner through the catalogues of all the principal brands of EVAR manufacturers.

RESULTS: Over a training set of 283 geometries, after the manual selection of solely 5 seed points, our algorithms are actually able to automatically perform AAA's sizing in the 79% of the cases.

CONCLUSIONS: The great value of aXurge® relies in the synergy of several individual high-level skills, needed to achieve an effective product. aXurge® aims not only at bringing innovation to vascular experts but also at interacting and collaborating with them to ensure continuous improvement in patients' healthcare.

May 24-25, 2018
London, UK

Recent Publications

1. Piccinelli M, Vergara C, Antiga L, Forzenigo L, Biondetti P, Domanin M: Impact of hemodynamics on lumen boundary displacements in abdominal aortic aneurysms by means of dynamic computed tomography and computational fluid dynamics. *Biomechanics and Modeling in Mechanobiology*: 2013;12:1263-1276 DOI 10.1007/s10237-013-0480-5.
2. MC Firetto, M Petrini, F Sala, M Domanin, G Terribile, PR Biondetti Thoracic Aortic Aneurysms, Fistula and Thrombus. in M Scaglione (ed.) *Emergency Radiology of the Chest and Cardiovascular System*. Medical Radiology pp 307-340.
3. Vergara C, Le Van D, Quadrio M, Formaggia L, Domanin M. Large eddy simulations of blood dynamics in abdominal aortic aneurysms. *Med Eng Phys*.

Biography

Degree in Medicine and Surgery, University of Milan and Specialist in Vascular Surgery. Assistant Professor in Vascular Surgery at the University of Milan since 1994. Field of interest: He is experienced in the diagnosis and treatment of all the aspects of vascular pathologies (in particular for carotid surgery, endovascular treatment of abdominal aortic aneurysm and varicose veins surgery). Author of numerous publication, he collaborates with Politecnico of Milan and Ecole Polytechnique Federale de Lausanne for the development of bioengineering methods of analysis of Computational Fluid Dynamics (CFD) in vascular pathologies. He is the co-founder and designer of aXurge, a start-up dedicated to AAA endovascular treatment (www.aXurge.com). For these researches, he received grants from MIUR in 2005 and ERC in 2015.

maurizio.domanin@unimi.it

May 24-25, 2018
London, UK

Shannon Hernon et al., J Vasc Endovasc Therapy 2018, Volume 3
DOI: 10.21767/2573-4482-C1-002

STRUCTURED RESISTANCE EXERCISE AND REMOTE ISCHEMIC PRECONDITIONING FOR MODERATE INTERMITTENT CLAUDICATION

Shannon Hernon, Yvonne Finn and Micheál Newell

National University of Ireland Galway, Ireland

Statement of the Problem: Walking is the recommended mode of exercise for moderate intermittent claudication (IC). There is currently limited information on the effect of remote ischemic preconditioning (RIPC) and structured resistance exercise (SE), specifically full-body exercise using resistance bands, for improving walking ability. The purpose of this study is to determine if an at home structured resistance exercise programme would elicit similar improvements in walking ability, body strength endurance and quality of life (QOL) in individuals with moderate IC compared to a combination intervention of RIPC and at home structured resistance exercise.

Methodology & Theoretical Orientation: As a pilot study participant were recruited from the vascular clinic over a 52-weeks and randomly allocated to one of two interventions: a 12-week RIPC and at home SE programme (RIPC+SE) or a 12-week at home SE programme alone. Walking abilities and body strength endurance were assessed at baseline, 6-weeks and 12-weeks. QOL was assessed using EQ-5D-3L questionnaire. Findings: Thirty-one participants were recruited, 25 males and 6 females, whereby 15 were randomized to the 12-week RIPC+SE and 16 to the 12-week at home SE programme. Seven participants completed 6-weeks and 3 completed 12-weeks of the at home SE programme. Eight participants completed 6 weeks and 3 completed 12-weeks of the RIPC+SE programme. The median pain-free walking distance (PFWD) at baseline was 139.92m in the RIPC+SE group and 137.515m in the SE group. At 12 weeks the median PFWD was 316.625m and 294.5m in the RIPC+SE and the SE groups respectively. QOL scores were similar in both groups. **Conclusion & Significance:** Both interventions achieved significant improvements in PFWD. An at home SE programme, facilitates patient autonomy on timing and place of treatment, may be an effective intervention for patients with moderate IC. Further studies are required to determine the efficacy of this intervention.

Recent Publications

1. Delagarde, H., Ouadraougo, N., Grall, S., Macchi, L., Roy, P., Abraham, P., & Prunier, F. (2015). Remote ischaemic preconditioning in intermittent claudication. *Archives Of Cardiovascular Diseases*, 108(10), 472-479.

2. Fokkenrood, H., Lauret, G., Verhofstad, N., Bendermacher, B., Scheltinga, M., & Teijink, J. (2015). The Effect of Supervised Exercise Therapy on Physical Activity and Ambulatory Activities in Patients with Intermittent Claudication. *European Journal Of Vascular And Endovascular Surgery*, 49(2), 184-191.
3. Gerhard-Herman, M., Gornik, H., Barrett, C., Barshes, N., Corriere, M., & Drachman, D. et al. (2016). 2016 AHA/ACC Guideline on the Management of Patients With Lower Extremity Peripheral Artery Disease: Executive Summary: A Report of the American College of Cardiology/American Heart Association Task Force on Clinical Practice Guidelines. *Circulation*, 135(12), e686-e725.
4. Hageman, D., Gommans, L., Scheltinga, M., & Teijink, J. (2016). Effect of diabetes mellitus on walking distance parameters after supervised exercise therapy for intermittent claudication: A systematic review. *Vascular Medicine*, 22(1), 21-27.
5. Sigvant, B., Lundin, F., & Wahlberg, E. (2016). The Risk of Disease Progression in Peripheral Arterial Disease is Higher than Expected: A Meta-Analysis of Mortality and Disease Progression in Peripheral Arterial Disease. *European Journal Of Vascular And Endovascular Surgery*, 51(3), 395-403.

Biography

Shannon Hernon is currently an exercise specialist and PhD researcher at the National University of Ireland Galway. Her expertise roots from an education in exercise and sport science and has expanded to personal training and exercise intervention for special populations. Shannon's at home full body resistance exercises programmes has allowed a new approach to management of intermittent claudication. She is currently working on a project comparing at home resistance exercise to supervised walking to determine if both programmes will elicit similar psychological and physiological benefits for moderate intermittent claudication

dr_sanjaysingh@hotmail.com

May 24-25, 2018
London, UK

Oscar Ojeda, J Vasc Endovasc Therapy 2018, Volume 3
DOI: 10.21767/2573-4482-C1-002

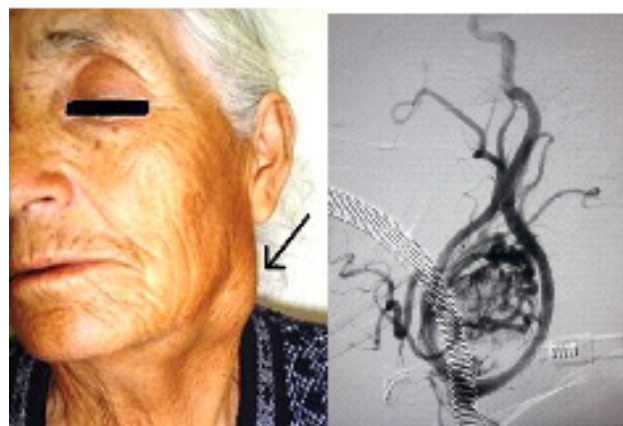NEW DEVELOPMENTS IN THE TREATMENT OF CAROTID BODY TUMORS FROM ECUADOR WHERE THEY ARE COMMON. WHAT IS THE ETIOLOGY AND THE BEST TREATMENT TRICKS

Oscar Ojeda

Hospital Eugenio Espejo, Ecuador

INTRODUCTION: The carotid body tumors belong to the paragangliomas group whose cellular origin is the neuroendocrin extra-adrenal system. The chronic hypoxia is one of the causes. Their diagnosis is based on the clinical presentation and in an image study like ultrasonography, angioCT, angio MR and angiography, this last one at the moment is not of common use and it has been displaced by other techniques. We propose a new classification. **PATIENTS:** Sixty-nine patients have been analyzed with diagnostic of carotid body tumor, all with unilateral in a 10-year-old period (2007-2017). Twelve men and 57 women. Mean age: 62 years (30-75). Forty of the left side and twenty-nine of right side. The most common form of presentation was an asymptomatic cervical mass. Most of the patients come from the region bigger mountain of cities to 2000 msnm. The diagnosis for more used image was the ultrasonography and the angioCT, in seven cases was not carried out image study. Preoperative embolization with cyanoacrylate and Onyx has been used in tumors bigger than 3 cm prior to surgery. Sixty-eight cases were subjected to surgery and in a case it was not possible the resection for discoveries of malignancy. In all the operated patients the subadventitial technique was used. Thirty-five patients were classified in tumor type Shamblin I, 21 of type II and 13 of type III. Complications in 12 cases, eight of the type III and four of the type II of Shamblin and they include: tear of the carotid bifurcation, longitudinal angioplasty of the internal carotid and ligation of the external carotid. Postoperative morbidity was presented in 15 cases: disphonia, haematoma of surgical wound and asymmetry of the tongue. There was not mortality.

CONCLUSIONS: Ecuador is a country with high prevalencia and incidence of carotid body tumors and this could be justified for the numerous cities that are on the 2000 meters on the level of the sea. The surgical procedure should be carried out by a surgeon with wide experience in technical of carotid reconstruction and handling of vascular and nervous package of neck, for this way to diminish the patient's morbidity and mortality. The embolization should be used in tumors bigger than 3 cm to diminish the risk of bleeding.



Recent Publications

1. Alex Westerband, MD, Glenn C. Hunter, MD, Ismar Cintora, MD, Stanley W. Coulthard, MD, Michael L. Hinni, MD, Andrew T. Gentile, MD, Jennifer Devine, RN, and Joseph L. Mills, MD. Current trends in the detection and management of carotid body tumors, *Journal of Vascular Surgery*, 1998 28:1 84-93.
2. ALI FIRAT, CUNEYT AYTEKIN, FATİH BOYVAT, NUR ALTINORS, MURAD BAVBEK, ATILAY TAŞDELEN. Multidisciplinary Approach to Carotid Body Paraganglioma: Preoperative Percutaneous Embolization and Surgical Resection. *Turkish Neurosurgery* 13: 81-84, 2003
3. Gutierrez, Sanchez, Portillo, Lizola. Paraganglioma carotídeo, *Actualidades* 2012. Experiencia de 35 años. *Revista Mexicana de Angiología*, vol 40, numero 1. 2012.
4. Balcazar, López, Soto. Tumor del cuerpo carotídeo de altura. Revisión de 35 años, conceptos actuales y nueva

Vascular Surgery

May 24-25, 2018
London, UK

clasificación. Técnicas endovasculares volumen XIV, número 3, diciembre 2011.

5. Christos D. Liapis, M.D., Emmanouil L. Evangelidakis, M.D. Vassilios G. Papavassiliou, M.D., John D. Kakisis, M.D., Alexandros G. Gougoulakis, M.D., Aristidis K. Polyzos, M.D., Michael N. Sechas, M.D., John G. Gogas, M.D. Role of Malignancy and Preoperative Embolization in the Management of Carotid Body Tumors. World J. Surg. 24, 1526–1530, 2000.

Biography

Oscar Ojeda is an Ecuadorian vascular surgeon specialized in Argentina. He performed a fellowship in endovascular surgery at Albany Medical Center, USA, and has completed observerships in the most important hospitals in the world (Cleveland Clinic, Mayo Clinic, New York University). In 2016 he received an award from the SVS (International Scholar) and is currently part of the department of vascular surgery of the largest public hospital in Ecuador, the Eugenio Espejo Hospital

oscarle1942@gmail.com

May 24-25, 2018
London, UK

Luboš Kubíček, J Vasc Endovasc Therapy 2018, Volume 3
DOI: 10.21767/2573-4482-C1-002

POST-PTA DISSECTION REPAIR ABOVE AND BELOW THE KNEE

Luboš Kubíček

Masaryk University, Czech Republic

Objective: Angioplasty often results in dissections and remains a significant problem. Dissections are typically managed with stents, which are associated with high rates of in-stent restenosis. Two tack optimized balloon angioplasty (TOBA) studies evaluated the safety and efficacy of a novel implant for dissection repair in both above and below the knee lesions. The Tack combines low outward force with minimal metal to provide focal treatment for dissections.

Methods: TOBA was a prospective, single-arm study evaluated patients with Rutherford Category 2-4 caused by lesions of the superficial femoral and popliteal arteries. Patients were treated with standard balloon angioplasty, and post-PTA dissections were treated with Tacks. The primary endpoints were device technical success (ability of the Tack implants to resolve post-PTA dissection) and device safety (absence of new-onset major adverse events). TOBA BTK, a separate study, evaluated patients with CLI and infrapopliteal lesions. The primary safety endpoint was a composite of MALE and POD at 30 days. Device success and procedure success were also assessed.

Results: In TOBA, Tacks were used in 130 patients with post-PTA dissections (74.0% grade C). Technical success was achieved in 98.5% of patients with no major adverse events at 30 days. Twelve-month patency was 76.4%, and freedom from TLR was 89.5%. Significant improvement from baseline was observed in Rutherford clinical category and ankle-brachial index at 12 months ($p < 0.0001$). In TOBA BTK, 32 patients received dissection repair with Tacks. Freedom from MALE and POD at 30 days was 97.1%. Twelve-month patency was 78.4% and freedom from CD-TLR at 12 months was 93.5%.

Conclusions: Tack implant treatment of post-PTA dissection was safe and resulted in low rates of TLR both above and below the knee. Tack treatment represents a new, minimal metal paradigm for dissection repair that can safely improve the clinical results associated with PTA.

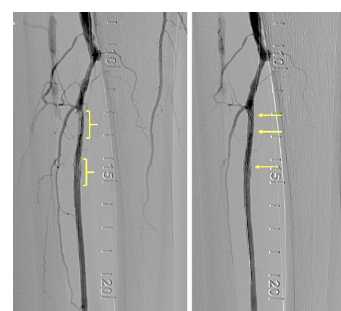

Figure 1: Example of resolved BTK Post-PTA dissection. Left: Two dissections (brackets) resulted from angioplasty. Right: Three Tack implants (arrows) were placed.

Recent Publications

1. Werk M, Albrecht T, Meyer D R, et al. Paclitaxel-coated balloons reduce restenosis after femoro-popliteal angioplasty: evidence from the randomized PACIFIER trial. *Circ Cardiovasc Interv* 2012; 5: 831-40.
2. Kiguchi MM, Marone LK, Chaer RA, et al. Patterns of femoropopliteal recurrence after routine and selective stenting endoluminal therapy. *J Vasc Surg* 2013; 57:37-43.
3. Al-Nouri O, Krezalek M, Hershberger R, et al. Failed superficial femoral artery intervention for advanced infrainguinal occlusive disease has a significant negative impact on limb salvage. *J Vasc Surg* 2012; 56:106-10.
4. Tosaka A, Soga Y, Iida O, et al. Classification and clinical impact of restenosis after femoropopliteal stenting. *J Am Coll Cardiol* 2012; 59:16-23.
5. Bosiers M, Scheinert D, Hendriks JMH et al. Results from the Tack Optimized Balloon Angioplasty (TOBA) study demonstrate the benefits of minimal metal implants for dissection repair after angioplasty. *J Vasc Surg* 2016; 64:109-16.

Biography

Luboš Kubiček received his MD degree from Faculty of Medicine, Masaryk University in Brno (Czech Republic) in 2011. He is a fifth-year postgraduate student in vascular surgery, university teacher, clinical researcher and vascular surgeon at 2nd Department of Surgery of St. Anne's university hospital in Brno, Czech Republic. His main research interests are: rupture risk prediction of abdominal aortic aneurysms, thermographic imaging in vascular surgery, systemic enzyme therapy in chronic wound healing and he is also involved in several international clinical trials, both drug research and interventional trials. He is also author or co-author of several grant project proposals and in this time, he is involved in two research grant projects.

lubos.kubicek@fnusa.cz

DAY 2

Scientific Tracks & Abstracts



3rd Edition of World Congress & Exhibition on

Vascular Surgery

May 24-25, 2018 | London, UK

DAY 2

May 25, 2018

Sessions

Endovascular Surgery | Carotid Artery Diseases |
Venous Surgery | Vascular Imaging |
Vascular Bypass Grafting

Session Chair

Ihor Huk

Medical University Vienna, Austria

Session Introduction

Title: Endovascular treatment of peripheral arterial disease in 2018: Which technology to use, and why

Martin A Funovics, Medical University of Vienna, Austria

Title: Deep venous thrombosis: From acute to chronic pharmaco-mechanic thrombectomy process

Ahmet Akgul, Istanbul University, Turkey

Title: Drop of ankle brachial index predicting outcome in treatment of popliteal artery entrapment syndrome

Hussien Rabee, Countess of Chester Hospital, UK

Title: Good results of management of varicose veins through endoscopic assisted surgery

Sin-Daw Lin, Kaohsiung Municipal Siaogang Hospital, Taiwan

Title: State-of-the-art imaging of the peripheral vasculature

Ruediger E. Schernthaner, Medical University of Vienna, Austria

Title: A physiological approach of penile venous stripping for patients with erectile dysfunction on ambulatory basis

Geng-Long Hsu, Hsu's Andrology, Taiwan

Title: Analysis of the latest method of penile venous stripping surgery in patient with veno-occlusive dysfunction

Chun-Kai Hsu, Taipei Tzu chi Hospital, Taiwan

Title: A Strategy for glans enhancement and negating glans coldness in patient with penile prosthesis implantation

Chi Can Huynh, The Male Clinic, Australia

Title: Comparison of presenting characteristics and cardiovascular outcome between indigenous and non-indigenous patients with peripheral artery disease.

Tejas P. Singh, The Townsville Hospital, Australia

Title: Different caveolin-1 and eNOS expression in simvastatin-treated patients with abdominal aortic aneurysm

Witold Nowak, Jagiellonian University, Poland

Title: Is coil embolization effectively and minimally invasive in the young man suffering from veno-occlusive dysfunction?

Chi Can Huynh, The Male Clinic, Australia

DAY 2

May 25, 2018

Sessions

Endovascular Surgery | Carotid Artery Diseases |
Venous Surgery | Vascular Imaging |
Vascular Bypass Grafting

Session Chair

Ihor Huk

Medical University Vienna, Austria

Session Introduction

Title: Marfan syndrome presented as asymmetrical aortic root aneurysm and spontaneous isolated aortic abdominal dissection

Jin-Lin Wu, Peking Union Medical College(PUMC), China

Title: Hybrid repair of aortic pathology involving aortic arch

Yu-guo Xue, Beijing Aortic Diseases Center, China

Title: Management of venous ulcers of primary varicose veins through endoscopic assisted surgery

Yun-Nan Lin, Kaohsiung Municipal Siaogang Hospital, Taiwan

Title: Optimal ultrasound criteria for grading stenosis of the superficial femoral artery

Mingjie Gao, Xuanwu Hospital of Capital Medical University, China

Title: Increased galectin-3 levels are associated with abdominal aortic aneurysm progression and inhibition of galectin-3-decrease elastase-induced AAA development

Mónica M. Torres Fonseca, FIIS-Fundacion Jimenez Diaz-Autonomia University, Spain

Title: Double aortic arch with TOF: Single stage approach via median sternotomy.

Soumya Guha, PGIMER, India

Title: Congenital absence of inferior vena cava associated with lower limb and pelvic venous thrombosis.

Sanjay Singh, United Lincolnshire Hospitals NHS Trust, UK

Title: Admission glucose and ICU mortality in abdominal aortic aneurysm patients: A retrospective analysis of the MIMIC-III clinical database

Qinchang Chen, Sun Yat-sen University, China

May 24-25, 2018
London, UK

Martin A Funovics, J Vasc Endovasc Therapy 2018, Volume 3
DOI: 10.21767/2573-4482-C1-002

ENDOVASCULAR TREATMENT OF PERIPHERAL ARTERIAL DISEASE IN 2018: WHICH TECHNOLOGY TO USE, AND WHY

Martin A Funovics

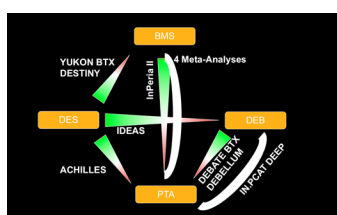
Medical University of Vienna, Austria

BACKGROUND: The endovascular treatment of peripheral arterial occlusive disease (PAOD) has undergone rapid evolution during the last years, characterized by the availability of a plethora of new devices and techniques that make an increasing number of lesions (technically) amenable to an “endo-first” approach. The interventionalist is now confronted with a multitude of options to cross and treat a lesion, but surprisingly little scientific evidence exists as to which method should be preferred over another, and in which lesion. For example, the notion that primary nitinol stents are superior to balloon angioplasty is based solely on three RCTs, the superiority of drug eluting stent over bare stent on a subgroup in one RCT, and the difference between drug-eluting balloons and nitinol stenting has never been addressed in an RCT.

LEARNING OBJECTIVES: This course will provide an overview of available endovascular techniques, including balloon angioplasty, bare stent implantation, stentgrafts, drug-eluting balloons, and drug-eluting stents. Region by region, the available literature concerning experience, expected primary patencies, and comparisons (where available) between the available methods will be appraised. Questions for which evidence is urgently needed but not available will be defined. For each region, a decision tree based upon the available evidence will be drafted and opened for discussion.

The following techniques will be covered:

- Balloon angioplasty
- Bare nitinol stents
- Drug-eluting stents
- Stentgrafts
- Drug-eluting balloons



Recent Publications

1. Self-expanding nitinol stents of high versus low chronic outward force in de novo femoropopliteal occlusive arterial lesions (BIOFLEX-COF trial): study protocol for a randomized controlled trial. Wressnegger A, Kaider A, Funovics MA. *Trials*. 2017 Dec 14;18(1):594. doi: 10.1186/s13063-017-2338-0.
2. Paclitaxel-Eluting Balloon Versus Standard Balloon Angioplasty in In-Stent Restenosis of the Superficial Femoral and Proximal Popliteal Artery: 1-Year Results of the PACUBA Trial. Kinstner CM, Lammer J, Willfort-Ehringer A, Matzek W, Gschwandtner M, Javor D, Funovics M, Schoder M, Koppensteiner R, Loewe C, Ristl R, Wolf F. *JACC Cardiovasc Interv*. 2016 Jul 11;9(13):1386-92. doi: 10.1016/j.jcin.2016.04.012.
3. Treatment of the aorto-iliac segment in complex lower extremity arterial occlusive disease. Wressnegger A, Kinstner C, Funovics M. *J Cardiovasc Surg (Torino)*. 2015 Feb;56(1):73-9. Epub 2014 Dec 5.
4. Endovascular repair of thoracoabdominal aortic aneurysms with a novel multibranched stent-graft design: preliminary experience. Kinstner C, Teufelsbauer H, Neumayer C, Domenig C, Wressnegger A, Wolf F, Funovics M. *J Cardiovasc Surg (Torino)*. 2014 Aug;55(4):543-50. Epub 2014 Jul 10.
5. [Endovascular interventions for multiple trauma]. Kinstner C, Funovics M. *Radiologe*. 2014 Sep;54(9):893-9. doi: 10.1007/s00117-013-2638-7. German

Biography

Martin Funovics is an interventional radiologist and has been working in all fields of endovascular treatment and oncologic IR for over 20 years. He has authored over 90 peer-reviewed publications both in clinical IR as well as in basic research in vascular and tumor biology. He has co-developed novel stent graft designs for aortic repair and performed several first-in-man procedures of novel devices. He is PI of the first (ongoing) RCT assessing chronic outward force between different nitinol stents in peripheral arterial disease.

martin.funovics@meduniwien.ac.at

May 24-25, 2018

London, UK

Ahmet Akgul et al., J Vasc Endovasc Therapy 2018, Volume 3
DOI: 10.21767/2573-4482-C1-002

DEEP VENOUS THROMBOSIS: FROM ACUTE TO CHRONIC PHARMACO-MECHANIC THROMBECTOMY PROCESS

Ahmet Akgul^{1,2}, Ali Ayca Kavala², Saygın Türkyılmaz² and Musa Cirak³

¹Istanbul University, Turkey

²Bakirkoy Dr. Sadi Konuk Training and Research Hospital, Turkey

Statement of the Problem: Chronic post-thrombotic syndrome (CPTS) refers to chronic clinical manifestations of venous insufficiency after deep venous thrombosis. CPTS is the most important consequence of CDVT, which develops in 20% to 50% of patients after proximal CDVT (popliteal and above CDVT) despite optimal anticoagulation therapy.

Methodology & Theoretical Orientation: We report the successful percutaneous management of extensive lower-extremity deep venous thrombosis (DVT) in 70 lower limbs (68 of them acute/subacute DVT and 2 CDVT) of consecutive 69 patients using pharmaco-mechanical thrombectomy. A 14F introducer sheath was inserted through the popliteal vein followed by rotational and aspiration thrombectomy. Balloon angioplasty was performed when needed. No stent insertion was added. Routine percutaneous pharmaco-mechanical treatment was performed in acute and/or subacute DVT and atherectomy with pharmacologic treatment were performed in CDVT.

Findings: From 2014 to 2017, single-session percutaneous endovenous pharmaco-mechanical thrombectomy was performed in 70 lower limbs of 69 patients (42 men; mean age: 41.8 years) with DVT. DVT was in subacute forms in 20 patients, and in chronic (1 patient with two limbs). Technical success rate was 97.1% (68 of 70 limbs). Among the 68 limbs, thrombectomy alone was performed in 62 (91.1%) limbs; additional balloon angioplasty of the femoral vein was performed in 6 patients. One patient with two limbs (chronic DVT) was performed thrombectomy with arterial atherectomy device with aspiration as well as balloon angioplasty.

Conclusion & Significance: Percutaneous endovenous thrombectomy is feasible and effective for patients with acute and subacute deep vein thrombosis. More patients with chronic DVT could be treated by revised-atherectomy device in the near future.

Recent Publications

1. Akgul A, Kus Gamze, Mustafaoglu Rustem and Karaborklu Argut Sezen (2018) Is video-based education an effective method in surgical education? A systematic review. *Journal of Surgical Education*, doi: 10.1016/j.jsurg.2018.01.014.
2. Akgül A, Cirak M and Birinci T (2016) Applications of platelet-rich plasma in lymphedema. *Lymphatic Research and Biology* 14(4):206-209.
3. Akgul A, Guner B, Çırak M, Çelik D, Hergünel O and Bedirhan S (2016) The beneficial effect of hypnosis in elective cardiac surgery: a preliminary study. *Journal of Thoracic and Cardiovascular Surgery* 64(7):581-588.
4. Akgul A, Gursoy M, Bakuy V, Komurcu G, Caglar I M and Gulmaliyev J (2013) Spontaneous triple coronary artery dissection. *Annals of Thoracic Surgery* 95:1443-5.
5. Akgul A, Gursoy M, Bakuy V, Polat E B, Kmurcu I G, Kavala A A, Turkyilmaz S, Caglar I M, Tekdos Y, Atay M, Altun S, Gulmaliyev C and Memmedov S (2013) Comparison of standard euroscore, logistic euroscore and euroscore II in prediction of early mortality following coronary artery bypass grafting. *Anadolu Kardioloji Derg* 13(5):425-31

Biography

Ahmet Akgul has graduated from Ankara University Medical School in 1997. He had completed his Postdoctoral residence and fellowship in the Michael E DeBakey Department of Surgery at Baylor College of Medicine in Houston, Texas. In 2004 in addition to his Chief Assistant position, he also served as an Editor in *Türkiye Klinikleri Journal of Medical Sciences*. In 2009 he was charged with establishing Heart and Vascular Surgery clinic at Istanbul Bakirkoy Dr. Sadi Konuk Hospital where he performed his works as founding clinic chief. Due to the increasing aging population in Turkey and this senior group being the majority of the heart and vascular diseases patients, he has established the Department of Gerontology in Istanbul University. In doing so he had received his Professorship and the title of Founding Department Head.

aakgul@hotmail.com

May 24-25, 2018
London, UK

Hussien Rabee et al., J Vasc Endovasc Therapy 2018, Volume 3
DOI: 10.21767/2573-4482-C1-002

DROP OF ANKLE BRACHIAL INDEX PREDICTING OUTCOME IN TREATMENT OF POPLITEAL ARTERY ENTRAPMENT SYNDROME

Hussien Rabee, R Makar, D Oloujugba and K Al Omar

Countess of Chester Hospital, UK

Statement of the Problem: Intermittent claudication is not a common presentation in young people as they are rarely suffering from chronic lower limb ischemia. Popliteal artery entrapment syndrome (PAES) is one of the main known causes of intermittent claudication and should be considered among this young age group. Most of the reported cases are males and usually present before the age of 45. Different anatomical variations found to explain the abnormal compression on the artery in the popliteal fossa. These include variant medial head of gastrocnemius muscle, muscular slip, popliteus muscle or plantaris muscle as a constricting agent. It can be bilateral up to 34% of cases. Repeated trauma may damage the popliteal artery and lead to stenosis, thrombotic occlusion or post stenotic aneurysmal dilatation. Lack of awareness could lead to delay in diagnosis and complications.

Methodology: The data of this study has been retrospectively collected with review of patients undergoing operative treatment of popliteal artery entrapment syndrome (PAES). Eight patients (11 limbs) presented, diagnosed and surgically treated. All of them were males. Six limbs had PAES on the left side. The age ranged from 21 to 47 years with median age of 31 years. Only one patient was diabetic and two were smokers. Out of the 11 limbs included in our study, three patients had bilateral PAES with unilateral symptoms. The mean duration of symptoms was 12 months and ranged between 3 and 24 months.

Conclusion & Significance: Diagnosing PAES is mainly based on clinical assessment with support of duplex scanning; ankle brachial index (ABI) drop during muscular stress is a good predictor to identify patients benefit from surgical decompression and keeping high threshold to offer surgery for PAES will save patients from inadequate outcome.

Recent Publications

1. Jarraya M, Simmons S, Farber A, Teytelboym O, Naggara N and Guermazi A (2016) Uncommon diseases of the popliteal artery: a pictorial review. *Insights into Imaging* 7(5):679-688.

| Case no. | Type | Decompression | Aneurysm | Occlusion | Bypass | Symptom relief | Follow up months |
|----------|--------|---------------|----------|-----------|--------|----------------|------------------|
| 1 | I + II | Y | - | Y | Y | Y | 30 |
| 2 | II | Y | Y | - | - | Y | 29 |
| 3 | I | Y | - | - | - | Y | 14 |
| 4 | I | Y | - | - | - | Y | 22 |
| 5 | I + II | Y | - | - | - | Y | 24 |
| 6 | IV | Y | - | Y | Y | Y | 16 |
| 7 | I | Y | - | - | - | Y | 18 |
| 8 | III | Y | - | - | - | No | 21 |
| 9 | I | Y | - | - | - | Y | 10 |
| 10 | I | Y | - | - | - | No | 6 |
| 11 | I | - | - | - | - | No | 6 |

Figure 1: Schematic representation of the different SNPs in TLR genes.

2. Lejay A, Delay C, Georg Y, Gaertner S, Ohana M, Thaveau F, Lee J T, Geny B and Chakfe N (2016) Five year outcome of surgical treatment for popliteal artery entrapment syndrome. *Eur J Vasc Endovasc Surg.* 51(4):557-64.
3. Bonasia D E, Rosso F, Cottino U and Rossi R (2015) Exercise-induced leg pain. *Asia-Pacific Journal of Sports Medicine, Arthroscopy, Rehabilitation and Technology.* 2(3):73-84.
4. Kim S Y, Min S K, Ahn S, Min S I, Ha J and Kim S J (2012) Long-term outcomes after revascularization for advanced popliteal artery entrapment syndrome with segmental arterial occlusion. *J Vasc Surg.* 55(1):90-7.
5. Sinha S, Houghton J, Holt P J, Thompson M M, Loftus I M and Hinchliffe R J (2012) Popliteal entrapment syndrome. *J Vasc Surg.* 55(1):252-262.

Biography

Hussien Rabee, MBBCh, MSc, FRCS, PHD. Consultant Vascular Surgery in Countess of Chester Hospital (2015-2018). Associate Professor & Consultant Vascular Surgery, College of Medicine, Riyadh, Saudi Arabia (1998-2014). Founder of Vascular Surgery Training Program, Head of Vascular Surgery unit & Animal Lab. Author and Co-author in different researches in Vascular Surgery.

h.rabee@nhs.net

May 24-25, 2018

London, UK

Sin Daw Lin, J Vasc Endovasc Therapy 2018, Volume 3
DOI: 10.21767/2573-4482-C1-002

GOOD RESULTS OF MANAGEMENT OF VARICOSE VEINS THROUGH ENDOSCOPIC ASSISTED SURGERY

Sin Daw Lin^{1,2}¹Kaohsiung Medical University Hospital, Taiwan²Kaohsiung Municipal Siaogang Hospital, Taiwan

Aim: The recurrence rate of management of varicose veins was high and ranged 20–60% in previous reports. In this study, primary varicose veins were managed through endoscopic assisted surgery. The recurrence rate and satisfaction rate were evaluated.

Materials & Methods: From 1997 to 2017, 1966 limbs of primary varicose veins and its complications were managed through endoscopic assisted surgery. With good illumination and magnified view offered by the endoscopy, tissues in the operative field were visualized clearly. The varicose main trunk and its tributaries, incompetent perforating veins, non-varicose veins and saphenous nerve could be identified by their anatomic appearance. The features of varicose veins explored include: 1) poor contractility of varicose veins; 2) dilated, tortuous and flaccid changes of varicose veins and 3) saccular or lateral bulging deformities of vein wall. The anatomic abnormalities were supernumerary tributaries along the main trunk, varicose clusters formed by main trunk, tributaries and/or incompetent perforating vein; variable size and location of incompetent perforating veins. The complicated abnormality of these varicose veins could be carefully dissected and radically excised. The operation procedures will be demonstrated in a video. Because all the abnormal varicose veins and incompetent perforating veins radically excised, and the recurrence rate marked is decreased.

Results: The recurrence rate ranged from 0 to 2.3% in our serial reports. The satisfaction rate of 689 patients (2004-2013) was 96.5%.

Conclusion: In management of primary varicose vein, endoscopic assisted surgery could achieve a low recurrence rate and high satisfaction rate.

Recent Publications

1. Lin Y N, Hsieh T Y, Huang S H, Liu C M, Chang K P and Lin S D (2017) Management of venous ulcers according to their anatomical relationship with varicose veins. *Phlebology* 33(1):44-52.

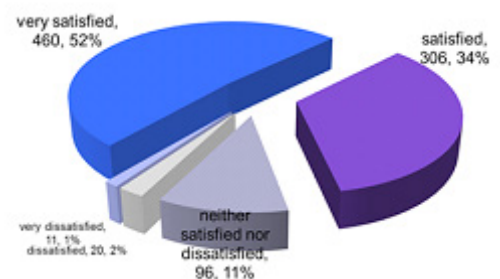


Figure 1: Satisfaction rate of 609 patients

2. Kuo C J, Liang S S, Hsi E, Chiou S H and Lin S D (2013) Quantitative proteomics analysis of varicose veins: identification of a set of differentially expressed proteins related to ATP generation and utilization. *Kaohsiung J Med Sci* 29(11):594-605.
3. Lin Y N, Lin S D, Huang S H, Lee S H, Lai C S and Chang K P (2012). Endoscopic assisted surgical management of superficial thrombophlebitis in patients with primary varicose veins. *J Taiwan Soc of Plast Surg* 21(2):90-8.
4. Chang M Y, Chiang P T, Chung Y C, Ho S Y, Lin S D, Lin S R and Neoh C A (2009) Apoptosis and angiogenesis in varicose veins using gene expression profiling. *Fooyin J Health Sci* 1(2):85-91.
5. Wang Chen H, Lin S D, Lee S S, Chang K P, Sun I F, Wang W H and Lai C S (2008) Management of primary varicose veins with the assistance of endoscopic surgery: it's role in the treatment of venous ulceration. *J Plast Surg Assoc ROC* 17(2):127-37.

Biography

Sin Daw Lin performs endoscopic face lifting for facial rejuvenation and expands the endoscopic surgery to manage the benign tumor of the head and neck. He also manages the varicose veins with the assistance of endoscopic surgery to decrease the recurrence rate. He performed immediate breast re-

Vascular Surgery

construction with pedicled transverse rectus abdominis myocutaneous flap in over 1230 cases since 1997. Recently, his research team, have established a core laboratory for the study of human adipose derived stem cells (hADSCs). They have developed a new culture medium for rapid proliferation of hADSCs and can harvest a large number of stem cells within a short period.

By tissue engineering, they have succeeded the production of new adipose tissue from hADSCs in immune-deficient mice. He expects in the near future they can reconstruct soft tissue defect with autologous adipose tissue by tissue engineering.

sidalin@kmu.edu.tw

May 24-25, 2018
London, UK

Ruediger E. Schernthaner, J Vasc Endovasc Therapy 2018, Volume 3
DOI: 10.21767/2573-4482-C1-002

STATE-OF-THE-ART IMAGING OF THE PERIPHERAL VASCULATURE

Ruediger E. Schernthaner

Medical University of Vienna, Austria

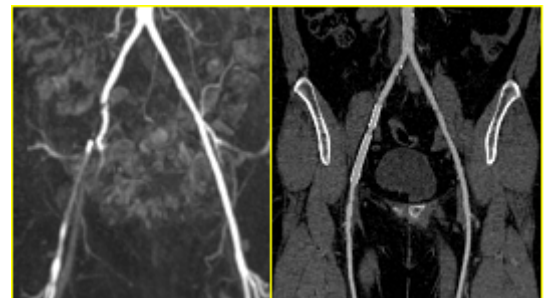
BACKGROUND: PAOD is a clinical diagnosis, the clinical Rutherford classification is based on walking impairment and the extent of ischemic ulceration. However, the complete delineation of the peripheral vascular tree is mandatory for treatment decision and planning according to the TASC guidelines (1). For long time, digital subtraction angiography was considered the gold standard due to its high temporal and spatial resolution. However, DSA is an invasive procedure requiring intra-arterial application of contrast agents, with an associated risk of complications (2) and the exposure of both patients and observers to ionizing radiation. Thus, MR angiography and CT angiography have been developed over the last 20 years in an effort to replace DSA for diagnostic purposes and to limit its application to therapeutic procedures.

LEARNING OBJECTIVES: This course will provide you with an overview of MRA and CTA of the peripheral arteries with special emphasis on their capabilities and limitations as well as most recent technical developments (3-5). The following issues will be covered:

- Volume coverage
- Spatial resolution
- Acquisition time
- Accurate and fast image post-processing
- Patient safety
- Cost efficiency

Recent Publications

1. Committee TS, Jaff MR, White CJ, Hiatt WR, Fowkes GR, Dormandy J, et al. An Update on Methods for Revascularization and Expansion of the TASC Lesion Classification to Include Below-the-Knee Arteries: A Supplement to the Inter-Society Consensus for the Management of Peripheral Arterial Disease (TASC II). J Endovasc Ther. 2015;22(5):663-77. Heilig M, Egli M (2006) Pharmacological treatment of alcohol dependence: Target symptoms and target mechanisms. Pharmacology and therapeutics 111:855-876.
2. Waugh JR, Sacharias N. Arteriographic complications in



the DSA era. Radiology. 1992;182(1):243-6.

3. Edelman RR, Flanagan O, Grodzki D, Giri S, Gupta N, Koktzoglou I. Projection MR imaging of peripheral arterial calcifications. Magnetic Resonance in Medicine. 2015;73(5):1939-45.
4. Schreiner MM, Platzgummer H, Unterhumer S, Weber M, Mistelbauer G, Groeller E, et al. Multipath Curved Planar Reformations of Peripheral CT Angiography: Diagnostic Accuracy and Time Efficiency. Cardiovascular and interventional radiology. 2017.
5. Schreiner MM, Platzgummer H, Unterhumer S, Weber M, Mistelbauer G, Loewe C, et al. A BMI-adjusted ultra-low-dose CT angiography protocol for the peripheral arteries-Image quality, diagnostic accuracy and radiation exposure. Eur J Radiol. 2017;93:149-56.

Biography

Ruediger Schernthaner is an expert in cardiovascular imaging. He has been developing CT angiography reformation techniques in collaboration with the Technical University of Vienna and the Stanford Medical Center for more than 10 years. He has published more than 50 peer-reviewed publications in the field of cardiovascular imaging and interventional oncology and authored the chapter "Management of Peripheral Arterial Disease" in the book "Managing Cardiovascular Complications in Diabetes".

ruediger.schernthaner@meduniwien.ac.at

May 24-25, 2018
London, UKGeng Long Hsu, J Vasc Endovasc Therapy 2018, Volume 3
DOI: 10.21767/2573-4482-C1-002

A PHYSIOLOGICAL APPROACH OF PENILE VENOUS STRIPPING FOR PATIENTS WITH ERECTILE DYSFUNCTION ON AMBULATORY BASIS

Geng Long Hsu^{1,2}¹Hsu's Andrology, Taiwan²National Taiwan University, Taiwan

Disclosed is the latest method of a physiologically penile venous stripping for patients with erectile dysfunction (ED) secondary to veno-occlusive dysfunction (VOD), which mainly bases on a template of Hsu's penile anatomy. It is further endorsed by Hsu's erection physiology. Neither a Bovie nor a suction apparatus is required in the entire procedure. The method entails usage of a set of specific instrument used under an acupuncture-aided pure local anesthesia on an ambulatory basis. It includes a thorough penile venous stripping and then ligating one deep dorsal vein (DDV) and a paired of cavernosal veins (CVs) whereas two pairs of para-arterial veins (PAVs) are rendered for segmental ligation closest to the tunica albuginea. The Buck's fascia is just made 5-6 opening on each emissary veins which drain the sinusoidal blood away from the corpora cavernosa. Thus the DDV trunk serves as a guide to strip the venous system along the penile shaft while the emissary vein is fixed by 6-0 nylon. A pull-through maneuver is made from opening to opening until the penile base. Likewise, the CVs are managed. A 3.5 cm long longitudinal wound is performed on the pubic region to relay the venous stripping procedure. As a rule, there are 6-9 and 5-8 branches require treated corresponding to DDV and CVs respectively from penile base to the penile hilum. A total of 67-132 ligation positions are required to complete the treatment of the offensive erection related veins. Both wounds are fashioned with layer by layer while an assistant stretch the penile shaft mimicking an erectile status. Although the techniques for handling venous tissues with stripping and then ligation is extraordinary challenging, this innovative method turns the venous treatment for ED resulting from VOD from one that has been abandoned to a curable option

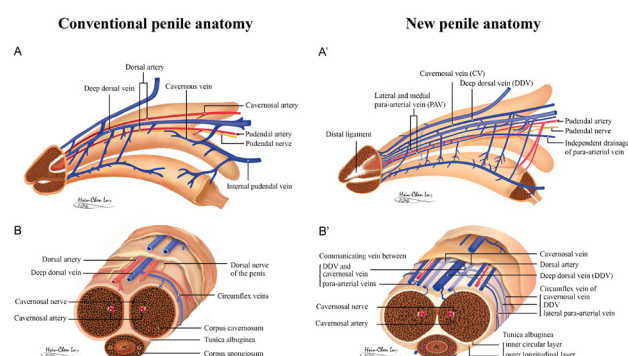


Figure 1: Schematic illustration of conventional and new penile anatomy. (A) Lateral view. The glans penis is exclusively composed of uniform sinusoids only? The deep dorsal vein (DDV) is sandwiched in by a pair of dorsal arteries (DA)? The 2:1 ratio of arteries to veins is the same as in the umbilicus vessel. (B) Cross-section of a pendulous portion in the human penis. The tunica albuginea of the corpora cavernosa is consistently described as a one-layered coat with uniform thickness. The median septum is complete. There is one single DDV and two DAs between the tunica albuginea and Buck's fascia. Thus the penile vascular system still complies with the general anatomical rule that veins number more than arteries do. In comparison, (A') Lateral view: The deep dorsal vein is consistently located in the median position and receives blood of the emissary veins from the corpora cavernosa and of the circumflex vein from the corpus spongiosum. It is sandwiched between the cavernosal veins, although these lie at a deeper position. Bilaterally, each dorsal artery is respectively sandwiched by its corresponding medial and lateral para-arterial veins. Note that the lateral para-arterial vein merges with the medial one proximally. The deeper color of the veins indicates the deepest part of the vasculature. (B') Cross section of the mid-penis. Note the number of veins is seven, not one as was traditionally believed. (Although the number becomes four at the level of the penile hilum because each pair of the nomenclature veins merges) Erection-related veins are arrayed in an imaginary arc on the dorsal aspect of the tunica albuginea.

May 24-25, 2018
London, UK

Recent Publications

1. Hsu G L, Zaid U X, Hsieh C H and Huang S J (2013) Acupuncture assisted regional anesthesia for penile surgeries. *Translation Andrology and Urology* 2:291-300.
2. Hsu G L, Huang Y P, Tsai M H, Chang H C, Liu S P, Molodysky E and Hsu M C Y (2013) The venous drainage of the corpora cavernosa in the human penis. *Arab Journal Urology* 11: 384-391.
3. Hsu G L, Molodysky E, Liu S P, Chang H C, Hsieh C H and Hsu C Y (2013) Reconstructive surgery for idealizing penile shape and erectile functional restoration on patients with penile dysmorphism and erectile dysfunction. *Arab Journal Urology* 11:375-383.
4. Hsu G L, Hill J W, Chen H S and Huang S J (2014) Novel pilot films providing dispensable information in pharmaco-cavernosography. *Translation Andrology and Urology* 4:398-405.
5. Hsieh C H, Huang Y P, Tsai M H, Chen H S, Huang P C, Lin C W and Hsu G L (2015) Tunical outer layer plays an essential role in penile veno-occlusive mechanism evidenced from electrocautery effects to the corpora cavernosa in defrosted human cadavers. *Urology* 86:1129-113.

Biography

Geng Long Hsu is a Clinical Professor at China Medical University. He has developed and refined a series of penile reconstructive surgeries, including penile venous surgery, corporoplasty and penile implantation, in tandem with advances in knowledge of the penile venous and tunical anatomy and of erection physiology. In 1993, he was promoted to the first Chair of Urology at Taiwan Adventist Hospital; he held that position until 1997 and then served as Vice-Superintendent of Po-Jen General Hospital until 2001. From 2001 to 2003, he was the Director of Microsurgery Potency Reconstruction at Taipei Medical University Hospital. Afterward, he has established his private practice—Hsu's Andrology which serves as both a clinical practice and research center. In 2012, his latest method of penile venous stripping surgery, administered via local anesthesia on an ambulatory basis, was granted a USPTO patent. He hopes this surgery will be studied and practiced worldwide.

genglonghsu@gmail.com

May 24-25, 2018
London, UKChun Kai Hsu et al., J Vasc Endovasc Therapy 2018, Volume 3
DOI: 10.21767/2573-4482-C1-002

ANALYSIS OF THE LATEST METHOD OF PENILE VENOUS STRIPPING SURGERY IN PATIENT WITH VENO-OCCLUSIVE DYSFUNCTION

Chun Kai Hsu¹ and Geng Long Hsu^{2,3}¹Taipei Tzu Chi Hospital, Taiwan²Hsu's Andrology, Taiwan³National Taiwan University, Taiwan

A penile venous stripping has been effective for treating erectile dysfunction (ED) since 1986. We conduct a retrospective analysis to those who received the latest method of surgery on an ambulatory basis. From 2009 to 2016, 452 patients had a diagnosis of veno-occlusive dysfunction (VOD). Of these, 283 men underwent the latest method of penile venous stripping. They were divided into young (n=46, younger than 30 years) and older (n=237) group respectively. The surgery begins with a circumferential incision followed by identification and management of the deep dorsal veins (DDV) 1.5~2.5 cm proximal to the retro coronal sulcus. It was then thoroughly stripped and ligated with 6-0 nylon sutures with a pull-through maneuver. The cavernosal veins (CVs) were managed in a similar manner. The para-arterial veins (PAVs) were only segmentally ligated. A median longitudinal pubic incision was then made to relay the stripping of the DDVs and CVs proximally to the infrapubic angle. Finally, the pubic and circumferential wounds were fashioned. A postoperative cavernosography was made immediately. The operative times were 4.1±0.7 and 4.0±0.6 hr. respectively. The follow-up period ranged 1.2~7.2 (5.3±1.2) years. Differences in erectile function were significant between the groups of young and older group in term of preoperative IIEF-5 (n=33, 10.2±3.6 vs. n=212, 9.7±3.8) scores compared to either one-year postoperative (n=46, 19.1±3.2 vs. n=237, 16.4±3.0) ones or two years postoperative (21.3±1.7 vs. 18.2±3.2) respectively (both p<0.003). Overall, 92.3% (261/283) of the patients reported improvements. On the preoperative and postoperative cavernosograms, it was unexceptionally enhanced from weaker to stronger radiopacity by this penile venous stripping. This latest method of penile venous stripping appears to be a viable option which achieves favorable outcomes with negligible morbidity for treating ED secondary to VOD.

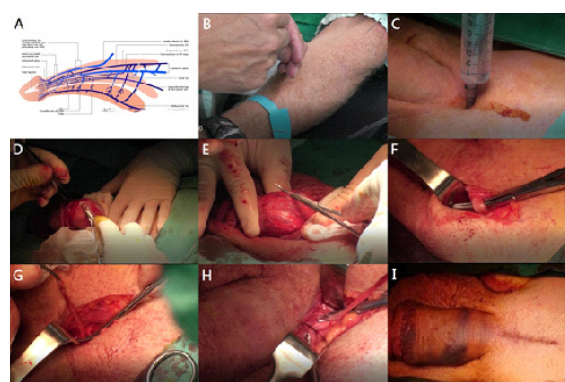


Figure 1: Schematic illustration and blueprint and ongoing penile venous stripping. (A) This is the blueprint for the latest method of penile venous stripping. It entails the new insight into erection-related veins which require being ligated at the tunical level to each emissary vein. In between the tunica albuginea and Buck's fascia, there is one deep dorsal vein (DDV), a couple of cavernosal veins (CVs) and two pairs of para-arterial veins (PAVs), in contrast to conventional one – just one single DDV. DDV is consistently in the median position and receives the blood of sinusoids of the glans penis and the emissary veins from the corpora cavernosa and of the circumflex vein from the corpus spongiosum. (B) Acupuncture is made on the acupoints of Shou San Li (LI10) Hegu (LI4) Quchi (LI11) and Waiguan (SJ5). (C) Local anesthesia is fulfilled via proximal dorsal nerve block crural block and peipenile infiltration. (D) The stripping surgery is initiated with a circumferential incision followed by degloving those tissues superficial to the Colles' fascia. The visibility of the DDV can be enhanced by squeezing the corpora cavernosa. (E) Using a pull-through maneuver, opening on Buck's fascia is made to treat the emissary vein 5-6 times until the penile base. Likewise, the CVs are managed. (F) A longitudinal pubic incision is made to relay the procedure. (G) The DDV and CVs are treated respectively. (H) As a rule there are 6-9 and 5-8 big branches to DDV and CVs respectively. (I) In our experience, a total of 76-132 ligature sites are required to finish the penile venous stripping. Both wounds are fashioned

May 24-25, 2018
London, UK

Recent Publications

1. Hsu G L, Molodysky E, Liu S P, Chang H C, Hsieh C H and Hsu C Y (2013): Reconstructive surgery for idealizing penile shape and erectile functional restoration on patients with penile dysmorphism and erectile dysfunction. *Arab Journal Urology* 11:375–383.
2. Hsu G L, Hill J W, Chen H S and Huang S J (2014) Novel pilot films providing dispensable information in pharmaco-cavernosography. *Translation Andrology and Urology* 4:398-405.
3. Hsieh C H, Huang Y P, Tsai M H, Chen H S, Huang P C, Lin C W and Hsu G L (2015) Tunical outer layer plays an essential role in penile veno-occlusive mechanism evidenced from electrocautery effects to the corpora cavernosa in defrosted human cadavers. *Urology* 86: 1129-1136.
4. Hsieh C H, Tai H C, Hsu G L, Chen C C and Hsu C Y (2016) Herb formula enhances treatment of impotent patients after penile venous stripping, a randomized clinical trial. *Andrologia* 48:754-760.
5. Hsieh C H and Hsu G L (2016) Current role of vascular surgery (Arterial and venous) in erectile dysfunction. In: *International book of erectile dysfunction*, 1st ed. edited by Djordjevic M L and Martins F E, New York: Nova Publisher, ISBN: 978-1-63485-271-5.

Biography

Since 1986, Geng-Long Hsu, formerly a clinical professor at China Medical University, has developed and refined a series of penile reconstructive surgeries, including penile venous surgery, corporoplasty and penile implantation, in tandem with advanced the penile anatomy and erection physiology. In 1993, he was promoted to the first Chair of Urology at Taiwan Adventist Hospital; he held that position until 1997 and then served as vice-superintendent of Po-Jen General Hospital until 2001. From 2001 to 2003, Dr. Hsu was a director of microsurgery potency reconstruction at Taipei Medical University Hospital. Afterward, he established his private practice—Hsu's Andrology—which serves as both a clinical practice and research center. In 2012, Dr. Hsu's latest method of penile venous stripping, administered via an ambulatory basis, was granted a USPTO patent. He hopes this surgery will be studied and practiced worldwide. I, Chun-Kai Hsu, am pleasurable to conduct this report in fellowship.

svevi0614@gmail.com

May 24-25, 2018
London, UK

Chi Can Huynh et al., J Vasc Endovasc Therapy 2018, Volume 3
DOI: 10.21767/2573-4482-C1-002

A STRATEGY FOR GLANS ENHANCEMENT AND NEGATING GLANS COLDNESS IN PATIENT WITH PENILE PROSTHESIS IMPLANTATION

Chi Can Huynh¹ and Geng Long Hsu^{2,3}

¹The Male Clinic, Australia

²Hsu's Andrology, Taiwan

³National Taiwan University, Taiwan

Although penile implantation remains a final solution for patients with refractory impotence in many urologists, undesirable postoperative effects, including the development of pale appearance, size reduction and cold sensation of the glans penis in particularly the penile size itself, remain problematic. We sought to report an innovative surgical method designed to avoid these problems. From 2003 to 2017, 103 consecutive patients received a malleable penile implant. Of these 68 men (the enhancing group, after 2008) were also treated with venous ligation of the retrocoronal venous plexus, deep dorsal vein, and cavernosal veins in addition to standard penile implant. The remaining 35 men formed the control group, treated with only a penile implant. Follow-up ranged from 0.5 to 14.5 (8.7±1.0) years. Although preoperative glanular dimension did not differ significantly between the two groups, significant respective difference at one day and one year postoperatively was found in the glanular circumference (128.6±6.8 mm versus 115.5±7.1 mm and 131.6±7.2 mm versus 100.3±7.3 mm; both <0.05), radius (38.9±2.7 mm versus 37.0±2.8 mm and 41.7±2.6 mm versus 33.7±2.9 mm; latter <0.01), and satisfaction rate (95.8% versus 53.2%, <0.01) as well. Inconclusive analysis of the penile copulatory portion ensued resulting from difficulty in practical measurement on this portion. Based on our results, selective venous ligation of penile erection related veins appears to enhance the glans penis dimension and probable the penile copulatory portion in implant patients:

Recent Publications

1. Hsu G L, Chen H S, Hsieh C H, Lee W Y, Chen K L and Chang C H (2010) Clinical experience of a refined penile venous surgery procedure for patients with erectile dysfunction: is it a viable option? *Journal of Andrology* 31(3):271-280.
2. Hsieh C H, Liu S P, Hsu G L, Chen H S, Molodysky E, Chen Y H and Yu H J (2012) Advances in our understanding

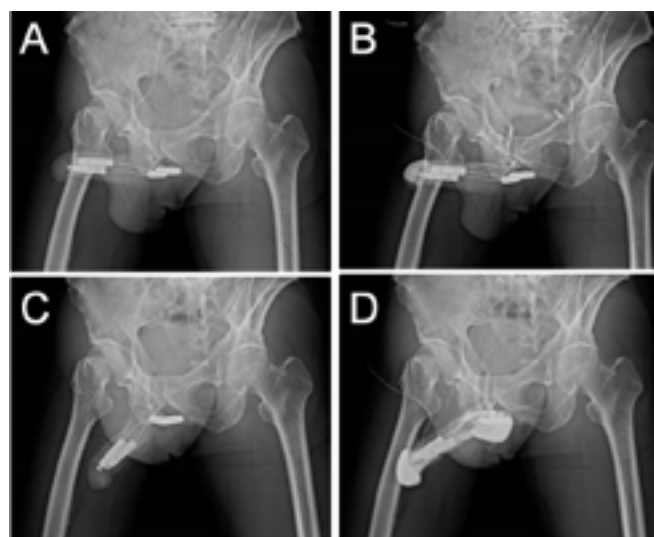


Figure 1: Pelvic x-ray film of 30 oblique view of a 65-year-old male. (A) He underwent a Duraphase penile implantation somewhere in 2005. A cold glans syndrome and reduced glans volume prompted him to receive the venous ligation surgery. (B) A spongiosogram disclosed the deep dorsal vein and the cavernosal vein via contrast injection to the glans penis. (C) The glans radius was enhanced from 28 mm to 34 mm after the penile venous surgery on the retrocoronal plexus. Meanwhile, a proximal ligation was performed on the deep dorsal vein and cavernosal vein at the penile hilum. (D) A postoperative spongiosogram disclosed the injected contrast was retention in the deep dorsal vein and the cavernosal vein. An enhancement was demonstrated in both the glans penis and entire penile shaft after a contrast medium was injected into the glans penis via a #23 scalp needle

of mammalian penile evolution, human penile anatomy and human erection physiology: clinical implications for physicians and surgeons. *Medical Science Monitor* 18(7):RA118-125.

Vascular Surgery

May 24-25, 2018
London, UK

3. Hsu G L, Chen H S and Huang S J (2013) A physiological approach to penile venous stripping surgical procedure for patients with erectile dysfunction. *Translational Medicine* 3:117.
4. Molodysky E, Liu S P and Hsu GL (2013) Penile vascular surgery for treatment of erectile dysfunction: Current role and future direction. *Arab Journal Urology* 11(3):254-266.
5. Hsu G L, Hill J W, Hsieh C H, Liu S P and Hsu C Y (2014) Venous ligation: A novel strategy for glans enhancement in penile prosthesis implantation. *BioMed Research International*, Article ID 923171.

Biography

Chi Can Huynh graduated from Sydney University in 1999. During his senior years in Medical School he completed a surgical research term with Tom De-Meester at the University of Southern California. He was accepted into the Advanced General Surgical training scheme in 2003 and then onto the Advanced Urology Training Program in 2005. He was the inaugural Robotic Fellow at St Vincent's Prostate Cancer Centre in 2008. Following this, he spent 18 months in Manchester (United Kingdom) completing a laparoscopic prostate fellowship. Dr Huynh has interests in erectile restorative surgery and robotic prostate surgery and was the first in Australia to perform a robotic assisted radical nephro-ureterectomy and penile erection restorative vein surgery. His research interests are in erectile dysfunction and is a part time fellow in erectile restorative surgery overseas. He has co-authored papers in peer reviewed medical journals and presented at multiple international conferences on the topic. He also holds teaching positions with the Rural Medical School of the Australian National University and the Australian School of Advanced Medicine.

urocch@gmail.com
genglonghsu@gmail.com

May 24-25, 2018
London, UK

Tejas P Singh et al., J Vasc Endovasc Therapy 2018, Volume 3
DOI: 10.21767/2573-4482-C1-002

COMPARISON OF PRESENTING CHARACTERISTICS AND CARDIOVASCULAR OUTCOME BETWEEN INDIGENOUS AND NON-INDIGENOUS PATIENTS WITH PERIPHERAL ARTERY DISEASE

Tejas P Singh^{1,2,3}, Joseph V Moxon¹, Genevieve N Healy³, Yvonne Cadet James⁴ and Jonathan Golledge^{1,2}

¹Queensland Research Centre for Peripheral Vascular Disease - JCU, Australia

²Townsville Hospital, Australia

³The University of Queensland, Australia

⁴James Cook University, Australia

Aim: The risk factors for peripheral artery disease (PAD) are more common in Indigenous than non-Indigenous Australians. However, the presentation and outcome of PAD in Indigenous Australians has not been previously investigated. The aim of this prospective cohort study was to compare the presenting characteristics and clinical outcome of Indigenous and non-Indigenous Australians with PAD.

Methods: PAD patients were prospectively recruited since 2003 from an outpatient vascular clinic in Townsville, Australia. Presenting symptoms and risk factors in Indigenous and non-Indigenous patients were compared using Pearson's χ^2 test and Mann Whitney U test. Kaplan Meier survival analysis and Cox proportional hazard analysis compared the incidence of myocardial infarction (MI), stroke or death (major cardiovascular events) among Indigenous and non-Indigenous patients.

Results: 401 PAD patients were recruited, of which 16 were Indigenous and 385 were non-Indigenous Australians. Indigenous Australians were younger at entry (median age 63.3 [54.7-67.8] vs. 69.6 [63.3-75.4]), more commonly current smokers (56.3% vs. 31.4%), and more frequently had insulin treated diabetes (18.8% vs. 5.2%). During a median follow-up of 2.5 years, five and 45 combined events (MI, stroke or death) were recorded amongst Indigenous and non-Indigenous Australians, respectively. Indigenous Australians were at a 4-fold greater risk of major cardiovascular events (adjusted hazard ratio 4.03 [95% confidence intervals 1.17-13.87], $p=0.027$) compared to non-Indigenous Australians.

Conclusions: These findings suggest that Indigenous Australians

with PAD present at a younger age have higher rates of smoking and insulin-treated diabetes, and poorer clinical outcomes compared to non-Indigenous Australians

Recent Publications

1. Singh T P, Morris D R, Smith S, Moxon J V and Golledge J (2017) Systematic review and meta-analysis of the association between C-reactive protein and major cardiovascular events in patients with peripheral artery disease. *European Journal of Vascular and Endovascular Surgery* 54(2):220-33.
2. Morris D, Singh T, Moxon J, Smith A, Stewart F, Jones R, et al. (2017) Assessment and validation of a novel angiographic scoring system for peripheral artery disease. *British Journal of Surgery* 104(5):544-54.
3. Singh T P, Vangaveti V N, Kennedy R L and Malabu U H (2016) Role of telehealth in diabetic foot ulcer management – A systematic review. *Australian Journal of Rural Health* 24(4):224.
4. Nair J J and Singh T P (2017) Sjogren's syndrome: review of the aetiology, pathophysiology & potential therapeutic interventions. *Journal of Clinical and Experimental Dentistry* 9(4):e584-e9.
5. Singh T P, Vangaveti V N and Malabu U H (2015) Dipeptidyl peptidase-4 inhibitors and their potential role in the management of atherosclerosis—a review. *Diabetes & Metabolic Syndrome: Clinical Research & Reviews* 9(4):223-9.

Vascular Surgery

Biography

Tejas P Singh is a Resident Medical Officer at the Vascular Surgery Department of the Townsville Hospital and a Junior Research Fellow at the Queensland Centre for Peripheral Vascular Disease.

tejas.singh@myjcu.edu.au

May 24-25, 2018
London, UK

Aleksandra Piechota Polanczyk et al., J Vasc Endovasc Therapy 2018, Volume 3
DOI: 10.21767/2573-4482-C1-002

DIFFERENT *CAVEOLIN-1* AND *ENOS* EXPRESSION IN SIMVASTATIN-TREATED PATIENTS WITH ABDOMINAL AORTIC ANEURYSM

Aleksandra Piechota Polanczyk^{1,3}, Karolina Kowalska^{1,2}, Dominika Ewa Habrowska Górczyńska², Christoph Neumayer¹, Michael Bolliger¹, Christoph Domenig¹, Markus Klinger¹, Josif Nanobaschvili¹, Agnieszka Wanda Piastowska Ciesielska² and Ihor Huk¹

¹Medical University of Vienna, Austria

²Medical University of Lodz, Poland

³Jagiellonian University, Poland

Introduction: This study was undertaken to verify if simvastatin modulates Cav-1/eNOS expression and if this modulation is associated with changes in pro- and anti-inflammatory cytokines and Toll-like receptor 4 (TLR4) in abdominal aortic aneurysm (AAA).

Methods: This was undertaken on non-statin (n=12) and simvastatin-treated patients (n=24) who underwent open AAA repair. Patients were treated with simvastatin at a dose of 20 or 40 mg/day for at least 6 months. The tissue samples of AAA wall were analyzed for Cav-1, eNOS, interleukin 6 (IL-6), IL-10, IL-17 and TLR4 at the gene and protein level.

Results: Simvastatin treatment significantly and dose-dependently decreased Cav-1 and increased eNOS expression in AAA wall ($p<0.05$ and $p<0.01$, respectively). The changes in Cav-1 and eNOS were associated with increased concentration of IL-10 ($p=0.055$) but not IL-6, IL-17 or TLR4 expression in AAA wall.

Conclusions: Simvastatin may modulate Cav-1 and eNOS expression in aneurysmal wall indicating a new beneficial role of statins in AAA patients

Recent Publications

1. Piechota Polanczyk A, Demyanets S, Nykonenko O, Huk I, Mittlboeck M, Domenig C M, Neumayer C, Wojta J, Nanobaschvili J and Klinger M (2013) Decreased tissue levels of cyclophilin A, a cyclosporine a target and phospho-ERK1/2 in simvastatin patients with abdominal aortic aneurysm. Eur J Vasc Endovasc Surg 45:682-688.
2. Huk I, Nanobaschvili J, Neumayer C, Punz A, Mueller M, Afkhampour K, Mittlboeck M, Losert U, Polterauer P, Roth E, Patton S and Malinski T (1997) L-arginine treatment alters the kinetics of nitric oxide and superoxide release

and reduces ischemia/reperfusion injury in skeletal muscle. Circulation 96:667-675.

3. Ricchiuti V, Lapointe N, Pojoga L, Yao T, Tran L, Williams G H and Adler G K (2011) Dietary sodium intake regulates angiotensin II type 1, mineralocorticoid receptor, and associated signaling proteins in heart. J Endocrinol 211:47-54.
4. Testa A, Spoto B, Sanguedolce M C, Parlongo R M, Pisano A, Tripepi G, Benedetto F A, Mallamaci F and Zoccali C (2012) eNOS and caveolin-1 gene polymorphisms interaction and intima media thickness: a proof of concept study in ESRD patients. Am J Hypertens 25:103-08.
5. Johnston W F, Salmon M, Su G, Lu G, Stone M L, Zhao Y, Owens G K, Upchurch G R Jr. and Ailawadi G (2013) Genetic and pharmacologic disruption of interleukin-1beta signaling inhibits experimental aortic aneurysm formation. Arterioscler Thromb Vasc Biol 33(2):294-304.

Biography

Aleksandra Piechota Polanczyk is currently employed as an Associate Professor at the Department of Medical Biotechnology, at the Jagiellonian University in the frame of the project entitled: Role of heme oxygenase 1 in the development and progression of abdominal aortic aneurysm. She received her PhD in Medicine with specialty of Medical Biology in 2011. She was a leading Researcher in Prof. Ihor Huk research group (VASLAB) at the Medical University of Vienna (Austria) with whom she is now cooperating. She is an author and a co-author of 37 publications published in Polish and foreign international journals (28 original papers and 8 review articles). Her research interests focuses on finding of new anti-oxidative and anti-inflammatory proteins that could be potential markers and/or targets in treatment of gastrointestinal and cardiovascular diseases, as well as the role of Nrf2 and heme oxygenase 1 in cellular adaptation to oxidative stress and inflammatory reactions

piechota.aleksandra@gmail.com

May 24-25, 2018
London, UK

Chi Can Huynh et al., J Vasc Endovasc Therapy 2018, Volume 3
DOI: 10.21767/2573-4482-C1-002

IS COIL EMBOLIZATION EFFECTIVELY AND MINIMALLY INVASIVE IN THE YOUNG MAN SUFFERING FROM VENO-OCCLUSIVE DYSFUNCTION?

Chi Can Huynh¹ and Geng Long Hsu^{2,3}

¹The Male Clinic, Australia

²Hsu's Andrology, Taiwan

³National Taiwan University, Taiwan

Is coil embolization effective and safe to treat impotence resulting from veno-occlusive dysfunction, we report five cases and literature review. From 2012 to 2017, refractory impotence prompted five young men to consult us despite coil venous embolization performed elsewhere. All patients were evaluated with general x-ray, Doppler sonography, computerized tomography, the abridged 5-item version of the international index of erectile function (IIEF-5) and our dual phamco-cavernosography. They were treated with the latest method of penile venous stripping which was carried out with circumferential and pubic longitudinal approaches under acupuncture aided local anesthesia. The deep dorsal vein, cavernosal veins were thoroughly stripped while the para-arterial veins were ligated segmentally. Follow-up cavernosography was routinely conducted for confirming sufficient venous stripping and comparison of radio-opacity between the femoral cortex and the corpora cavernosa especially the penile crura while the IIEF-5 follow was merely made via the internet. A review of the literature on coil embolization was obtained using Medline. Coils migration took place in four patients in which each two were found in pelvic and pulmonary area respectively and one patient disclosed dozens of coils in the periprostatic plexus, all had no improvement in impotence. Postoperative cavernosography discloses the radio-opacity of the penile crura was denser than that of the femoral cortex. However, the IIEF-5 score changed from 10.4 ± 2.4 to 15.9 ± 2.8 , $p < 0.001$. One man required additional oral sildenafil and two men ended with a penile implant. Coil migration was not uncommon in the medical literature, which varied from 2.5% to 11.1%. The efficacy of penile venous embolization appears controversial, and its safety may not be sustainable although larger samples may be required.

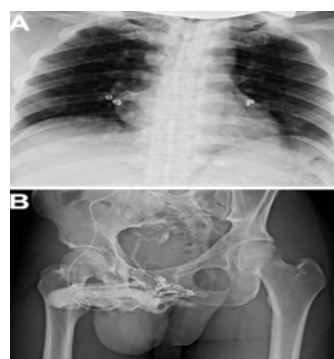

Figure 1: Imaging of patients who received prior penile venous embolization. (A) Several embolization coils are likely lodged in the pulmonary artery and further confirmed by contrast CT Scanning which disclosed one coil perforated cardiac right ventricle. In recent years, the patient was susceptible to hemoptysis. (B) A cavernosogram of another patient disclosed several dozens of coils lodged in the Santorini plexus

Recent Publications

1. Hsu G L, Chen H S, Hsieh C H, Lee W Y, Chen K L and Chang C H (2010) Clinical experience of a refined penile venous stripping surgery procedure for patients with erectile dysfunction: is it a viable option? *Journal of Andrology* 31:271-280.
2. Hsu G L, Chen H S, Hsieh C H, Lee W Y, Chen K L and Chang C H (2010) Salvaging penile venous stripping surgery. *Journal of Andrology* 31:250-260.
3. Hsieh C H, Liu S P, Hsu G L, Chen H S, Molodysky E, Chen Y H and Yu H J (2012) Advances in our understanding of mammalian penile evolution, human penile anatomy

May 24-25, 2018
London, UK

and human erection physiology: clinical implications for physicians and surgeons. *Medical Science Monitor* 18:RA118-125.

4. Hsu G L, Hung Y P, Tsai M H, Hsieh C H, Chen H S, Molodysky E, Huynh C C and Yu H J (2012) Penile veins are the principal component in erectile rigidity: a study of penile venous stripping on defrosted human cadavers. *Journal of Andrology* 33:1176-1185.

Biography

Chi Can Huynh graduated from Sydney University in 1999. During his senior years in Medical School he completed a Surgical Research Term with Tom DeMeester at the University of Southern California. He was accepted into

the Advanced General Surgical training scheme in 2003 and then onto the Advanced Urology Training Program in 2005. He was the inaugural Robotic Fellow at St. Vincent's Prostate Cancer Centre in 2008. Following this, he spent 18 months in Manchester (United Kingdom) completing a laparoscopic prostate fellowship. He has interests in erectile restorative surgery and robotic prostate surgery and was the first in Australia to perform a robotic assisted radical nephro-ureterectomy and penile erection restorative vein surgery. His research interests are in erectile dysfunction and he is a part time fellow in erectile restorative surgery overseas. He co-authored papers in peer reviewed medical journals and presented multiple international conferences on the topic. He also holds teaching positions with the Rural Medical School of the Australian National University and the Australian School of Advanced Medicine.

urocch@gmail.com
genglonghsu@gmail.com

May 24-25, 2018
London, UK

Jin Lin Wu et al., J Vasc Endovasc Therapy 2018, Volume 3
DOI: 10.21767/2573-4482-C1-002

MARFAN SYNDROME PRESENTED AS ASYMMETRICAL AORTIC ROOT ANEURYSM AND SPONTANEOUS ISOLATED AORTIC ABDOMINAL DISSECTION

Jin Lin Wu and **Cun Tao Yu**

Peking Union Medical College(PUMC), China

Introduction: Isolated abdominal aortic dissection (IAAD) refers to aortic dissection (AD) inferior to the diaphragm, which is very rare. Marfan syndrome (MFS) is an autosomal dominant connective tissue disorder, which is mostly presented as garlic-like aortic aneurysm in cardiovascular system. To the best of our knowledge, no such a case concerning MFS presented as IAAD has been reported before.

Case Report: A 37-year-old female with no history of hypertension was referred to our hospital for chest tightness. She had been initially diagnosed as spontaneous IAAD one month before with successful analgesic and antihypertensive treatment at a local hospital. On physical examination, the patient's blood pressure was 138/80 mmHg. Laboratory tests showed D-dimer of 2.13 ug/ml (<0.5 ug/ml), FDP of 8.42 ug/ml (0-5 ug/ml). Echocardiography revealed severe aortic regurgitation. CT showed an obvious compression of the left atrium by asymmetrical dilatation of non-coronary sinus. Abdominal aortic dissection originated distally to the superior mesenteric artery (SMA) ostium and extended downward to the bilateral common internal iliac artery. Then FBN1 mutation was found by gene analysis, thus the diagnosis of Marfan syndrome (MFS) was confirmed. She underwent Bentall procedure only and discharged on calcium channel blocker and warfarin. On follow-up at 1 year, the patient was doing well physically. CT scanning found no obvious extension of IAAD or aortic growth in diameter.

Lessons: First, this is the first case report of MFS combined with both asymmetrical aortic root aneurysm and spontaneous IAAD, which enriches our understanding of the clinical manifestations of MFS. Second, we should take aorta as a whole organ in which multiple levels of lesions may occur simultaneously, so it is necessary to assess the whole aorta in order to prevent serious missed diagnosis. Third, for MFS patient with IAAD, conservative treatment under careful surveillance seems satisfactory on a short-term follow up. Further follow-up is still needed to confirm the long-term effect.

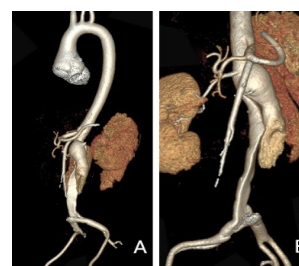


Figure 1: A: 3-D re-construction of CT scanning of the whole aorta. B: 3-D re-construction of CT scanning of the abdominal aorta.

Recent Publications

1. Cheng L, Huang F, Chang Q, Zhu J, Yu C, Liu Y, et al. (2010) Repair of extensive thoracoabdominal aortic aneurysm with a tetrafurcate graft: midterm results of 63 cases. *The Heart Surgery Forum* 13(1):E1-6.
2. Sun X, Zhang L, Yu C, Qian X and Chang Q (2014) One-stage repair of extensive aortic aneurysms: mid-term results with total or subtotal aortic replacement. *Interactive Cardiovascular & Thoracic Surgery* 18(3):278-82.
3. Zhang L, Yu C, Qian C, Luo X, Qiu J and Liu S (2016) Comparison of gene expression profiles in aortic dissection and normal human aortic tissues. *Biomedical Reports* 5(4):421-7.
4. Liu P, Qian C, Qian X, Sun X, Yu C, Tian C, et al. (2016) Early and mid-term results after hybrid total arch repair of DeBakey type I dissection without deep hypothermic circulatory arrest. *Interactive Cardiovascular & Thoracic Surgery* 23(4):608.

Biography

Cun Tao Yu is one of the most famous cardiovascular surgeons in China. He is especially good at all kinds of operation of large vessels and has completed over 1500 operations such as total arch replacement and thoracoabdominal aortic replacement. Jin Lin Wu is his doctoral candidate.

jinlinhowsy@outlook.com

May 24-25, 2018
London, UK

Yu Guo Xue et al., J Vasc Endovasc Therapy 2018, Volume 3
DOI: 10.21767/2573-4482-C1-002

HYBRID REPAIR OF AORTIC PATHOLOGY INVOLVING AORTIC ARCH

Yu Guo Xue, Li Zhong Sun, Jun Zheng, Shangdong Xu and Lian Jun Huang

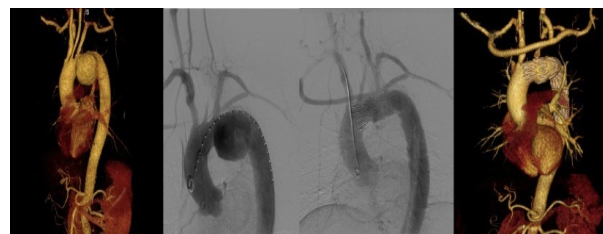
Beijing Aortic Diseases Center, China

Purpose: To evaluate the safety and efficacy of hybrid repair for aortic lesions involving aortic arch.

Materials & Methods: From February 2009 to September 2016, 81 consecutive patients (70 men; mean age 63.4±7.9 years, range 32-79) underwent brachiocephalic bypass combined with stent-graft implantation (hybrid) and were enrolled in the study. Aortic pathologies included Stanford type B aortic dissection (n=22), aortic arch aneurysm (n=26), aortic arch pseudoaneurysm (n=14), aortic arch penetrating ulcer (n=11) and proximal endoleak (n=5) or pseudoaneurysm formation (n=3) after thoracic endovascular aortic repair (TEVAR). Hybrid repair comprised 3 landing in zone 0, 44 landing in zone 1 and 34 landing in zone 2. Simultaneous procedures included left subclavian artery embolization (n=57), endovascular abdominal aortic repair (n=1), coronary artery bypass (n=1), left common carotid endarterectomy (n=1) and renal stenting (n=4). Follow-up was performed at 1 month, 3 months, 6 months, 1 year and annually thereafter to investigate endoleak, patency of vascular graft and exclusion of aortic pathology.

Results: Technical success was 100%. Instant endoleak was observed in 9 (11.1%, 7 type I, 2 type II) cases on postoperative angiography. Perioperative complications included iatrogenic ascending aortic dissection (n=1, 1.2%), stroke (n=2, 2.5%), anastomotic bleeding (n=1, 1.2%), both lower limbs thrombosis (n=1, 1.2%) and acute respiratory failure (n=2, 2.5%). Early morbidity was 8.6% (7/81). Early death occurred in 5 cases (6.2%) due to stroke, anastomotic bleeding, acute respiratory failure and sudden death. Follow-up was complete in 100% for 39.4±14.5 months (range 1-81 months). During follow-up, all the vascular grafts were patent. The overall endoleak rate was 13.58% (11/81). Late mortality was 6.2% (5/81) and morbidity was 14.5% (8/81).

Conclusions: Hybrid repair of aortic pathologies involving aortic arch is safe and effective with good short and mid-term results, greatly expanding the indication of endovascular aortic repair.



Recent Publications

1. Xydias S, Mihos C G, Williams R F, et al. (2017) Hybrid repair of aortic arch aneurysms: a comprehensive review. *J Thorac Dis*, 9(Suppl 7):S629-S634.
2. Tadros R, Safir S R, Faries P L, et al. (2017) Hybrid repair techniques for complex aneurysms and dissections involving the aortic arch and thoracic aorta. *Surg Technol Int*, 30:243-247.
3. Pagliariccio G and Gatta E (2017) Rupture of a complex aortic arch aneurysm: hybrid repair. *Eur J Vasc Endovasc Surg*, 54(3):330.
4. Arnaoutakis G J and Szeto W Y (2016) Hybrid aortic arch repair: The ultimate solution or a stop along the way to a total endovascular arch reconstruction? *J Thorac Cardiovasc Surg*, 152(1):169-170.
5. Faure E M, Canaud L, Marty Ane C, et al. (2016) Hybrid aortic arch repair for dissecting aneurysm. *J Thorac Cardiovasc Surg*, 152(1):162-168.

Biography

Yu Guo Xue is specialized on the diagnosis and interventional treatment of aortic diseases, including dissection, intramural hematoma, penetrating aortic ulcer, aneurysm, pseudoaneurysm and coarctation. Every year, more than 300 patients with aortic diseases underwent endovascular treatment at Beijing aortic diseases center.

xueyuguo2006@163.com

May 24-25, 2018

London, UK

Yun-Nan Lin, J Vasc Endovasc Therapy 2018, Volume 3
DOI: 10.21767/2573-4482-C1-002

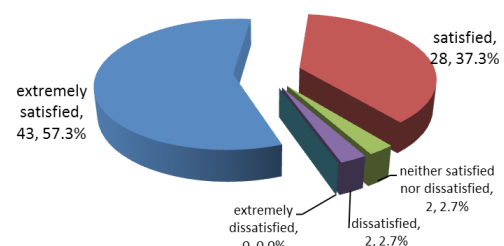
MANAGEMENT OF VENOUS ULCERS OF PRIMARY VARICOSE VEINS THROUGH ENDOSCOPIC ASSISTED SURGERY

Yun-Nan Lin^{1,2}¹Kaohsiung Medical University Hospital, Taiwan²Kaohsiung Municipal Siaogang Hospital, Taiwan**Aims:** Venous ulcers of primary varicose veins were managed through endoscopic assisted surgery.**Materials and Method:** Between January 2004 and December 2016, 1241 legs with primary varicose veins were operated on through endoscopic-assisted surgery. Patients of secondary varicose veins were excluded. Of the 78 patients who had C6 ulcer were included in this study, 23 (29.5%) were male and 55 (70.5%) were female. 44 patients (56.4%) had venous ulcer on the left leg, 34 patients (43.6%) on the right leg, and 5 (6.4%) on both legs. The mean patient age was 59 years (range 30-84 years).

The clear illumination and magnified monitor view offered by an endoscope enable the identification of the varicose and non-varicose veins. The operation procedures will be demonstrated in a video. (<https://drive.google.com/open?id=0B9GW1JJYL1niVi1BNE1xZGxaeK0>)

Before the operation, the causative vein of the ulcer was detected and marked after the patient standing for 10-15 mins. The engorged vein proximal to the ulcer lesion is highly suspected as the causative vein.

The causative varicose veins could be identified definitely and dissected precisely from its proximal end and was along the whole vein down to the periphery and/or the base of the ulcer. Frequently, the associated incompetent perforating vein was dissected and divided. The causative veins were totally excised.

Results: The varicose veins were traced to the base or periphery of the 66 ulcers. 88.5% of the ulcers healed within 14 weeks. Two recurrent ulcers occurred due to residual varicose veins. Kaplan-Meier analysis revealed a five-year recurrence rate of 0.0%.**Conclusion:** In management of venous ulcer of primary varicose vein, endoscopic assisted surgery is a good alternative to achieve a low recurrence rate and high satisfaction rate.**Figure 1:** Satisfaction rate, 75 patients.

Recent Publications

1. Lin YN, Huang SH, Lin TY, Chou CK, Huang YH, Takahashi H, Lai CS, Lin SD, Lin TM. Micro-autologous fat transplantation for rejuvenation of the dorsal surface of the ageing hand. J Plast Reconstr Aesthet Surg. 2017 In Press.
2. Lin YN, Hsieh TY, Huang SH, Liu CM, Chang KP, Lin SD*. Management of venous ulcers according to their anatomical relationship with varicose veins. Phlebology. 2017 Jan 1 [Epub ahead of print].
3. Kao WP, Lin YN, Lin TY, Huang YH, Chou CK, Takahashi H, Shieh TY, Chang KP, Lee SS, Lai CS, Lin SD, Lin TM*. Microautologous Fat Transplantation for Primary Augmentation Rhinoplasty: Long-Term Monitoring of 198 Asian Patients. Aesthet Surg J. 2016 Jun;36(6):648-56.
4. Lin SD*, Huang SH, Lin YN, Wu SH, Chang HW, Lin TM, Chai CY, Hsieh DJ, Chang KP. Injected Implant of Uncultured Stromal Vascular Fraction Loaded Onto a Collagen Gel: In Vivo Study of Adipogenesis and Long-term Outcomes. Ann Plast Surg. 2016 Mar;76 Suppl 1:S108-16.
5. Lai YW, Lee SS, Chang KP, Huang SH, Lin YN, Lin SD, Lai CS*. Blood supply classification and varied clinical

May 24-25, 2018
London, UK

manifestations of skeletal muscle infarction. *Ann Plast Surg.* 2015 May;74 Suppl 2:S109-12.

6. Huang SH, Lin YN, Lee SS, Chai CY, Chang HW, Lin TM, Lai CS, Lin SD*. New adipose tissue formation by human adipose-derived stem cells with hyaluronic acid gel in immunodeficient mice. *Int J Med Sci.* 2015 Jan 8;12(2):154-62.
7. Hsieh TY, Lin YN, Lin SD*, Lai CS, Chang KP, Lee SS, Huang SH, Hou MF, Chen FM, Ou-Yang F. Immediate transverse rectus abdominis musculocutaneous flap reconstruction is associated with improved cancer-specific survival in locally advanced breast cancer. *Ann Plast Surg.* 2014 Sep;73 Suppl 1:S31-6.
8. Hsieh TY, Lin YN, Lin SD*, Lai CS, Chang KP, Lee SS, Huang SH, Hou MF, Chen FM, Ou-Yang F. Breast Cancer Patients With and Without Transverse Rectus Abdominus Myocutaneous Flap Reconstruction: Better Conformity with Practice Guideline is Associated With Improved Survival and Reduced Local Recurrence. *J Taiwan Soc of Plast Surg.* 2014;23(4):291-305.
9. Lin YN, Lin SD*, Chang KP. Endoscope-assisted surgery for management of varicosity in Klipper-Trenaunay syndrome: a case report. *J Taiwan Soc of Plast Surg.* 2013;22(4):314-20.
10. Lin YN, Lin SD*, Lai CS, Chang KP, Hou MF. Is It Safe For An Asian Woman To Be Pregnant After TRAM Flap Surgery For Breast Reconstruction? A Case Report. *J Taiwan Soc of Plast Surg.* 2012;21(4):343-50.
11. Lin YN, Lin SD*, Huang SH, Lee SH, Lai CS, Chang KP. Endoscopic Assisted Surgical Management of Superficial Thrombophlebitis in Patients with Primary Varicose Veins. *J Taiwan Soc of Plast Surg.* 2012;21(2):90-8.
12. Lin SD*, Huang SH, Lin YN, Wu SH, Chang HW, Lin TM, Chai CY, Lai CS. Engineering adipose tissue from uncultured human adipose stromal vascular fraction on collagen matrix and gelatin sponge scaffolds. *Tissue Eng Part A.* 2011 Jun;17(11-12):1489-98.

Biography

Dr. Lin manages the varicose veins with the assistance of endoscopic surgery to decrease the recurrence rate. He also performs immediate breast reconstruction with pedicled transverse rectus abdominis myocutaneous flap. He is specialized in the field of fat grafting and wound healing.

yunnan1123@gmail.com

May 24-25, 2018
London, UK

Mingjie Gao et al., J Vasc Endovasc Therapy 2018, Volume 3
DOI: 10.21767/2573-4482-C1-002

OPTIMAL ULTRASOUND CRITERIA FOR GRADING STENOSIS OF THE SUPERFICIAL FEMORAL ARTERY

Mingjie Gao, Yang Hua, Xinyu Zhao, Lingyun Jia, Jie Yang and Beibei Liu

Xuanwu Hospital of Capital Medical University, China

Objective: This retrospective study determined the duplex ultrasound scanning (DUS) criteria for detecting 50-69% and 70-99% stenosis of the superficial femoral artery (SFA). Methods Examinations of 278 limbs in 185 subjects with peripheral arterial disease were performed. Duplex ultrasound scanning was used to measure the residual diameter of the stenotic segment and the diameter of the original lumen, the peak systolic velocity (PSV) at the stenotic segment of the SFA (PSVst), the segment proximal to the stenosis (PSVpro), and the popliteal artery (PSVpop; distal to the stenosis). The ratios PSVst/PSVpro and PSVst/PSVpop were calculated. Receiver operator characteristic curves were plotted, with digital subtraction angiography as the reference.

Results: The studied limbs included 205 limbs with stenotic SFAs: 43 (15.5%) with 50-69% stenosis, and 162 (58.3%) with 70-99% stenosis. The control group consisted of 73 limbs: 44 (15.8%) were normal and 29 (10.4%) had <50% stenotic SFAs. According to the results of the ROC analysis, the optimal cut-off values for detecting 50-69% stenosis of the SFA were PSVst \geq 210 cm/s, PSVst/PSVpop \geq 2.5, or PSVst/PSVpro \geq 1.7. PSVst was the most useful hemodynamic parameter for predicting 50-69% stenosis, with 95.6% sensitivity, 98.6% specificity, and 96.4% accuracy. For predicting 70-99% stenosis of the SFA, the thresholds were PSVst \geq 275 cm/s, PSVst/PSVpop \geq 4.0, or PSVst/PSVpro \geq 2.5. PSVst/PSVpop \geq 4.0 was the most useful Doppler parameter, with 96.3% sensitivity, 93.9% specificity, and 95.3% accuracy. PSVst/PSVpop PSVst was the best combined parameter to detect SFA 70-99% stenosis with 96.3% sensitivity, 94.8% specificity, and 95.7% accuracy. Conclusions This study determined the cutoff values of DUS hemodynamic parameters for diagnosing 50-69% and 70-99% stenosis of the SFA. PSVst/PSVpop may be a better ratio parameter than the traditional parameter of PSVst/PSVpro for diagnosing SFA stenosis, especially for 70-99% stenosis

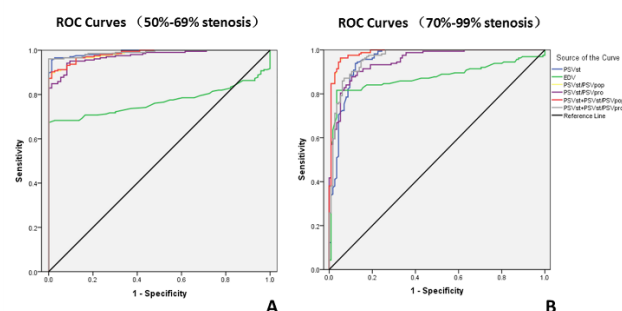


Figure 1: ROC curves for 4 individual parameters and 2 combined parameters. (A) 50-69% stenosis. (B) 70-99% stenosis. Blue, PSV at the stenotic segment; green, EDV at the stenotic segment; yellow, PSVst/PSVpop; purple, PSVst/PSVpro; red, PSVst+PSVst/PSVpop; grey, PSVst+PSVst/PSVpro. The black line indicates the reference values. ROC= Receiver operator characteristic.

Recent Publications

1. Conte MS, Pomposelli FB, Clair DG, et al. Society for Vascular Surgery practice guidelines for atherosclerotic occlusive disease of the lower extremities: management of asymptomatic disease and claudication. J Vasc Surg 2015; 61:2S-41S.
2. Cossman DV, Ellison JE, Wagner WH, et al. Comparison of contrast arteriography to arterial mapping with color-flow duplex imaging in the lower extremities. J Vasc Surg 1989; 10:522-8; discussion 28-9.2.
3. Gao M, Hua Y, Zhao X, et al. Incidence and Predictors of In-stent Re-Stenosis in the Superficial Femoral Artery: Evaluation of Long-Term Outcomes by Color Duplex Ultrasound. Ultrasound Med Biol 2016; 42:717-26.
4. Khan SZ, Khan MA, Bradley B, et al. Utility of duplex ultrasound in detecting and grading de novo femoropopliteal lesions. J Vasc Surg 2011; 54:1067-73.
5. Zwiebel WJ, Pellerito JS. Introduction to vascular ultrasonography, 6th edition; Philadelphia,PA, Elsevier Press, 2012;294-30.

Biography

Associate Professor Mingjie Gao has worked in the field of vascular ultrasound for more than 10 years and has good expertise in lower extremity artery ultrasound. Her research focuses on the following areas: 1) Systemical evaluation of the vessel structures and hemodynamics in lower extremity artery by multiple-modes of ultrasound in patients with peripheral arterial disease. 2) Evaluation of the vessel structures and hemodynamic alterations before and after interventional therapy such as stenting. She and her study group also performed a series of studies in the risk factors for SFA in stent restenosis. She has published almost 10 articles in the above areas.

gaomingjie163@163.com

May 24-25, 2018
London, UK

Mónica M Torres Fonseca, J Vasc Endovasc Therapy 2018, Volume 3
DOI: 10.21767/2573-4482-C1-002

INCREASED GALECTIN-3 LEVELS ARE ASSOCIATED WITH ABDOMINAL AORTIC ANEURYSM PROGRESSION AND INHIBITION OF GALECTIN-3 DECREASE ELASTASE-INDUCED AAA DEVELOPMENT

Mónica M Torres Fonseca

Autonomous University of Madrid, Spain

The evolution of abdominal aortic aneurysm (AAA) is unpredictable. Moreover, no specific treatment exists for AAA, except surgery to prevent aortic rupture. Galectin-3 has been previously associated with cardiovascular disease (CVD), but its potential role in AAA has not been addressed. Galectin-3 levels were increased in plasma of AAA patients (n=225) compared to controls (n=100). Moreover, galectin-3 concentrations were associated with need for surgical repair, independently of potential confounding factors. Galectin-3 mRNA and protein expression were increased in human AAA samples compared to healthy aortas. Experimental AAA in mice was induced by aortic elastase perfusion. Mice were treated intravenously with the galectin-3 inhibitor modified citrus pectin (MCP, 10 mg/kg, every other day) or saline. Similar to humans, galectin-3 serum and aortic mRNA levels were also increased in elastase-induced AAA mice compared to control mice. Mice treated with MCP showed decreased aortic dilation, as well as elastin degradation, vascular smooth muscle cell (VSMC) loss and macrophage content at day 14 post-elastase perfusion compared with control mice. The underlying mechanism(s) of the protective effect of MCP was associated with a decrease in galectin-3 and cytokine (mainly CCL5) mRNA and protein expression. Interestingly, galectin-3 induced CCL5 expression by a mechanism involving STAT3 activation in VSMC. Accordingly, MCP treatment decreased STAT3 phosphorylation in elastase-induced AAA. In conclusion, increased galectin-3 levels are associated with AAA progression, while galectin-3 inhibition decreased experimental AAA development. Our data suggest the potential role of galectin-3 as a therapeutic target in AAA

Recent Publications

1. Dale M A, Ruhlman M K and Baxter B T (2015) Inflammatory cell phenotypes in AAAs: their role and potential as targets for therapy. *Arterioscler Thromb*

Vasc Biol 35:1746-55.

2. Daniels L B, Clopton P, Laughlin G A, Maisel A S and Barrett Connor E (2014) Galectin-3 is independently associated with cardiovascular mortality in community-dwelling older adults without known cardiovascular disease: the Rancho Bernardo study. *Am Heart J* 167:674-82.
3. Filipe M D, Meijers W C, Rogier van der Velde A and de Boer R A (2015) Galectin-3 and heart failure: prognosis, prediction & clinical utility. *Clin Chim Acta* 443:48-56.
4. Jagodzinski A, Havulinna A S, Appelbaum S, Zeller T, Jousilahti P, Skytte Johanssen S, Hughes M F, Blankenberg S and Salomaa V (2015) Predictive value of galectin-3 for incident cardiovascular disease and heart failure in the population-based FINRISK 1997 cohort. *Int J Cardiol* 192:33-9.
5. Maiolino G, Rossitto G, Pedon L, Cesari M, Frigo A C, Azzolini M, Plebani M, and Rossi G P (2015) Galectin-3 predicts long-term cardiovascular death in high-risk patients with coronary artery disease. *Arterioscler Thromb Vasc Biol* 35:725-3.

Biography

Mónica M Torres Fonseca is a Vascular Surgeon who, along with her clinical work, devotes a large part of her time to the field of research, which she is passionate about. She and her group's work are mainly directed to the study of AAA for years. This is the object of study in her doctoral thesis, based on the diagnosis, prognosis and treatment of AAA through clinical and experimental studies. She is concerned about the situation of patients with AAA without surgical indication, who cannot be offered effective medical treatment at this time. Therefore, part of their study aims to determine possible particles that can reduce or delay the progression of the aneurysm, which would mean a substantial change in the prognosis of these patients.

monitorfon@gmail.com

May 24-25, 2018
London, UK

Soumya Guha, J Vasc Endovasc Therapy 2018, Volume 3
DOI: 10.21767/2573-4482-C1-002

DOUBLE AORTIC ARCH WITH TOF: SINGLE STAGE APPROACH VIA MEDIAN STERNOTOMY.

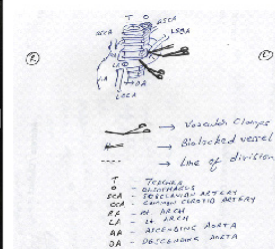
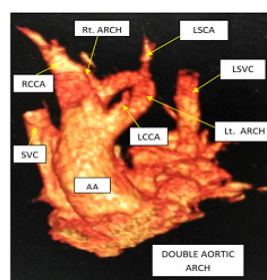
Soumya Guha

PGIMER & Dr. RML Hospital, India

Double aortic arch (DAA) is a rare accompaniment of Tetralogy of Fallot (TOF). This case report describes successful management of TOF with DAA via median sternotomy in a 3-year-old child. The approach selection for a surgery in these patients is often quite puzzling to the surgeons especially those encountering it for the first time. The non-dominant arch is divided at the atretic segment. In the absence of an atretic segment the non-dominant arch is divided between the ipsilateral subclavian artery and the descending aorta. The distal non-dominant arch beyond the ipsilateral subclavian artery is often difficult to access from the midline and accounts for the controversy regarding the approach (thoracotomy vs median sternotomy) and for the prevalence of the two-incision approach wherein the arch is tackled by a separate posterolateral thoracotomy. We modified the placement of clamps to simplify the division of non-dominant arch. We believe that division of the non-dominant arch can be safely undertaken from the midline when coexisting cardiac anomalies mandate an intracardiac repair under cardiopulmonary bypass which also facilitates division of the non-dominant arch

Recent Publications

1. Harper AR, Dai M, Prabhatha RM. Tetralogy of fallot with double aortic arch. *Cardiol Young*. 2011;21:695–696.
2. Emani SM. Sabiston & Spencer: Surgery of the Chest. 8th edition. Elsevier; 2010.
3. Kouchoukos NT, Blackstone EH, Kirklin JK, Hanley FL. Kirklin/Barratt-Boyes: Cardiac Surgery. 4th ed. Elsevier; 2012.
4. Pankaj B, Munesh T, Bhan A. Dysphagia in an Adult Tetralogy of Fallot with Double aortic arch. *Images*



Paediatr Cardiol. 2013;15(3):6-13

5. Dan, Z., Qiangfu, H., Liang, T., Changyu, L., Linnan, D. and Laichun, S. Repair of double aortic arch in patients with concomitant cardiac anomalies. *J Card Surg*. 2016; 31: 635–638.
6. Sachin Talwar, Anubhav Gupta, Shiv Kumar Choudhary, Balram Airan. Absent left pulmonary artery and double aortic arch in tetralogy of Fallot: reconstruction using homograft saphenous vein or iliac artery. *Interact CardioVasc Thorac Surg*. 2009; 8 (2): 277-279.

Biography

Dr. Soumya Guha is currently completing his residency programme in Cardio-thoracic and vascular Surgery from the reputed PGIMER & RML Hospital, New Delhi. He is already a specialist in the field of General Surgery from one the premier government hospitals in his country, the Safderjung Hospital in New Delhi which sees a daily footfall of roughly 8000-10000 patients. He has published papers in internationally acclaimed journals and has presented his papers as well in international conferences.

surya_blue@yahoo.co.uk

May 24-25, 2018
London, UK

Sanjay Singh et al., J Vasc Endovasc Therapy 2018, Volume 3
DOI: 10.21767/2573-4482-C1-002

CONGENITAL ABSENCE OF INFERIOR VENA CAVA ASSOCIATED WITH LOWER LIMB AND PELVIC VENOUS THROMBOSIS

Sanjay Singh, Asghar Butt, Muhammad Usman Cheema and Jayarama Mohan

United Lincolnshire Hospitals NHS Trust, UK

Background: Congenital absence of inferior vena cava (IVCA) is an extremely rare anomaly with an estimated prevalence of 1%. It is recognised to be associated with deep vein thrombosis (DVT) particularly in the young. There can be clues indicating the presence of such an anomaly from a young age. Patients with IVC anomalies usually develop compensatory circulation through the collateral veins; despite the compensatory circulation, the venous drainage of the lower limbs is often insufficient leading to venous stasis and thrombosis. We present two cases of young adult aged 17 and 28 years who presented with groin pain, swelling and lower limb DVT respectively. The clinical features, diagnostic and therapeutic options are discussed.

Discussion: IVCA is an uncommon but well recognised anomaly. Most of the patients with IVCA are asymptomatic and detected incidentally during radiological procedures or abdominal surgery. Common symptoms are lower extremity pain, swelling, ulcers, and sometimes nonspecific pain in the lower back and abdomen. The most reliable non-invasive methods for diagnosing IVC anomalies are CT and MRI. There is no role of surgical correction in the management of these patients. There is no consensus regarding the duration of anti-coagulation but it would seem sensible for them to remain on life-long anticoagulation given the on-going risk of further DVT.

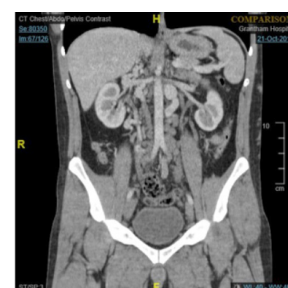Conclusion: All vascular surgeons should consider the possibility of IVC anomalies in a young adult presenting with unexplained, extensive, or bilateral DVT. The diagnosis can be challenging and requires detailed imaging studies. Further diagnostic workup and management should be considered for any coagulation abnormalities and long-term anticoagulation.

Recent Publications

1. Sakellaris G, Tilemis S, Papakonstantinou O, Bitsori M, Tsetis D and Charissis G (2005) Deep venous thrombosis in a child associated with an abnormal inferior vena cava.

Acta Paediatrica 94:242-244.

2. Gayer G, Luboshitz J, Hertz M, Zissin R, et al. (2003) Congenital anomalies of the inferior vena cava revealed on CT in patients with deep vein thrombosis. AJR Am J Roentgenology 180: 729-732.
3. Iqbal J and Nagaraju E (2008) Congenital absence of inferior vena cava and thrombosis: a case report. Journal of Medical Case Reports 2:46.
4. Koc Z and Oguzkurt (2007) Interruption or congenital stenosis of the inferior vena cava: prevalence, imaging and clinical findings. European Journal of Radiology 62: 257-266.
5. Koppisetty S, Smith A G and Dhillon R K (2015) Incidental finding of inferior vena cava atresia presenting with DVT following physical assertion. Case Reports in Emergency Medicine 2015:146304.



Biography

Sanjay Singh has his expertise and passion in Vascular and Endovascular Surgery. He has done complex aortic endovascular fellowship and is a Vascular Consultant working in United Kingdom. His open and contextual surgical techniques are based on researched and practiced models which helped to create new pathways for innovation. He has achieved this aptitude after years of experience in research and teaching in university hospitals and institutions. The ever-responsive and adapting field of Endovascular Surgery has improved the survival rates of high risk patients.

dr_sanjaysingh@hotmail.com

May 24-25, 2018
London, UK

Qinchang Chen et al., J Vasc Endovasc Therapy 2018, Volume 3
DOI: 10.21767/2573-4482-C1-002

ADMISSION GLUCOSE AND ICU MORTALITY IN ABDOMINAL AORTIC ANEURYSM PATIENTS: A RETROSPECTIVE ANALYSIS OF THE MIMIC-III CLINICAL DATABASE

Qinchang Chen¹ and Huang Kai²

¹Sun Yat-sen University, China

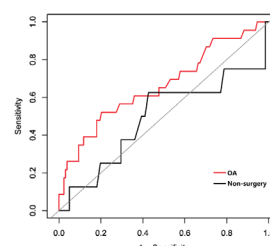
²Sun Yat-Sen Memorial Hospital, China

Statement of the Problem: Abdominal aortic aneurysm (AAA) affects about 10% of men aged 70 and the mortality can up to 85 to 90% once it ruptures. The association between admission glucose and ICU mortality in AAA patients remained controversy in previous studies. Though hyperglycemia has been reported as the important determinant of mortality for AAA in several retrospective studies, the significant association was not observed between the trend in AAA mortality and trend in blood glucose from the population in 19 western countries. We aimed to replicate these studies and assessed the effect of hyperglycemia on ICU mortality in patients with AAA.

Methodology & Theoretical Orientation: A retrospective study was conducted in Multiparameter Intelligent Monitoring in Intensive Care III (MIMIC III) database. The potential risk factors were selected from the univariate analysis and applied into the multivariate analysis. Then, the receiver operating characteristic (ROC) curve and the area under the curve (AUC) were used to confirm the power of predictive effect.

Findings: A total of 225 patients with 32 ICU deaths and 192 patients alive were included. After the correction of potential confounding factors, such as age, AAA condition, diabetes and so on, admission glucose was significantly associated with the mortality in patients undergoing surgery (OR 1.009; 95% CI 1.002-1.015), not observed in non-surgery patients. Further ROC curve indicated that glycemic status had the better predictive value for the mortality in the surgery group (AUC=0.6624) than the non-surgery group (AUC=0.4908). The glucose level at 200 mg/dl was demonstrated as the best threshold.

Conclusion & Significance: The association between high glucose concentration and poor survival was confirmed in the AAA patients undergoing surgery; but not observed in the non-surgery group, which provided the potential answer to the controversy and highlighted the positive screening and aggressive glucose control before AAA surgery.



Recent Publications

1. Kai H, Xixia L, Miaoyun L, et al. (2017) Intraoperative nerve monitoring reduces recurrent laryngeal nerve injury in geriatric patients undergoing thyroid surgery. *Acta Oto-Laryngologica* 137(12):1275-1280.
2. Huang K, Luo D, Huang M, et al. (2013) Protection of parathyroid function using carbon nanoparticles during thyroid surgery. *Otolaryngology-Head and Neck Surgery* 149(6):845-850.
3. Tang Y, Chen J, Huang K, et al. (2017) The incidence, risk factors and in-hospital mortality of acute kidney injury in patients after abdominal aortic aneurysm repair surgery. *BMC Nephrology* 18(1):184.
4. Luo D, Chen H, Lu P, et al. (2017) CHI3L1 overexpression is associated with metastasis and is an indicator of poor prognosis in papillary thyroid carcinoma. *Cancer Biomarkers* 18(3):273-284.

May 24-25, 2018
London, UK

5. Jiang Y, Wang M, Huang K, et al. (2012) Oxidized low-density lipoprotein induces secretion of interleukin-1 β by macrophages via reactive oxygen species-dependent NLRP3 inflammasome activation. *Biochemical and Biophysical Research Communications* 425(2):121-126.

Biography

Huang Kai is the expert in the surgery of peripheral vascular surgery and thyroid surgery. He spares no effort to improve the survival in surgery and

find out the potential factor to predict the outcome after surgery, especially the surgery in abdominal aortic aneurysm, which is with high mortality.

Chen Qinchang, Male, born in January 1995, student of Dr Huang Kai, has been studying in Clinical Medicine Major of Zhongshan School of Medicine in Sun Yat-sen University from August 2013. Without any unexpected accident, he will be awarded the Bachelor Degree in Medicine. Though he is the undergraduate at Grade 5, he has been the expert at data mining, gene chip analysis and clinical research.

huangk37@mail.sysu.edu.cn
chenqch6@mail2.sysu.edu.cn