

May 24-25, 2018  
London, UK

Yu Guo Xue et al., J Vasc Endovasc Therapy 2018, Volume 3  
DOI: 10.21767/2573-4482-C1-002

## HYBRID REPAIR OF AORTIC PATHOLOGY INVOLVING AORTIC ARCH

Yu Guo Xue, Li Zhong Sun, Jun Zheng, Shangdong Xu and Lian Jun Huang

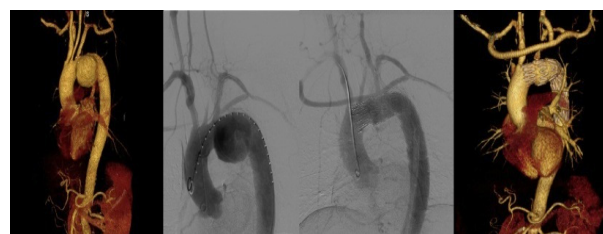
Beijing Aortic Diseases Center, China

**Purpose:** To evaluate the safety and efficacy of hybrid repair for aortic lesions involving aortic arch.

**Materials & Methods:** From February 2009 to September 2016, 81 consecutive patients (70 men; mean age 63.4±7.9 years, range 32-79) underwent brachiocephalic bypass combined with stent-graft implantation (hybrid) and were enrolled in the study. Aortic pathologies included Stanford type B aortic dissection (n=22), aortic arch aneurysm (n=26), aortic arch pseudoaneurysm (n=14), aortic arch penetrating ulcer (n=11) and proximal endoleak (n=5) or pseudoaneurysm formation (n=3) after thoracic endovascular aortic repair (TEVAR). Hybrid repair comprised 3 landing in zone 0, 44 landing in zone 1 and 34 landing in zone 2. Simultaneous procedures included left subclavian artery embolization (n=57), endovascular abdominal aortic repair (n=1), coronary artery bypass (n=1), left common carotid endarterectomy (n=1) and renal stenting (n=4). Follow-up was performed at 1 month, 3 months, 6 months, 1 year and annually thereafter to investigate endoleak, patency of vascular graft and exclusion of aortic pathology.

**Results:** Technical success was 100%. Instant endoleak was observed in 9 (11.1%, 7 type I, 2 type II) cases on postoperative angiography. Perioperative complications included iatrogenic ascending aortic dissection (n=1, 1.2%), stroke (n=2, 2.5%), anastomotic bleeding (n=1, 1.2%), both lower limbs thrombosis (n=1, 1.2%) and acute respiratory failure (n=2, 2.5%). Early morbidity was 8.6% (7/81). Early death occurred in 5 cases (6.2%) due to stroke, anastomotic bleeding, acute respiratory failure and sudden death. Follow-up was complete in 100% for 39.4±14.5 months (range 1-81 months). During follow-up, all the vascular grafts were patent. The overall endoleak rate was 13.58% (11/81). Late mortality was 6.2% (5/81) and morbidity was 14.5% (8/81).

**Conclusions:** Hybrid repair of aortic pathologies involving aortic arch is safe and effective with good short and mid-term results, greatly expanding the indication of endovascular aortic repair.



### Recent Publications

1. Xydas S, Mihos C G, Williams R F, et al. (2017) Hybrid repair of aortic arch aneurysms: a comprehensive review. *J Thorac Dis*, 9(Suppl 7):S629-S634.
2. Tadros R, Safir S R, Faries P L, et al. (2017) Hybrid repair techniques for complex aneurysms and dissections involving the aortic arch and thoracic aorta. *Surg Technol Int*, 30:243-247.
3. Pagliariccio G and Gatta E (2017) Rupture of a complex aortic arch aneurysm: hybrid repair. *Eur J Vasc Endovasc Surg*, 54(3):330.
4. Arnaoutakis G J and Szeto W Y (2016) Hybrid aortic arch repair: The ultimate solution or a stop along the way to a total endovascular arch reconstruction? *J Thorac Cardiovasc Surg*, 152(1):169-170.
5. Faure E M, Canaud L, Marty Ane C, et al. (2016) Hybrid aortic arch repair for dissecting aneurysm. *J Thorac Cardiovasc Surg*, 152(1):162-168.

### Biography

Yu Guo Xue is specialized on the diagnosis and interventional treatment of aortic diseases, including dissection, intramural hematoma, penetrating aortic ulcer, aneurysm, pseudoaneurysm and coarctation. Every year, more than 300 patients with aortic diseases underwent endovascular treatment at Beijing aortic diseases center.

xueyuguo2006@163.com