



# Hepatoprotective Effects of Herbal Drug on Adriamycin Induced Toxicity in Developing Chick Embryos

Shingadia Hitesh U\*

SVKM's Mithibai College of Arts, Chauhan Institute of Science and A. J. College of Commerce and Economics Vile Parle - West Mumbai 400 056 Maharashtra-India

Date of Receipt- 28/07/2014  
Date of Revision- 04/08/2014  
Date of Acceptance- 17/08/2014

## ABSTRACT

Anti-neoplastic agents used in chemotherapy for cancer are observed to cause deleterious adverse effects. In present study Adriamycin administration resulted in developmental deformities showing teratogenic effects on the developing chick embryos in dose verses time dependent manner. The treated group of chick embryos showed decrease in the weight vis-à-vis reduction in the volume of amniotic fluid probably due to reduced transport of albumin; oxidative stress caused by generation of free radicals, disturbed ionic channels and/or inactivation of signal transduction pathways. Thus liver acting as a major sink for detoxification of harmful metabolites gets damaged, leaking its contents that diffuse through vascular tissues raising levels of marker enzymes like AST, ALT, ALP and LDH in amniotic fluid when compared with control group of chick embryos ( $p \leq 0.05$ ). However levels of marker enzymes were radically reduced ( $p \leq 0.01$ ) in a dose-dependent manner, when pretreated with alcoholic leaf extract of *vitex negundo* Linn. The photomicrographs of liver with Adriamycin treatment showed cellular swelling of hepatocytes with diffused mononuclear cell infiltration in hepatic parenchyma, derangement of hepatic cords, granular cytoplasmic and vacuolar changes indicative of hepatic degeneration. On treatment with crude herbal drug, liver under stress of Adriamycin revealed mild degree of pathological alterations of degenerative nature in hepatocytes with focal marginal changes in hepatic parenchyma without any inflammation. This may be a sign of the hepatoprotective effect of herbal extract due to presence of phenolics, flavonoids and other compounds over Adriamycin induced histopathological changes in liver.

**Keywords:** *Vitex negundo*, Chick embryo, Liver, Amniotic fluid, Adriamycin.

## Address for Correspondence

SVKM's Mithibai  
College of Arts,  
Chauhan Institute of  
Science and A. J.  
College of Commerce  
and Economics Vile  
Parle - West Mumbai  
400 056 Maharashtra-  
India.

### E-mail:

[hiteshshingadia26@gmail.com](mailto:hiteshshingadia26@gmail.com)

## INTRODUCTION

Anti-tumor drugs are observed to cause detrimental consequences in the embryos of human and experimental animals. Adriamycin (ADR) synonymously known as Doxorubicin is one of the most active anti-neoplastic agents developed for the treatment of tumors of various types viz. acute leukemia's, malignant lymphomas, head and neck, breast, bladder, endometrial, hepatic and prostate cancers. The morphological effects of Adriamycin on chick, mice and rat embryos in-vivo are well documented by eminent researchers in past<sup>2,15,13,22</sup>. At significantly elevated doses ADR is genotoxic and carcinogenic. Adriamycin as an anti-cancer drug functions by redox cycling of ADR semiquinone radical, intercalation of DNA, meddling in the functioning of DNA topoisomerase II, inhibition of transcription and translation activities, disquieting the cellular functions. Within the cell ADR interacts with several enzymes like oxidoreductases. Literature from animals and humans data suggest that most of the anti-neoplastic drugs may have lethal effects on the foetus causing increased incidence of prematurity, intrauterine growth retardation, stillbirths and lower birth weight<sup>14</sup>. Adriamycin toxicity is of grave concern during gestation period causing malformation and teratogenic defects in developing foetus. Study on several animal models have also shown a high risk of congenital anomalies, which in humans occur mainly when the anti-cancer drugs are administered during the first trimester of pregnancy<sup>14</sup>.

The chick embryo is proved to be a well known animal model that has been comprehensively studied since Aristotle's time<sup>19</sup>. An escalating significance of chick embryo as a substitute animal model for the research in Biosciences over the mammalian models is correlated to its simplicity and close to the ground cost. Furthermore, moral

precincts and restrictions on use of the mammalian models are escalating by its leap and bound. Also the study on amniotic fluid is widely validated in clinical diagnosis and management, never the less analysis of amniotic fluid is well thought-out as an Index of foetal health. Even though chick embryos are less extensively used for the assessment of new drug carriers, the United States FDA has approved products pre-clinically tested with chick embryos<sup>19</sup>.

Since time immemorial mankind has been exploiting the medicinal potential of herbal extracts through Ayurveda, Siddha and Unani system of medication across Asia. Modern form of medication sporadically causes side effects that have made herbal drugs a promising prospect through the alternative form of medicines. The crude extracts of herbal drugs often have mixture of compounds: the mere consortia of molecules could be responsible to augment the efficacy of drug for its defensive and/or curative effects. Hence crude leaf extract of *vitex negundo* Linn. contains most important constituents containing phenolics and, flavonoids akin to casticin, isoorientin, chrysophenol-D, luteolin, p-hydroxybenzoic acid and D-fructose. The main constituents of the oil are sabinene, linalool, terpinen-4-ol,  $\beta$ -caryophyllene and  $\alpha$ -guaiene. *Vitex negundo* Linn. also called 'Nirgundi' belonging to Family: Verbenaceae was used in the present investigation (Fig. 2). Nirgundi is extensively used in folk medicine in South and Southeast Asia. Heated nirgundi leaves are tied over the affected part in headache, scrotal swelling, synovitis, arthritic pain and rheumatism. Leaves decoction is used for bath and in endometritis, colitis and orchitis. In nasoral infections like pharyngitis, stomatitis, sinusitis and common cold, gargles with the decoction of leaves or even smoke of the

heated dry leaves is effective. *In vitro* and animal studies have shown that the plant has potential anti-inflammatory<sup>5</sup>, antibacterial<sup>16</sup>, antifungal<sup>18</sup> and analgesic<sup>7</sup> activities. Consequently the present study focuses on the embryo protective activity of *vitex negundo* Linn. on Adriamycin induced toxicity in the developing chick embryo.

## MATERIALS AND METHODS

The fresh leaves were collected locally from in and around Mumbai and authenticated (59971), Fig. 2. The leaves were shade dried for a week and powdered using a grinder. The sieved powder of leaves was subjected to soxhlet extraction using ethanol that gave high extractive value. The extract was filtered and ethanol was vacuum evaporated at 55°C. The alcoholic extract was then stored at -20°C until further use. Adriamycin (Doxorubicin hydrochloride) from Pfizer was procured and used. All other chemicals and reagents were of analytical grade and purchased from Merck, Lobachem and Qualigens. The diagnostic kits for biochemical assays were purchased from Span Diagnostics and Biolabs Pvt. Ltd.

### Incubation and maintenance of eggs

The zero-day old freshly laid fertilized eggs were procured from Central Poultry Farm (WR), Government of India, Goregaon, Mumbai, Maharashtra (India). The eggs were cleaned with distilled water, wiped with 70% alcohol and placed in incubator set at 37°C with relative humidity of 58-60% maintained by keeping tray filled with water inside the incubator. The eggs were rotated manually and examined through candling every day for the proper growth and viability. The eggs with dead embryos were immediately removed from the incubator. Eggs were candled to locate the injection site for the administration of the drug, avoiding membrane bound blood vessels that were marked 2.0 cm below the air sac<sup>14</sup>.

### Embryo toxicity study

The 12 days old chick embryos were selected after candling for the toxicity studies. These eggs were divided into four groups containing six embryos in each group. Based on the LD<sub>50</sub> values, embryos were administered with Adriamycin (50, 60 and 70 µg) on 12<sup>th</sup> day. Simultaneously normal saline was administered in embryos of control group by injecting into air sac. After administration, the injection site was sealed with molten paraffin and eggs were returned to incubator for further incubation. The embryos were scored for morphological alterations; change in volume of amniotic fluid and body weight, if any at the end of 48 hours of incubation by comparing ADR treated groups with the respective control.

### Experimental design

To study embryo protective effect of alcoholic leaf extract of *vitex negundo* Linn. in Adriamycin induced toxicity in chick embryos experimental set up was divided into five groups of six embryos each (Table 1). The embryo protective role of leaf extract was assessed after 48 hrs. of incubation and treatment.

### Collection of embryonic tissues, amniotic fluid and biochemical analysis

After experimental period of 48 hrs, 12 days old embryos were sacrificed by opening air sac. Embryos were dissected; vital tissues were collected aseptically and stored at -20°C until further use. Amniotic fluid was collected aseptically from incubated eggs and centrifuged at 3000 rpm for 10 min. to remove cellular debris. Clear supernatant was used for biochemical assays of marker enzymes like Alanine Aminotransferase<sup>10</sup>, Aspartate Aminotransferase<sup>12</sup>, Alkaline Phosphatase<sup>11</sup> and Lactate Dehydrogenase<sup>3</sup> in the amniotic fluid.

### Histopathology of embryonic tissues

Liver tissue was immediately washed in chilled saline and fixed in neutral formalin fixative to prevent autolysis and preserve the shape, structure and chemical constituents of the tissue<sup>6</sup>. After 24 hrs. of fixation the tissue were dehydrated with alcohol and subjected to the process of infiltration in paraffin wax (M.P. 52-54°C). Paraffin blocks were prepared and sections were cut on the microtome at 4-5µm thickness. The ribbons were taken on slides and passed through xylene to dewax the tissue. The dewaxed tissues were dehydrated with alcohol. The tissues were stained with Ehrlich's Haematoxyline and Eosin Y stains<sup>9</sup>. Finally the sections were mounted in Diether Plasticizer Xylene and photomicrographs were taken using digital camera.

### Statistical analysis

All the results were expressed as mean  $\pm$  standard error for six embryos in each group. Statistical software Origin 8.5 was used for analysis of variance. Significance was measured as  $p \leq 0.05$  and  $p \leq 0.01$  respectively.

## RESULTS AND DISCUSSION

The chemical structure of Adriamycin is prone to free-radical formation; in addition, its administration also causes a decrease in intracellular antioxidants normally responsible for preventing free-radical damage<sup>15</sup>. The present study revealed a considerable decrease in the volume of amniotic fluid and weight of the 12 days old developing chick embryos on exposure to Adriamycin when compared with the control group of chick embryo in a dose verses time dependent manner (Table 2). In the embryos there is an antioxidant/pro-oxidant balance in tissues, which accounts for normal embryonic development and post-hatch chick viability<sup>20</sup>. ADR induces production of free radicals, which along with reactive metabolites are

either detoxified by complexing with glutathione that is considered to be critical in protection against embryo toxicants<sup>19</sup>. However in absence of glutathione and/or due to its reduction throughout the embryonic development, the free radicals generated might be reacting with macromolecules resulting in damage of the tissues. The reduction in the volume of amniotic fluid and weight of in the ADR treated developing chick embryos signify relative toxic effect of ADR at higher doses (70µg). Since the toxic metabolites probably might be getting detoxified especially in liver by forming complexes with glutathione at lower doses but unable to do so in decreased concentration of glutathione at higher dose and/or due to its scarcity in developing chick embryos.

The developing chick embryo not only derives nourishment but also protection from the amniotic fluid enclosed within the amnion. This fluid is rich in nutrients as well as mineral like proteins, carbohydrates, phospholipids, urea and electrolytes that serve to sustain the growth of the developing embryo. Amount of these constituents in amniotic fluid can be used as a diagnostic tool in the progress of development and growth of the embryo. Similar observations were also reported by other researchers<sup>4</sup> that justifies for the evaluation of biochemical constituents in the amniotic fluid. Shingadia and Dalvie (2014) reported momentous changes in the concentration of Urea, Uric acid, Creatinine, Sodium, Potassium, Calcium and Inorganic Phosphorus in the amniotic fluid of chick embryos and correlated it with pathohistological changes in the kidneys of developing chick embryos under stress of ADR. However noteworthy ameliorative role of leaf extract of *V. negundo* Linn. was also reported by the duo in their study. Alterations in the volume of amniotic fluid due to various teratogenic agents have been reported in past by many workers<sup>8</sup>. Albumin enters the amniotic fluid via the sero-amniotic

connection that nourishes and protects the developing chick embryo; however free radicals generated by ADR might have altered the mechanism of transport of albumin causing momentous decline in the volume of amniotic fluid and resulting in decrease in the weight of the developing chick embryos.

#### Changes induced by Adriamycin in levels of marker enzymes in amniotic fluid of chick embryo

A considerable increase ( $P \leq 0.01$ ) in activity of marker enzymes like AST, ALT, ALP and LDH was observed in ADR treated group of chick embryos (Table 3: Fig. 1). Trivial alterations were observed in Group 3 animals that were administered with ethanolic leaf extract of *vitex negundo* when compared with control Group 1 of chick embryos. Increased levels of these enzymes in amniotic fluid on ADR administration might be due to the effect of ADR on hepatic tissue possibly causing leakage of these enzymes into the amniotic fluid. ALP is a prototype of hepatic marker enzyme that reflects the pathological alterations in flow of bile<sup>17</sup>. ALP, ALT, AST and LDH levels were significantly normalized ( $P \leq 0.01$ ) in a dose-dependent manner, when pretreated with leaf extract of *V. negundo* Linn. Cytosolic enzymes viz. LDH, AST and ALT which serve as the diagnostic markers leak out from the damaged tissue to blood stream when cell membrane becomes permeable or ruptures<sup>4</sup>. The amount of these cellular enzymes in amniotic fluid reflects the alteration in plasma membrane integrity and/or permeability<sup>6</sup>. However in a similar study on rats<sup>23</sup> no significant change in AST and ALT levels was observed during administration of hydro alcoholic extract of pomegranate. Consequently these enzyme levels were considerably ( $P \leq 0.01$ ) normalized, when pretreated (6 hrs. prior to administration of ADR) with leaf extract of *vitex negundo* Linn. (Group 4 and 5) in a

dose-dependent manner at the end of 48 hrs. of incubation, after the treatment of ADR.

#### ADR induced histopathological changes in liver of chick embryo

ADR is known to inhibit various pumps and alter different ionic channels in the cells. It also inactivates the signal transduction pathways of the cell. The pathological changes in the liver tissue are triggered by the ADR induced oxidative stress. The much greater tendency to develop ADR toxicity in liver tissue may be due to accumulation of ADR as evidenced by histopathological examination.

#### Group 1 (Control)

The tissue section of liver of Group 1 embryos showed normal histological architecture (Fig. 3) with well formed hepatic parenchyma along with central vein and hepatic cords and also focal areas of aggregated nucleated RBCs suggestive of extra medullary foci of haemopoiesis.

#### Group 2 [Adriamycin (70 µg/egg)]

Photomicrographs showed substantial degree of pathological alterations in Liver as compared to all other groups (Fig. 4). The sections of liver showed diffused cellular swelling of hepatocytes with diffused lymphoid cell infiltration in hepatic parenchyma. The cytoplasm of hepatocytes was characterized by vacuolation. Derangement of hepatic cords with break in continuity of hepatic cords leading to pseudo-lobular pattern with grouping of three to five hepatocytes, granular cytoplasmic and vacuolar changes indicative of hepatic degeneration was apparent evident. These damaged hepatic cords leaked the enzymes that diffused into amniotic fluid altering its biochemical constituents.



Group 3 [Extract control group (200 µg of extract/egg)]

The liver sections from Group 3 showed normal hepatic parenchyma without focal changes in hepatocytes (Fig. 5) that signify the protective effect of herbal drug under study. Hepatoprotective activity of *vitex negundo* Linn. is well documented by workers<sup>1</sup> in past that corroborates with the present findings.

Group 4 [Dose 1 (100 µg of extract/egg) + Adriamycin (70 µg/egg)]

The photomicrograph of liver from Group 4 revealed mild degree of pathological alterations of degenerative nature in hepatocytes. The cytoplasm in hepatocytes showed reduced vacuolation, reduction in number of pycnotic nuclei and less derangement of hepatic cord (Fig. 6). Apparently liver parenchyma appeared near normal and reduced effect of Adriamycin induced pathological changes observed due to protective effect of herbal drug *vitex negundo* Linn was evident.

Group 5 [Dose 2 (200 µg of extract/egg) + Adriamycin (70 µg/egg)]

The Photomicrograph of liver from group 5 insignificant degenerative changes in hepatic parenchyma with more or less normal appearance of hepatocytes (Fig. 7). There was titular infiltration of mononuclear cells/Lymphocytes (in opposition to observed in photomicrograph of liver in Group 2). Hepatocytes retained its polygonal shape and hepatic cords retained its linear arrangement. This may perhaps indicate the protective consequence of herbal extract over Adriamycin induced pathological changes in hepatic tissue.

## CONCLUSION

Due to the paucity of antioxidants for embryo protection against anti-neoplastic agents, newer and better herbal drugs need to

be developed with antioxidant potentials that are efficient in maintaining peroxidant / antioxidant balance. Hence in the present investigation pretreatment with ethanolic leaf extract of *vitex negundo* proved beneficial by restoring antioxidant balance and biochemical variables in developing chick embryos. Nonetheless further characterization of herbal drug necessitates the efficacy studies. Larger trials are obligatory before it is recommended for clinical exercise in future, though it carries immense prospective to be developed as drug for pharmaceutical diligence.

## ACKNOWLEDGEMENT

Author is grateful to University of Mumbai for granting funds to accomplish this project. Thanks are also due to SVKM Management and Principal of Mithibai College for their encouragement and support.

## REFERENCES

1. Avadhoot, Y. and Rana, A.C. Hepatoprotective activity of *Vitex negundo* against Carbon tetrachloride induced liver damage, *Arch. Pharm. Res.* 14 (1) 1999: 96-98.
2. Beasley, S.W., Diez Pardo, J. Qi B.Q., Tovar, J.A. and Xia, H.M. The contribution of the Adriamycin-induced rat model of the VATER association to our understanding of congenital abnormalities and their embryogenesis. *Pediatr. Surg. Int.* (16) 2000: 465-472.
3. Bergmeyer H.U. and Bernt E. Methods of enzymatic Analysis (Ed. Bergmeyer) Vol. 2, 1974: 735.
4. Chandrakar, M., Raipure, R., Manwar, N. and Chandrakar, S. Effect of ethanol on glucose, protein, cholesterol and calcium level in the amniotic fluid of chick embryo. *The Bioscan.* 5 (2) 2010: 189-191.
5. Dharmasiri, M.G., Jayakody, J.R., Galhena, G., Liyanage, S.S. and

- Ratnasooriya, W.D. Anti-inflammatory and analgesic activities of mature fresh leaves of *Vitex negundo*. *J. Ethnopharmacol.* 87 (2-3) 2003: 199-206.
6. Farvin, K.H.S., Anandan, R., Kumar, S.H., Shiny, K.S., Sankar, T.V. and Thankappan, T.K. Effect of squalene on tissue defense system in isoproterenol-induced myocardial infarction in rats. *Pharmacol. Res.* 50, 2004: 231-236.
  7. Gupta, R.K. and Tandon, V.R. Antineoplastic activity of *Vitex-negundo* Linn. leaf extract. *Indian J. Physiol. Pharmacol.* 49 (2) 2005: 163-70.
  8. Gulienetti, R., Kalker, H. and Davis, N.C. *Bio. Neonat.* 4, 1962: 300-309.
  9. Gurr E. A Practical Manual of medical and biological staining techniques. Leonard Hill (books) Ltd. 1956.
  10. King, J. *Biochem J.* 26, 1932: 296.
  11. King, J. Practical Clinical Enzymology, (Princeton M. J. Ed.), Van D. Wost and Company, London. 1965a: 264-5.
  12. King, J. Practical Clinical Enzymology, (Princeton M. J. Ed.), Van D. Wost and Company, London. 1965b: 363.
  13. Loannides, A.S., Chaudhry, B., Henderson, D.J., Spitz, L. and Copp, A.J. Dorsoventral patterning in oesophageal atresia with tracheo-oesophageal fistula: Evidence from a new mouse model. *J. Pediatr. Surg.* 37 (2) 2002: 185-191.
  14. Mortell, A., Giles, J., Bannigan, J. and Puri, P. Adriamycin effects on the chick embryo. *Pediatr. Surg. Int.* 19 (5) 2003: 359-364.
  15. Matalon, S.T., Ornoy, A. and Lishner, M. Review of the potential effects of three commonly used antineoplastic and immunosuppressive drugs (cyclophosphamide, Azathioprine, doxorubicin on the embryo and placenta). *Repr. Toxicol.* 18, 2004: 219-230.
  16. Perumalsamy, R., Ignacimuthu, S. and Sen, A. Screening of 34 Indian medicinal plants for antibacterial properties. *J. Ethnopharmacol.* 62 (2) 1998: 173-182.
  17. Plaa, G. and Hewitt, W. Quantitative evaluation of induced hepatotoxicity. In: Toxicology of liver (Zakin D. and Boyer J. D., eds.), Raven Press, New York. 1982: 103-110.
  18. Sathiamoorthy, B., Gupta, P., Kumar, M., Chaturvedi, A.K., Shukla, P.K. and Maurya, R. New antifungal flavonoid glycoside from *Vitex negundo*. *Bioorg. Med. Chem. Lett.* 17 (1) 2007: 239-242.
  19. Schrott, L.M., Sweeney, W., Bodensteiner, K. and Sparber, S.B. *Pharmacol. Biochem. Behav.* 64, 1999: 81-89.
  20. Surai, P.F. *Br. Puol. Sc.* 40, 1999: 397-405.
  21. Shingadia H.U. and Dalvie V.V. Embryo protective effect of leaf extract of *Vitex negundo* Linn. in Adriamycin induced toxicity. *Int. J. Med. Sc. Clin. Res.* 2 (4) 2014: 730-740.
  22. Vargas, A., Zeisser-Labouebe, M., Lange, N., Guny, R. and Delie, F. The chick embryo and its chorio-allantoic membrane (CAM) for the in-vivo evaluation of drug delivery system. *Adv. Drug Delivery Reviews.* 59, 2007: 1162-1176.
  23. Vidal, A., Fallarero, A., Pena, B.R., Medina, M.E., Gra, B., Rivera, F., Gutierrez, Y. and Vuorela, P.M. *J. Ethnopharmacol.* 89, 2003: 295-300.

**Table 1.** Experimental protocol

Experimental Groups	Dosage
Group 1	Control (Normal saline)
Group 2	Adriamycin (70 µg/egg)
Group 3	Extract control (200 µg of extract/egg)
Group 4	Dose 1 - Six hours prior to administration of ADR (100 µg of extract/egg) + Adriamycin (70 µg/egg)
Group 5	Dose 2 - Six hours prior to administration of ADR (200 µg of extract/egg) + Adriamycin (70 µg/egg)

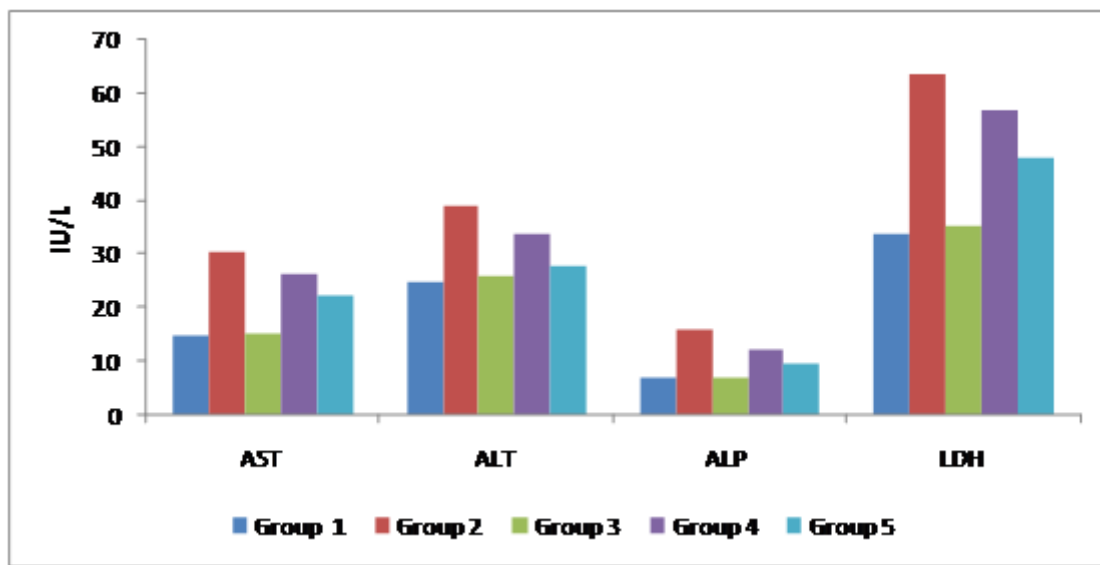
**Table 2.** Weight of 12 days old chick embryo and volume of amniotic fluid after 48 hrs. of Adriamycin treatment (n=6 mean ± SE \*\*P≤0.01, \*P≤0.05)

Parameters	Exposure period	Group 1 (Control)	Group 2 (ADR 50µg)	Group 3 (ADR 60µg)	Group 4 (ADR70µg)
Weight of embryo (G/egg wt.)	48 hrs.	9.28±0.08	8.72±0.03**	7.32±0.04**	6.65±0.11*
Volume of amniotic fluid (mL/embryo)	48 hrs.	5.5±0.15	4.9±0.20*	3.3± 0.12*	3.95±0.09**

**Table 3.** Concentration of marker enzymes in amniotic fluid after 48 hrs. of Adriamycin treatment (n=6 mean ± SE \*\*P≤0.01, \*P≤0.05)

Groups	AST (IU/L)	ALT (IU/L)	ALP (IU/L)	LDH (IU/L)
Group 1 (Control)	14.75 ± 0.08	25.06 ± 0.21	6.94 ± 0.04	33.91 ± 0.13
Group 2 (ADR 70µg)	30.47 ± 0.09	39.14 ± 0.28	15.9 ± 0.12	63.76 ± 0.08
Group 3 (LE 200µg)	15.08 ± 0.05	26.17 ± 0.16	7.12 ± 0.03	35.45 ± 0.26
Group 4 (LE 100µg + ADR 70µg)	26.28 ± 0.17**	33.87 ± 0.05**	12.27 ± 0.22*	57.04 ± 0.05**
Group 5 (LE 200µg + ADR 70µg)	22.45 ± 0.19*	27.8 ± 0.08*	9.51 ± 0.06**	48.16 ± 0.11*

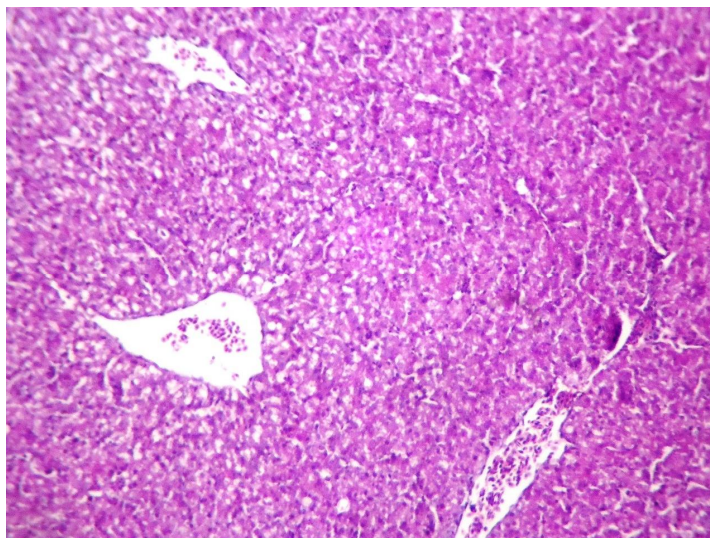




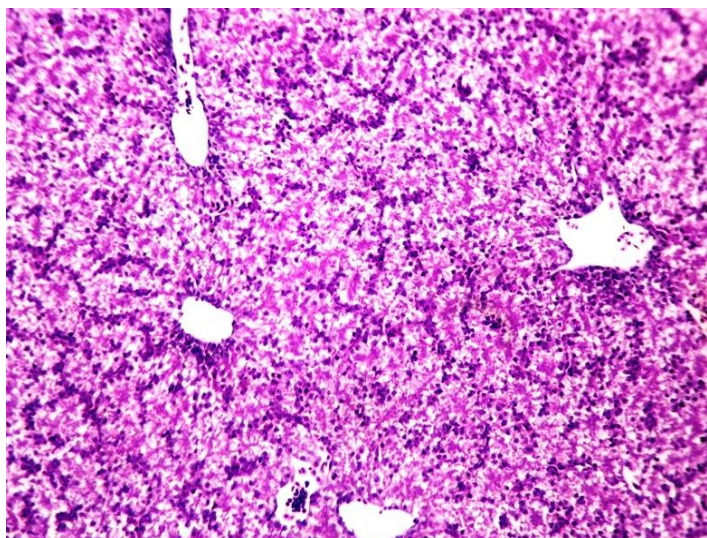
**Figure 1.** Concentration of marker enzymes in amniotic fluid after 48 hrs. of Adriamycin treatment (n=6 mean  $\pm$  SE \*\*P $\leq$ 0.01, \*P $\leq$ 0.05)



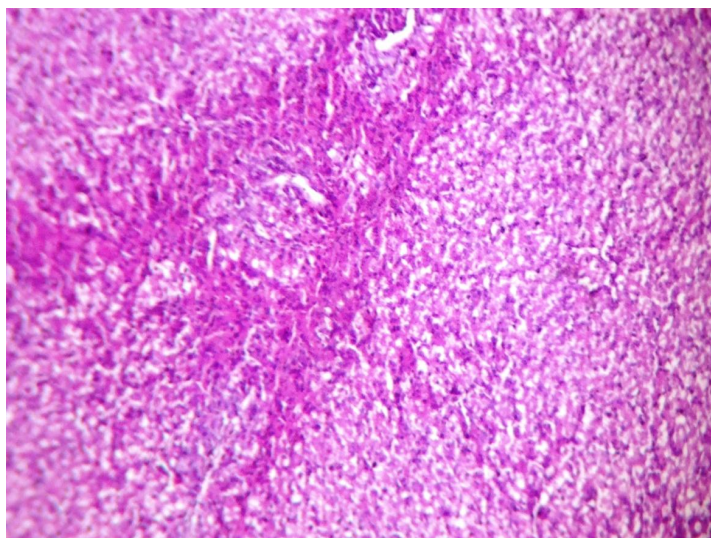
**Figure 2.** *Vitex negundo* Linn. Leaves used in preparation of alcoholic herbal extract



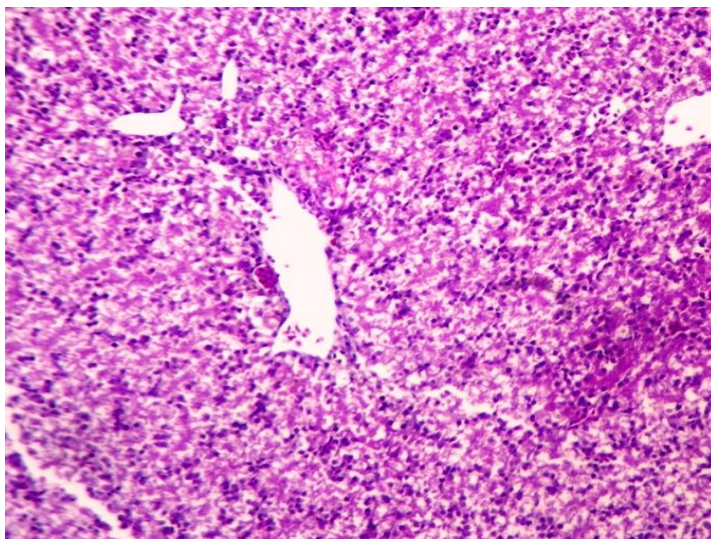
**Figure 3.** Photomicrograph of Liver from Grp. 1 showing normal architecture of tissue. (HEx200)



**Figure 4.** Photomicrograph of Liver from Grp.2 showing mononuclear / lymphocyte infiltration, vacuolation and derangement of hepatic cords. (HEx200)

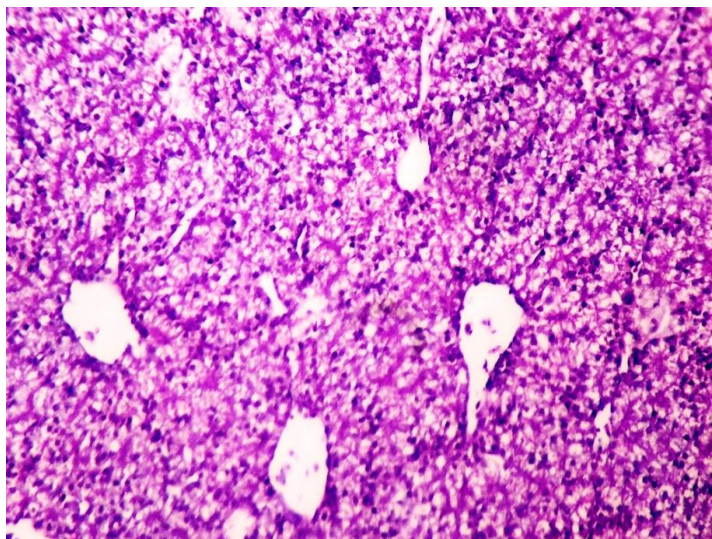


**Figure 5.** Photomicrograph of Liver from Grp.3 showing normal hepatic parenchyma with focal minimal changes in hepatocytes. (HEx200)



**Figure 6.** Photomicrograph of Liver from Grp.4 showing mild degree of degenerative changes in hepatocytes. (HEx200)





**Figure 7.** Photomicrograph of Liver from Grp. 5 showing no degenerative changes in the liver tissue. (HEx200)