

## Bilateral Hyphaemas Post Airbag-Deployment: A Case Report

Devangna Bhatia,  
Poonam Sharma,  
Lyudmila Kishikova and  
Partha Chakraborty\*

Department of Ophthalmology, Darlington Memorial Hospital, Hollyhurst Road, Darlington, UK

\*Corresponding author: Partha Chakraborty

✉ pchakraborty@nhs.net

Department of Ophthalmology, Darlington Memorial Hospital, Hollyhurst Road, Darlington, DL3 6HX, UK.

Tel: +441325743697

**Citation:** Bhatia D, Sharma P, Kishikova L, Chakraborty P (2017) Bilateral Hyphaemas Post Airbag-Deployment: A Case Report. *Ins Ophthalmol*. Vol. 1 No. 3:12

### Abstract

Airbags were first patented in 1951. It was not until the 1990s that they were featured in most cars in Europe. The main purpose of airbags is to increase the surface area of contact during a RTA thereby spreading the force of the impact and thus reducing overall injury, yet they are still linked to ocular injuries and poor visual outcomes.

Prospective follow-up over 4 months of Mrs. J, a 70 year old female who was brought into the Accident and Emergency Department following a road traffic accident with minor facial injuries, non-perforating ocular injuries presenting as bilateral hyphaemas with reduced visual acuity in both eyes – HM in the right eye and PL in the left eye and secondary raised IOPs. During admission she had daily ocular examinations, VAs and IOP measurements, slit-lamp photographs, B-scans and received medical treatment.

During the follow up period, VAs improved from hand movements in the right eye and perception of light in the left eye to 6/9 PH both eyes. IOPs reduced significantly from 26/40 mm Hg to 10/10 mm Hg. The hyphaemas completely resolved and there was no vitreoretinal pathology.

**Keywords:** Airbags; Hyphaemas; Ophthalmology

**Abbreviations:** A&E: Accident and Emergency; BE: Both Eyes; HM: Hand Movements; IOP: Intraocular Pressure; LE: Left Eye; PH: Pinhole; PL: Perception of Light; RE: Right Eye; RTA: Road Traffic Accident; VA: Visual Acuity; VR: Vitreoretinal

**Received:** June 29, 2017; **Accepted:** September 20, 2017; **Published:** September 27, 2017

### Background

Airbags have been used widely in the developed world for over 30 years and significantly reduce fatalities and serious injuries but are often linked to ocular trauma. Airbags are designed to inflate rapidly and then deflate almost as quickly. This requires a huge amount of pressure and heat, which is generated by an exothermic chemical reaction. This can lead to burns and chemical injuries to the face and eyes. Mechanical injuries occur as well, through the sheer force of the impact. These can lead to traumatic cataracts and globe ruptures.

They form a protective cushion in between the occupant and the vehicle interior and in doing so they absorb the majority of the impact of the collision. In the UK airbags are specifically designed for seatbelt-restrained occupants, unlike their USA counterparts

which are designed to protect unrestrained occupants and are therefore larger thereby causing more airbag-related injuries.

Cases of bilateral homogenous ocular injuries with minimal facial or any other injuries following airbag deployment are uncommon. This case highlights the importance of revisiting airbag safety regulations and improving public awareness surrounding airbag safety, specifically correct seat positioning.

### Case Presentation

Mrs. J, a 70 year old Caucasian female was the front-seat passenger in a car, which her husband was driving the car at a speed of 65-80 km/h. The car swerved and hit another vehicle, with the majority of the impact on the driver's side. The driver and passenger airbags were deployed. Even though, she was restrained by a three-point seatbelt, Mrs. J was struck in the face

which caused her to develop immediate vision loss in both eyes; she was not wearing any spectacles.

On presentation to A&E she was found to have bilateral hyphaemas as well as extensive bruising to the face and minor seatbelt injuries to the chest wall. She also sustained a fracture to the base of the left ring finger. There were no significant findings on the whole body CT scan.

She was admitted for head injury and neurological observations and referred to Ophthalmology. Visual acuity was reduced in both eyes to hand movements on the right and perception of light on the left. We were unable to visualise the fundus on initial presentation.

### Case History

Initially hyphaemas measured 2.8 mm in RE and 3.5 mm in LE (Figure 1). IOPs were 26/40 mm Hg and B-scan showed flat retinae. Initial treatment included acetazolamide and topical hypotensive and mydriatic agents. Topical steroids were added at subsequent visits.

Mrs. J had the following examinations performed regularly during admission: VAs; IOPs; hyphaema measurements; B-scans and slit lamp photography. There was no evidence of traumatic cataract or any vitreoretinal pathology.

She remained an inpatient for 15 days, during which time the VAs, IOPs and hyphaemas improved. The hyphaemas had completely resolved at 3 months post-injury and IOPs had normalised therefore her topical medications were reduced and oral acetazolamide was stopped. One month later VAs were 6/9 PH both eyes and IOPs were 10/10 mm Hg. All eye drops were stopped and slit lamp photos were repeated (Figure 2). Follow up was booked for 6 months. Table 1 shows outcomes.

Table 1 Clinical outcomes.

Time frame	VA (PH)		IOP (mm Hg)	Hyphaema (mm)	
	RE	LE		RE	LE
Day 0	HM	PL	26/40	2.8	3.5
Day 15	6/18	6/24	26/24	2.0	2.0
Day 90	6/12	6/9	13/13	Resolved	Resolved
Day 120	6/9	6/9	10/10	Resolved	Resolved

Table 2 Ocular injuries sustained upon airbag deployment.

Ocular Injury Types	
Anterior segment injuries	Posterior segment injuries
Corneal Abrasion	Vitreous/retina haemorrhage
Hyphaema	Retinal tear/detachment
Eyelid laceration, burn, periorbital contusion	Comotio retinae
Iritis	Macular hole
Iris tear	Choroidal rupture
Cataract	Traumatic maculopathy
Angle recession	Optic disc oedema
Chemical keratitis	
Corneal/scleral laceration/globe rupture	
Lens dislocation/subluxated	
Orbital fracture	
Facial Nerve palsy	

### Discussion

Although airbags have been in use for a long time, there is a lack of public awareness regarding their safety. Airbags were first patented in 1951 but did not become commonplace until the 1990s [1]. They are designed to act as a cushioning device in order to prevent occupants making contact with the vehicle interior and to spread the force of the collision over a larger surface area [2,3].

In the USA, where seatbelt usage was very low, airbags were designed to protect unrestrained occupants, unlike their European counterparts, which were intended for use in conjunction with seatbelts [1,2]. Thus, American airbags have a larger volume and inflate faster [1,3]. Seatbelts became a mandatory addition in all new cars sold in the USA from 1998 onwards, but new vehicles still contain larger airbags [1]. In the UK, there is no specific legal requirement for cars to have airbags, though most new cars are fitted with frontal airbags [2].

Airbags do significantly reduce fatalities and severe injuries, but they can cause significant non-life-threatening injuries. Airbag-related injuries are more common in the USA due to the larger volume and faster inflation rate of American airbags. As seen in this report, airbag deployment can cause ocular injuries resulting in temporary visual loss. Other authors have also reported cases of ocular injuries, sometimes bilateral. Examples of ocular injuries caused by airbags can be seen in Table 2 below [4-12].

### Conclusion

Airbags have undoubtedly prevented many fatalities due to road-traffic accidents, but they are not without their own dangers.

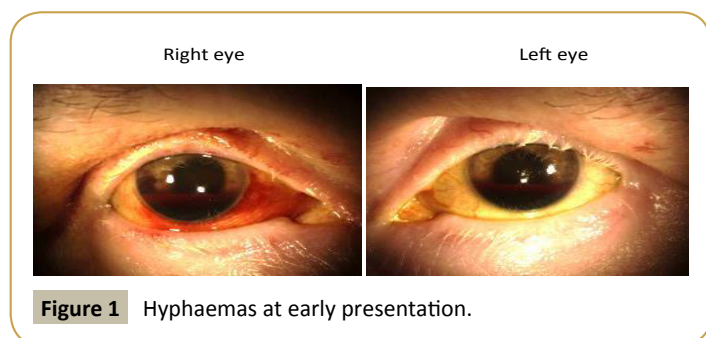


Figure 1 Hyphaemas at early presentation.

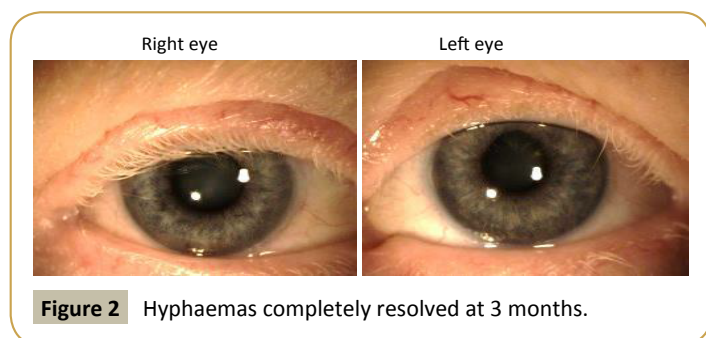


Figure 2 Hyphaemas completely resolved at 3 months.

They function best when used in conjunction with a three-point seatbelt. The Department of Transport has an 'Information Sheet' on airbag usage and its safety. A summary of these points is listed below and they should be taken into account for all automobile passengers [2]:

- Seatbelts should always be worn and are safer than airbags.
- Drivers should sit as far back as possible from the steering wheel; passengers should sit upright and as far back as possible from the dashboard.

- If you need to sit close to the wheel, recline the back of your seat slightly.
- If the steering wheel is adjustable, ensure it tilts downwards.
- Raise the height of the seat if possible.
- Never put your feet on the dashboard.
- Never fit a rear facing child restraint in the passenger seat.
- Children are generally safer when restrained in the rear seats.

## References

- 1 Wallis LA, Greaves I (2002) Injuries associated with airbag deployment. *J Emerg Med* 19: 490-493.
- 2 Taru M (2011) Airbags – General advice.
- 3 RoSPA (2017) Seat Belts and Airbags.
- 4 Pearlman JA, Au Eong KG, Kuhn F, Pieramici DJ (2001) Airbags and eye injuries: epidemiology, spectrum of injury and analysis of risk factors. *Surv Ophthalmol* 46: 234-242.
- 5 Stein JD, Jaeger EA, Jeffers JB (1999) Air bags and ocular injuries. *Trans Am Ophthalmol Soc* 97: 56-59.
- 6 Lee WB, O'Halloran HS, Pearson PA, Sen HA, Reddy SH (2001) Airbags and bilateral eye injury: Five case reports and a review of the literature. *J Emerg Med* 20: 129-134.
- 7 Lim MS, Stavrou P (2001) Severe ocular injury associated with airbag inflation. *Eye* 15: 805-806.
- 8 Duma SM, Jernigan MV, Stitzel JD, Herring IP, Crowley JS, et al. (2002) The effect of frontal air bags on eye injury patterns in automobile crashes. *Arch ophthalmol* 120: 1517-1522.
- 9 Duma SM, Rath AL, Jernigan MV, Stitzel JD, Herring IP (2005) The effects of depowered airbags on eye injuries in frontal automobile crashes. *Am J Emerg Med* 23: 13-19.
- 10 Alquraini TA, Aggour MA, Zamzam AM (2011) Airbag induced facial and bilateral ocular injuries in a 14 years old child. *Saudi J Ophthalmol* 25: 421-425.
- 11 Onakoya AO, Mbadugha CA, Aribaba OT (2015) Airbag related ocular injuries: A short case series. *Niger J Ophthalmol* 23: 24-26.
- 12 Duma SM, Jernigan MV, Stitzel J, Herring IP (2015) Eye injury incidence and mechanisms in frontal automobile crashes, p: 82.