

# Obturing Materials Used for Pulpectomy in Primary Teeth- A Review

Srinitya RajaSekhar\*, Sreekanth Kumar Mallineni and Sivakumar Nuvvula

Department of Paedodontics and Preventive Dentistry, Narayana Dental College and Hospital, Nellore, Andhra Pradesh, India

**\*Corresponding author:** Srinitya Raja Sekhar, Department of Paedodontics and Preventive Dentistry, Narayana Dental College and Hospital, Nellore, Andhra Pradesh, India, Tel: +919492810592; E-mail: srinitya.r@gmail.com

**Rec date:** February 20, 2018; **Acc date:** February 24, 2018; **Pub date:** March 2, 2018

**Citation:** Rajsheker S, Mallineni SK, Nuvvula S (2018) Obturing Materials Used for Pulpectomy in Primary Teeth- A Mini Review. J Dent Craniofac Res Vol.3 No.1: 3.

## Abstract

Pulpectomy of primary teeth is indicated when the radicular pulp tissue is necrotic. It should be maintained in the dental arch to maintain the arch integrity. Various obturating materials are reported with successful outcomes by various authors. Hence, the aim of this review is to present various obturating materials used in daily clinical practice from traditional to novel materials, along with their antibacterial properties, toxicity and biocompatibility.

**Keywords:** Children; Obturating materials; Primary teeth; Pulpectomy

resorbable paste. Zinc oxide eugenol is most widely used obturating material; nonetheless, it has few drawbacks, such as, delayed resorption if extruded from the apex and concerns of toxicity. So, to overcome these, many obturating materials such as, calcium hydroxide and iodoform combinations (Metapex, Vitapex), endoflas and herbal derivatives have been introduced with promising results that can be used as alternatives to traditional ZOE. Hence, the aim of this review is to discuss various obturating materials that are available and used in daily clinical practice.

## Literature Review

For this work, a systematic bibliographic search was performed using the research gates PubMed and Research Gate, without time or language limitations and books as a complement.

The search was performed using the following words: pulpectomy, children, obturating materials, Zinc oxide eugenol, calcium hydroxide, iodoform, walkoff paste, gudes pinto paste, endodlas, metapex, vitapex, Lesion sterilization and tissue repair (LSTR), lesion sterilization and tissue repair, pulpote, toxicity.

## The optimal requirements of a root-filling material for primary teeth were listed by several authors

Rabinowitch stated, "The history of the treatment of root canals is the discussion of medications used. [4]"

- It should not irritate the periapical tissues, nor coagulate any organic remnants in the canal.
- It should have a stable disinfecting power.
- Excess pressed beyond the apex should be resorbed easily.
- It should be inserted easily into the root canal and removed easily if necessary.
- It should adhere to the walls of the canal and should not shrink.
- It should not be soluble in water.
- It should not discolor the tooth.

## Introduction

Infected teeth should be treated and maintained in the dental arch as natural space maintainer, provided they can be restored to function and remain free from the disease [1]. Root canal therapy was advocated as early as 1932, as a method for retaining primary teeth which would otherwise be lost [2]. Primary teeth with pulp necrosis are of polymicrobial in nature with predominance of anaerobic bacteria residing deeply with in the dentin and in cementum around the periapex. These microorganisms in the fins and isthmus can remain even after biomechanical preparation, thorough debridement with antibacterial irrigating agents and intracanal dressing. Owing to the task of complete debridement related to the canal morphology and close presence of succedaneous tooth, the obturating material should be biocompatible and eliminate these residual pathogens. It should neutralize their toxic products and prevent the canal reinfection to create favorable environment for the healing process to occur [3].

The introduction of formaldehyde into endodontic therapy with Gysis triopaste, supporting the concept of fixing the pulp and leaving it sterile allowed possibility of pulp treatment in the primary teeth. However, it was Buckley in 1904, which used formaldehyde to treat pulp necrosis by introducing a formula containing 40% formaldehyde tricresol and glycerine. After Buckleys use of formaldehyde, pulp tissue removal was performed by root canal instrumentation and filling with

- It should be radiopaque.
- It should induce vital periapical tissue to seal the canal with calcified or connective tissue.
- It should be harmless to the adjacent tooth germ.
- It should not set to a hard mass, which could deflect an erupting succedaneous tooth.

Till date, a number of investigators have tested different materials but none of the obturating materials have been shown to possess the requisite properties of an ideal root canal filling material for primary teeth, especially with regard to the major desirable property of having a rate of resorption

matching that of the physiologic root resorption of the primary teeth.

### Zinc oxide eugenol (ZOE)

Zinc oxide eugenol was discovered by Bonastre and subsequently used in dentistry by Chisholm. It was the first root canal filling material to be recommended for primary teeth, as described by Sweet in 1930. Studies by various authors and their observations on ZOE and its combinations with other materials are shown in **Tables 1 and 2** respectively [5-26].

**Table 1** Shows authors and their observations for zinc oxide eugenol.

Authors	Observations
Allen [8]	Speculated that the resorption rate of zinc oxide eugenol (ZOE) and the root differed, resulting in small areas of ZOE paste possibly being retained
Barker and Lockett [6]	Material when extruded from the apex cause a mild foreign body reaction
Barker and Lockett [6] Spedding [11] Mortazavi and Mesbahi [2]	Stated that extruded ZOE resisted resorption and took months or even years to resorb
Coll and Sadrian [17]	Pulpectomized teeth rarely exfoliate later than normal and timing of exfoliation was not related to retention of ZOE paste. Anterior cross-bite, palatal eruption, and ectopic eruption of the succedaneous tooth following ZOE pulpectomy.
Coll et al. [15]	Reported that when ZOE extrudes, it develops a fibrous capsule that prevents resorption of the material. Thus, it has a slow rate of resorption and has a tendency to be retained even after tooth exfoliation. Areas of cementum resorption were evident, periodontal ligament exhibited intense and moderate thickening. Dentin resorption was not observed, whereas bone resorption was found.
Cox et al. [7]	Zinc oxide powder had no inhibitory effect and the addition of eugenol to zinc oxide retarded the growth of only the gram-positive organisms. The inclusion of zinc acetate as a setting accelerator inhibited both gram-positive and gram-negative bacteria.
Erasquin et al. [5]	Reported that the canals overfilled with (ZOE) are not recommended because it irritates the periapical tissues and causes necrosis of bone and cementum.
Flaitz et al. [16] Coll and Sadrian [17]	Observed deflection of permanent tooth eruption in 20% of pulpectomized tooth that were extracted
Garcia-Godoy [12], Ranly and Garcia-Godoy [13], Praveen et al. [14]	Reported deflection of developing permanent tooth bud because of its hardness
Hashieh et al. [20]	Studied the beneficial effects of eugenol. The amount of eugenol released in the periapical zone immediately after placement was 10 <sup>-4</sup> and falls to 10 <sup>-6</sup> after 24 hours, reaching zero after one month. Within these concentrations eugenol is said to have anti inflammatory and analgesic properties that are very useful after a pulpectomy procedure
Holan and Fuks [4]; Moskovitz and Samara [10]	Malformation of successor is attributed to the cytotoxic and neurotoxic nature of eugenol
Jerrell and Ronk [9]	Reported a case of developmental arrest of a premolar following overfilling of the root canal of the second primary molar using zinc oxide-eugenol/formocresol paste
Loevy [18]	Premolars erupt early after primary teeth pulpotomies. Possibly a mild chronic inflammation exists in periapical area of some pulpectomies judged successful that is not clinically evident. This could cause premature eruption of succedaneous tooth and uneven resorption of pulpectomy treated tooth.
Praveen et al. [14]; Sunitha et al. [21]	Excess material forced through the apex during filling procedures can remain in the apical tissue during the process of physiological root resorption and it takes few months or even years to resorb

Sadrian and Coll [19]	Demonstrated that none of the retained ZOE particles caused any observable pathology and were also not related to treatment failure
-----------------------	---

**Table 2** Shows zinc oxide combinations with other materials.

Combination	Author	Observation
Zinc oxide + Propolis (ZOP)	Al-Ostwani et al. [26]	ZOP paste was synthesized by mixing 50% zinc oxide powder with 50% hydrolytic propolis. There was acceptable clinical and radiographic success rate with faster resorption seen in some cases.
Zinc oxide + Ozonated oil	Chandra et al. [25]	It has biological properties such as, bactericidal action, debriding effect, angiogenesis stimulation capacity and high oxidizing power (Guinesi et al., 2011). After 12 months followup there was progressive bone regeneration at the periapical region with good clinical and radiographic success rate.
Zinc oxide eugenol (ZOE)+ Calcium hydroxide (CA(OH) <sub>2</sub> ) +Sodium fluoride	Chawla et al. [23]	Ca(OH) <sub>2</sub> - demerit of resorbing at a faster rate than the physiologic root resorption. To overcome this filling material incorporated with fluoride was utilized. The addition of fluoride was seen to give this material a resorption rate that matched the resorption rate of primary teeth.
Iodoformized ZOE	Garcia-Godoy [12]	It was found to be effective for both aerobic and anaerobic bacteria with a maximum sustaining period of 10 days.
Zinc oxide + Calen paste	Pinto et al. [24]	Clinical and radiographic outcomes for calen/zo were equal to ZOE after 18 months, suggesting that both the materials can be indicated for obturation of primary teeth
Zinc oxide + Calcium hydroxide	Praveen et al. [14]	Obtured material remained up to the apex of root canals till the beginning of physiologic root resorption and was found to resorb at the same rate as that of primary teeth
Zinc oxide eugenol + Aldehydes	Praveen et al. [14]; Chawla et al. [22]	The addition of these compounds neither increased the success rate nor made the material more resorbable as compared to zinc oxide eugenol alone

## Enamel defects of succedaneous teeth following ZOE pulpectomies

Coll and Sadrian [17], stated that there is no relationship between primary teeth pulpectomy and enamel hypoplasia. Incidence of enamel defects was not related to the retention of ZOE filler, length of ZOE fill, or history of trauma or caries.

Contrary to these results, Holan [14], reported that, succedaneous incisors that replace traumatized primary incisors treated with ZOE pulpectomies have 2-3 times higher incidence of enamel defects when compared to normal teeth.

## Calcium hydroxide

Calcium hydroxide was introduced by Herman. The main drawback of the material is that despite of its antiseptic and osteoconductive properties, it has the tendency to get depleted from the canals earlier than the physiologic root resorption. Antibacterial effect is primarily due to the liberation of hydroxyl ions and inactivation of enzymes in the bacterial cytoplasmic membrane [27].

## Calcium hydroxide when used as obturating material in hyperaemic pulp

Ca(OH)<sub>2</sub> containing root canal filling materials when used in primary teeth with hyperemic pulp can come in contact with some vital pulp tissue remnants and can trigger the cascade of inflammatory root resorption [28].

## Calcium hydroxide when used as obturating material in necrotic pulp

Ca(OH)<sub>2</sub> paste produces superficial layer of necrosis causing damage to predentine, which in turn can lead to exposure of dentine to odontoclasts and subsequent resorption [29].

## Iodoform

Castagnola and Orlay [30] showed that iodoform pastes are bactericidal to microorganisms in the root canal and lose only 20% of their potency over a period of 10 years. Iodoform because of the presence of iodine causes yellowish discoloration of the tooth that may compromise the esthetics [31]. Few studies have revealed that it is irritating to periapical tissues and can cause cemental necrosis [5]. It is commercially available as walkoff's paste, maisto's paste and Guedes pinto paste.

**Kri-1:** In 1989, a procedure was published for root canal preparation and filling in necrotic primary molars with a paste made of Kri-1 and pure calcium hydroxide obtaining a high percentage of success with remission of all symptoms. This was the first publication in which formaldehyde was mentioned as a component of root canal filling material, thus partly recovering Buckley's formula, which contained 40% formaldehyde and glycerine [32].

**KRI-3:** This liquid differs from commonly used Kri 1 paste in that, its para-chlorophenol, camphor and menthol concentration are twelve times superior and hence possess greater antimicrobial properties [12].

## Concerns of formaldehyde constituent in these materials

Formaldehyde, like other aldehydes, quickly binds to organic substance, thus originating albumin-formaldehyde with high permeability and penetration capacity. It is metabolized in acid form, carbon dioxide and amino acid radicals, and its biodegradation primarily occurs at the hepatic level and to a lower degree, at the pulmonary and renal levels [33]. When metabolized, part of the drug fixes on different body tissues (mainly liver and kidney), although only 1% of the dose applied on each tooth is usually absorbed. Thus, a diluted formaldehyde formulation has been recommended [34]. Another side effect of formalin-cresol is its antigenic potential and, even though it is not considered toxic at low exposure levels, the literature contains cases of hemocromatosis, dermatitis and pulmonary pathology (asthma) in workers of paper, cosmetic and wood-derivative industries [35].

## Maisto's paste

It differs from Kri paste in that; it also contains zinc oxide, thymol and lanolin. This formulation change was made with the intention of reducing the resorption rate of paste from within the canals of primary teeth [36].

## Guedes pinto paste

Composition is shown in **Figure 1**.

**Table 1.** Components of Guedes-Pinto Paste proposed in 1981.

GPP Components	Composition (per gram)	Physical Aspect	Property
Rifocort ® Merrel Leppetit	* prednisolone acetate (corticosteroid), (5mg) – anti-inflammatory * rifamycin sodium salt - antibiotic * propylenglycol - vehicle * macrogol (polyethylene-glycol) - vehicle	ointment	Anti-inflammatory Antibiotic
Camphorated parachlorophenol (Biodinâmica)	(proportion 3:7) * 30% parachlorophenol * 70% camphor	liquid	Antimicrobial Analgesic
Iodoform (K-Dent)	* iodine	powder	Antimicrobial

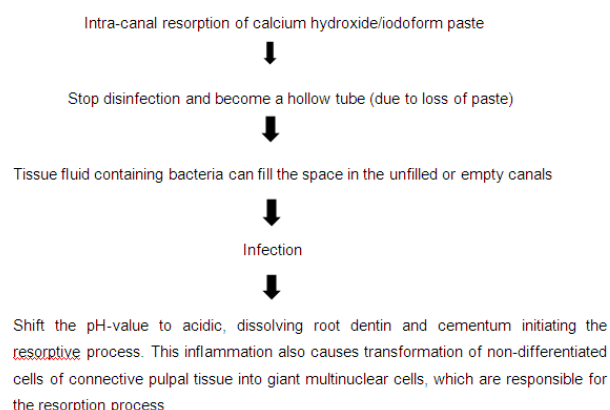
**Figure 1** Components of Guedes Pinto paste.

## Calcium hydroxide combinations

Metapex (METABIOMED) and Vitapex (Neo Dental Chemical Products Co., Ltd, Tokyo, Japan) are available in preformed syringes, which is directly placed into the canals and the material is extruded by simple pressure. Addition of polysiloxane oil in Vitapex, enhances fluidity and permeability, which also improves the collateral benefit of root canal filling [37]. The fast resorption of metapex and vitapex, causes voids in the canal leading to formation of hollow tube [26].

The formation of hollow tube effect is shown in **Figure 2**.

### Hollow tube effect (Goldman and Pearson 1965)<sup>28</sup>:



**Figure 2** Hollow tube effect reported by Goldman and Pearson [38].

## Prevention of intra radicular resorption there by preventing hollow tube effect

Mortazavi and Mesbahi [2] who treated children in two visits, performed formocresol pulpotomy on the first visit and then preparation and obturation of the canals in the second visit. It is possible that foreign body giant cells may have been chemically fixed, thus losing their ability to resorb the vitapex paste in the root canals.

## Endoflas

The rationale behind incorporating three materials ZOE, Ca(OH)<sub>2</sub> and iodoform into Endoflas was probably to compensate the disadvantages of one individual material with the advantages of the other. Endoflas has the advantage of having the resorption limited to excess material, which has been extruded periapically within 7 days [39,40]. Resorption of material does not occur within the canal. Thus, the material is neither resistant to resorption nor does it result in hollow tube effect.

## Endoflas-chlorophenol-free (CF)

Radiolucent lesions following endodontic treatment of primary teeth were, may be due to the filling material that contain phenol. Due to this endoflas cf was developed which is free of chlorophenol. Chlorophenol was eliminated from endoflas composition because it has fixation effect which may affect the osteoblast cells [26].

## Calen paste

Pinto [24] compared success rate of ZOE and calen paste thickened with zinc oxide. High success rate with calen/zo was seen as this material prevented pathologic root resorption and induced new bone formation. Addition of zo provides better consistency to the paste.

## Lesion sterilization and tissue repair (LSTR)

In recent years, Cariology Research Unit of Niigata University School of Dentistry has developed the concept of LSTR. The theory behind LSTR is that the repair of damaged tissue might occur if lesions are disinfected. This has also been referred to non-instrumentation endodontic treatment (NIET). The mix is also called as triple antibiotic paste/polyantibiotic paste, antibiotic mixture. It uses a mixture of 3 antibiotics. 1. Metronidazole 2. ciprofloxacin 3. minocycline.

The walls of access cavity were chemically cleaned with EDTA, a chelating agent, which is used to improve the chemo mechanical debridement because of its ability to remove smear layer and allowing antibiotics to penetrate into the dentinal tubules. Pulpal floor is covered with 3 mix-MP. The procedure which is termed as "medication cavity".

## Mechanism of action

The material can produce vascular changes in pulp, involving inflammation and formation of granulation tissue with accompanying metaplasia of the connective tissue and macrophages to form osteoclast like multinucleated giant odontoclasts. The remaining vital pulp cells proliferate and develop new pulp tissue into the coronal pulp chamber, so called pulp revascularization. Authors and their observations on LSTR procedure is shown in **Table 3**.

**Table 3** Showing authors and their observations on Lesion sterilization and tissue repair (LSTR) procedure.

Authors	Observations
Hoshino et al. [41]	Reported that, rifampicin the component of 4 mix causes discoloration of tooth
Pinky et al. [3]	Compared combination of two antibiotic pastes. metronidazole+ciprofloxacin +minocycline and ornidazole+ciprofloxacin +minocycline. They were mixed in the ratio of 1: 3: 3. One part ciprofloxacin, 3 parts metronidazole and minocycline. They concluded that ornidazole had longer duration of action, with better efficacy and slower metabolism compared to metronidazole.
Sato et al. [40]	Evaluated efficacy of 4 mix i.e., 3 Mix +rifampicin
Takushige et al. [42]	Preparation can be done in 2 ways: 3 mix sealer; 3 mix with MP
Trairatvorakul and Detsomboonrat [43]	3 mix cannot replace conventional root canal treatment

## Alternatives for metronidazole

Pinky et al [3] compared ornidazole with that of metronidazole. It has been reported that, ornidazole had longer duration of action, with better efficacy and slower metabolism compared to metronidazole, and hence better results with 100% success rate.

## Alternatives for minocycline

Minocycline causes pigmentation in calcifying teeth. Consequently, in place of this, drugs like amoxicillin, cefaclor, cefroxadine, fosfomycin, rokitamycin were tried.

## Pulpotec

Pulpotec has antiseptic, antibacterial and anti-inflammatory properties [44]. The main component of this product is iodoform, and due to its antiseptic properties, it acts like an antibiotic paste at the entry of the empty root canal. Pulpotec can be used in the teeth showing bone lesion and help in reduction of clinical signs of infection. The clinical and radiological results show that, this procedure could be considered as an alternative to the conventional endodontic treatment for necrotic primary teeth in paediatric dentistry [45].

## Aloe vera

Aloevera is an herbal and naturally found material and its properties made possible its wide usage in dentistry for various therapeutic properties. It enhances various phases of wound healing process, such as macrophage recruitment, collagen synthesis and wound contraction [46]. Khairwa et al [47] evaluated clinical and radiographic success of zinc oxide combined with aloe vera and showed good success rate. They reported that this material can be used as an alternative for zinc oxide eugenol.

## Ozone

Ozone is gaseous, energized form of oxygen, it is unstable and dissociates readily back into oxygen, thus liberating so called singlet oxygen, which is a strong oxidizing agent. They are responsible for remarkable bactericidal and fungicidal effects. In the study conducted by Chandra et al. [25] there was good clinical success rate at 12 months follow up, which was attributed to the antibacterial and excellent healing properties of ozone peroxides. There is also progressive bone regeneration observed at the follow ups. ZOE had radiographic success rate less than that of ozonated oil-ZOE. Accordingly, the authors have concluded that, it can be considered as a good alternative for ZOE.

## Antibacterial properties of various root canal filling materials

The endodontic infection in the primary teeth with pulp necrosis and apical periodontitis is of polymicrobial nature with predominance of anaerobic bacteria. Hence, endodontic filling materials should have antibacterial properties in order to create a favorable environment for the healing process to proceed [48-56]. The antimicrobial properties of ZOE, Ca(OH)<sub>2</sub>, metapex, vitapex and endoflas are shown in the **Tables 4-7** [57-59].

**Table 4** Showing antibacterial properties of calcium hydroxide reported by various authors.



Authors	Observations
Abdulkader et al. [54]	Calcium hydroxide associated with distilled water, saline, glycerine was ineffective against several obligatory and facultative anaerobic bacteria
Estrela et al. [55]	Verified influence of antibacterial potential of Ca(OH) <sub>2</sub> against <i>Staphylococcus aureus</i> , <i>Enterococci faecalis</i> , <i>Pseudomonas aeruginosa</i> , <i>Bacillus subtilis</i> , and <i>Candida albicans</i> and showed significant effectiveness for Ca(OH) <sub>2</sub> paste or iodoform plus saline

**Table 5** Showing antibacterial properties of Metapex reported by various authors.

Authors	Observations
Kriplani et al. [46]; Harini priya et al. [52]	Metapex has lowest antibacterial activity when compared to ZOE, Vitapex and Calcium hydroxide. However, it showed moderate activity against <i>Streptococcus pyogenes</i> , <i>Staphylococcus aureus</i> , <i>Enterococcus faecalis</i> , <i>Escherichia coli</i> and <i>Pseudomonas aeruginosa</i> but failed to inhibit <i>Candida albicans</i> . So, it was concluded from their study that ZOE>vitapex>Ca(OH) <sub>2</sub> >metapex.
Seow et al. [56]	The weak antimicrobial activity of metapex may be partially explained by the facts that calcium hydroxide, an ingredient of metapex has been demonstrated to interfere with the antiseptic capacity of dyadic combinations of endodontic medicaments
Tchaou et al. [50]	Calcium hydroxide with iodoform had exhibited no antimicrobial activity

**Table 6** Showing antibacterial properties of vitapex reported by various authors.

Authors	Observations
Kriplani et al. [46]; Harini priya et al. [52]	Metapex has lowest antibacterial activity when compared to ZOE, Vitapex and Calcium hydroxide. However, it showed moderate activity against <i>Streptococcus pyogenes</i> , <i>Staphylococcus aureus</i> , <i>Enterococcus faecalis</i> , <i>Escherichia coli</i> and <i>Pseudomonas aeruginosa</i> but failed to inhibit <i>Candida albicans</i> . So, it was concluded from their study that ZOE>vitapex>Ca(OH) <sub>2</sub> >metapex.
Seow et al. [56]	The weak antimicrobial activity of metapex may be partially explained by the facts that calcium hydroxide, an ingredient of metapex has been demonstrated to interfere with the antiseptic capacity of dyadic combinations of endodontic medicaments
Tchaou et al. [50]	Calcium hydroxide with iodoform had exhibited no antimicrobial activity

**Table 7** Showing antibacterial properties of Endoflas reported by various authors.

Authors	Observations
Hegde et al. [59]	Endoflas™ moderately inhibited the gram-negative and gram-positive organisms and showed strong inhibition of <i>Candida albicans</i>
Pelczar et al. [58]	The high antimicrobial activity of Endoflas™ was probably due to the presence of iodoform and eugenol, both of which have antibacterial action. Eugenol acts by protein denaturation, while iodoform is an oxidizing agent. Even after the material sets, surface hydrolysis of the chelate (zinc eugenolate) results in release of eugenol, thus

explaining the effective antibacterial activity of this substance even after 72 hours

## Mixture of zinc oxide powder calcium hydroxide in sodium fluoride

In the study conducted by Chawla [23] a mixture of zinc oxide powder and calcium hydroxide paste in sodium fluoride displayed moderate inhibitory activity against, *Staphylococcus epidermidis*, *Streptococcus mutans*, *Staphylococcus aureus* and *Bacillus subtilis* and other gram positive micro-organisms. It showed weak inhibition against *Enterococcus faecalis*. The improved efficacy of this mixture could be attributed to the addition of fluoride, whose antimicrobial effect is well established.

**Maisto paste:** Pabla [57] reported that, maisto paste had the best antimicrobial activity>idoform paste>ZOE>vitapex.

## Guedes pinto paste (GP)

Study by Praetzel [60] confirms that GP paste had a favorable antimicrobial action along with an exceptional diffusion capability against all the microorganisms. Antimicrobial action of GP occurred in decreasing order against: *Bacillus subtilis*, *Streptococcus oralis*, *Streptococcus mutans*, *Staphylococcus epidermis*, *Escherichia coli*, *Staphylococcus aureus* and *Enterococcus faecalis*.

## Calen paste

**Calen/zo paste:** In the study conducted by Queiroz [48] the zones of bacterial growth inhibition of calen paste thickened with ZO was slightly larger when compared to calen paste alone, except for, *Staphylococcus aureus*, suggesting that the addition of zo to thicken calen paste did not interfere in its antibacterial activity (this is due to zo also has antibacterial activity).

## Rifocort

It is a product formed from a corticosteroid and an antibiotic, presenting a great antimicrobial action and recommended for the treatment of primary teeth presenting with pulpal infectious processes. The paste also presented bactericidal action against most organisms except for *Enterococcus faecalis* and *Bacillus subtilis*.

## Toxicity and Biocompatibility

ZOE when combine with Formocresol increases its antibacterial efficacy but, Formocresol has been demonstrated to be toxic to pulp fibroblast and eugenol has been shown to be toxic to human submandibular gland carcinoma (HSG) cells [61]. Huang et al. [62] reported that root canal filling materials with strong antibacterial additions showed definitive cytotoxicity to U2OS cells. Contrary to the antibacterial effects, Vitapex and Ca(OH)<sub>2</sub> with iodoform paste showed good biocompatibility i.e. high survival rate of the U2OS cells but had low antibacterial effects. It was reported

that iodoform based tooth filling pastes caused considerable tissue necrosis and had a higher cytotoxicity than ZOE [63]. They concluded that, when primary root filling materials have strong antibacterial properties, the cytotoxicity is strong too.

## Discussion

The current obturating materials available though have marked success rates clinically and radiographically, none of the material can be considered as ideal root canal filling material. ZOE though has antibacterial properties better than other materials concerns are raised regarding its delayed resorption and toxicity which limits its use in current practice. To overcome the toxicity, aloe vera and ozonated oil was substituted for eugenol and the authors reported good clinical and radiographic success rates. Hence, these materials can be used as alternatives to traditional ZOE [25,47]. Ca(OH)<sub>2</sub> combinations were introduced with the idea of matching the resorption rate with that of primary teeth, but the major disadvantage with these materials was that it resorbed very much earlier than that of physiologic root resorption [26]. To overcome the above material disadvantages endoflas can be used which has the property of resorption of extruded material with no intracanal resorption [58]. With the advent of novel techniques and materials like LSTR and pulpotec, necrotic primary teeth can also be preserved there by maintaining the arch integrity [3].

## Conclusion

Zinc oxide ozonated oil and ZO added with aloe vera can be used as alternatives to ZOE. Endoflas can be recommended in daily practice as it has better antimicrobial property and resorption of only extruded materials. In case of necrotic primary teeth LSTR and pulpotec can be used to preserve the tooth. So, based on the observations from the present review, this knowledge can be applied to our daily clinical practice and more randomized clinical trials should be conducted in the field of obturation materials in the future with larger sample sizes, such as, studies comparing traditional materials with that of novel materials and herbal derivatives, with long term follow ups for sound evidence-based practice.

## References

- Asokan S, Sooriaprakas C, Raghu V, Bairavi R (2012) Volumetric analysis of root canal fillings in primary teeth using spiral computed tomography: an *in vitro* study. J Dent Child (Chic) 79: 46-48.
- Mortazavi M, Mesbahi M (2004) Comparison of zinc oxide and eugenol, and Vitapex for root canal treatment of necrotic primary teeth. Int J Paediatr Dent 14: 417-424.
- Pinky C, Shashibhushan KK, Subbareddy VV (2011) Endodontic treatment of necrosed primary teeth using two different combinations of antibacterial drugs: an *in vivo* study. J Indian Soc Pedod Prev Dent 29: 121-127.
- Holan G, Fuks AB (1993) A comparison of pulpectomies using ZOE and KRI paste in primary molars: a retrospective study. Pediatr Dent 15: 403-407.
- Erasquin J, Muruzabal M (1967) Root canal fillings with zinc oxide eugenol in the rat molar. Oral Surg Oral Med Oral Pathol 24: 547-558.
- Barker BCW, Lockett BC (1971) Endodontic experiments with resorbable paste. Australian Dental J 16: 364-373.
- Cox ST, Hembree JH, Knight JP (1978) The bactericidal potential of various endodontic materials for primary teeth. Oral Surg 45: 947-954.
- Allen KR (1979) Endodontic treatment of primary teeth. Aust Dent J 24: 347-51.
- Jerrell RG, Ronk SL (1982) Developmental arrest of a succedaneous tooth following pulpectomy in a primary tooth. J Pedod 6: 337-342.
- Moskovitz M, Samara E, Holan G (2005) Success rate of root canal treatment in primary molars. J Dent 33: 41-47.
- Spedding RH (1973) Root canal treatments for primary teeth. Dent Clin North Am 17: 105-124.
- Garcia-Godoy (1987) Evaluation of an iodoform paste in root canal therapy for infected primary teeth. J Dentistry Children 54: 30-34.
- Ranly DM, Garcia-Godoy F (1991) Reviewing pulp treatment for primary teeth. J Am Dent Assoc 122: 83-85.
- Praveen P, Anantharaj A, Karthik V, Pratibha R (2011) A review of the obturating material for primary teeth. SRM University Journal of Dental Science 1: 1-3.
- Coll JA, Josell SS, Carper TS (1985) Evaluation of one appointment formocresol pulpectomy technique for primary molars. Pediatr Dent 7: 123-129.
- Flaitz CM, Barr ES, Hicks MJ (1989) Radiographic evaluation of pulpal treatment for anterior primary teeth. ASDC J Dent Child 56: 182-185.
- Coll JA, Sadrian R (1996) Predicting pulpectomy success and its relation to exfoliation and succedaneous dentition. Pediatr Dent 18: 57-63.
- Loevy HT (1989) The effect of primary tooth extraction on the eruption of succedaneous premolars. J Am Dent Assoc 118: 715-718.
- Sadrian R, Coll JA (1993) A long-term followup on the retention rate of zinc oxide eugenol filler after primary tooth pulpectomy. Pediatr Dent 15: 249-253.
- Hashieh IA, Ponnemmel L, Camps J (1999) Concentration of Eugenol apically released from ZnO E based sealers. J Endod 22: 713-715.
- Sunitha B, Kiran KP, Puppala R, Kethineni B, Ravigna R et al. (2014). Resorption of extruded obturating material in primary teeth. Indian J Med Allied Sci 1: 64-67.
- Chawla HS, Mathur VP, Gauba K, Goyal A (2001) A mixture of calcium hydroxide paste and zinc oxide powder as a root canal filling material for primary teeth. J Indian Soc Pedod Prevent Dent 19: 107-109.
- Chawla HS, Setia S, Gupta N, Gauba K, Goyal A (2008) Evaluation of a mixture of zinc oxide, calcium hydroxide, and sodium fluoride as a new root canal filling material for primary teeth. J Indian Soc Pedod Prev Dent 26: 53-58.
- Pinto DN, de Sousa DL, Araujo RB, Moreira-Neto JJ (2011) Eighteen-month clinical and radiographic evaluation of two root

- canal filling materials in primary teeth with pulp necrosis secondary to trauma. *Dent Traumatol* 3: 221-224.
25. Chandra SP, Chandrasekhar R, Uloopi KS, Vinay C, Kumar NM (2014) Success of root fillings with zinc oxide-ozonated oil in primary molars: preliminary results. *Eur Arch Paediatr Dent* 15: 191-195.
  26. Al-Ostwani AO, Al-Monaqel BM, Al-Tinawi MK (2016) A clinical and radiographic study of four different root canal fillings in primary molars. *J Indian Soc Pedod Prev Dent* 34: 55-59.
  27. Estrela C, Sydney GB, Bammann LL, Felipe O Jr (1995) Mechanism of action of calcium and hydroxyl ions of calcium hydroxide on tissue and bacteria. *Braz Dent J* 6: 85-90.
  28. Nurko C, Garcia Godoy F (1999) Evaluation of a calcium hydroxide/iodoform paste (Vitapex) in root canal therapy for primary teeth. *J Clin Pediatr Dent* 23: 289-294.
  29. Ravi GA, Subramanyam RV (2012) Calcium hydroxide- Induced resorption of deciduous teeth: A possible explanation. *Dent Hypotheses* 3: 90-94.
  30. Castagnola L, Orlay HG (1952) Treatment of gangrene of the pulp by the Walkhoff method. *Br Dent J* 93: 93-102.
  31. Cerqueira DF, Mello-Moura AC, Santos EM, Guedes-Pinto AC (2008) Cytotoxicity, histopathological, microbiological and clinical aspects of an endodontic iodoform-based paste used in pediatric dentistry: A review. *J Clin Pediatr Dent* 32: 105-110.
  32. Domínguez A, Solano E (1989) Root canal treatment in necrotic primary molars. *J Pedodont* 14: 36-40.
  33. Bernstein RS, Stayner LT, Elliott LJ, Kimbrough R, Falk H, Blade L (1984) Inhalation exposure to formaldehyde: An overview of its toxicology, epidemiology, monitoring and control. *Am Ind Hyg Assoc J* 45: 778-785.
  34. Pashley EL, Myers DR, Pashley DH, Whitford EM (1980) Systemic distribution of <sup>14</sup>C-formaldehyde from formocresol-treated sites. *J Dent Res* 59: 602-608.
  35. Anerback C, Montschen-Dahuner M, Montschen M (1977) Genetic and cytogenetic effects of formaldehyde and related compounds. *Compounds Mutat Res* 39: 317-362.
  36. Mass E, Zilberman UL (1989) Endodontic treatment of infected primary teeth, using Maisto's paste. *J Dent Child (Chic)* 56: 117-120.
  37. Hunter AR, Kirk EE, Robinson DH, Kardos TB (1998) A slow release calcium delivery system for the study of reparative dentine formation. *Endod Dent Traumatol* 14: 112-118.
  38. Goldman M, Pearson AH (1965) A preliminary investigation of the "hollow tube" theory in endodontics: Studies with neotetrazolium. *J Oral Thfukser Pharmacol* 1: 618-626.
  39. Fuks AB, Eidelman E, Pauker N (2002) Root fillings with endoflas in primary teeth: a retrospective study. *J Clin Pediatr Dent* 27: 41-45.
  40. Sato I, Ando-Kurihara N, Kota K, Iwaku M, Hoshino E (1996) Sterilization of infected root-canal dentin by topical application of a mixture of ciprofloxacin, metronidazole and minocycline *in situ*. *Int Endod J* 29: 118-124.
  41. Hoshino E, Kurihara-Ando N, Sato I (1996) *In-vitro* antibacterial susceptibility of bacteria taken from infected root dentine to a mixture of ciprofloxacin, metronidazole and minocycline. *Int Endod J* 29: 125-130.
  42. Takushige T, Cruz EV, Asgor Moral A, Hoshino E (2004) Endodontic treatment of primary teeth using a combination of antibacterial drugs. *Int Endod J* 37: 132-138.
  43. Trairatvorakul C, Detsomboonrat P (2012) Success rates of a mixture of ciprofloxacin, metronidazole, and minocycline antibiotics used in the non-instrumentation endodontic treatment of mandibular primary molars with carious pulpal involvement. *Int J Paediatr Dent* 22: 217-227.
  44. Kakarla P, Avula J, Mellela G, Bandi S, Anche S (2013) Dental pulp response to collagen and pulpotec cement as pulpotomy agents in primary dentition: a histological study. *J Conserv Dent* 16: 434-438.
  45. Aboujaoude S, Noueiri B, Berbari R, Khairalla A, Sfeir E (2015) Evaluation of a modified Pulpotec endodontic approach on necrotic primary molars: a one-year follow-up. *Eur J Paediatr Dent* 16: 111-114.
  46. Kriplani R, Thosar N, Baliga MS, Kulkarni P, Shah N, et al. (2013) Comparative evaluation of antimicrobial efficacy of various root canal filling materials along with aloe vera used in primary teeth: a microbiological study. *J Clin Pediatr Dent* 37: 257-262.
  47. Khairwa A, Bhat M, Sharma R, Satish V, Maganur P, et al. (2014) Clinical and radiographic evaluation of zinc oxide with aloe vera as an obturating material in pulpectomy: an *in vivo* study. *J Indian Soc Pedod Prev Dent* 32: 33-38.
  48. Queiroz AM, Nelson-Filho P, Silva LA, Assed S, Silva RA, et al. (2009) Antibacterial activity of root canal filling materials for primary teeth: zinc oxide and eugenol cement, Calen paste thickened with zinc oxide, Sealapex and EndoREZ. *Braz Dent J* 20: 290-296.
  49. Grossman LI (1980) Antimicrobial effect of root canal cements. *J Endodont* 6: 594-597.
  50. Tchaou WS, Turng BF, Minah GE, Coll JA (1996) Inhibition of pure cultures of oral bacteria by root canal filling materials. *Pediatr Dent* 18: 444-449.
  51. Reddy S, Ramakrishna Y (2007) Evaluation of antimicrobial efficacy of various root canal filling materials used in primary teeth - A microbiological study. *J Clin Pediatr Dent* 31: 195-199.
  52. Harini Priya M, Bhat SS, Sundeep Hegde K (2010) Comparative evaluation of bactericidal potential of four root canal filling materials against microflora of infected non-vital primary teeth. *J Clin Pediatr Dent* 35: 23-29.
  53. Jha M, Patil SD, Sevekar S, Jogani V, Shingare P (2011) Pediatric obturating materials and techniques. *J Contemp Dent* 2: 27-32.
  54. Abdulkader A, Duguid R, Saunders EM (1996) The antimicrobial activity of endodontic sealers to anaerobic bacteria. *Int Endod J* 29: 280-283.
  55. Estrela C, Estrela CRA, Hollanda ACB, Decurcio DA, Pecora JD (2006) Influence iodoform on antimicrobial potential of calcium hydroxide. *J Appl Oral Sci* 14: 33-37.
  56. Seow WK (1990) The effects of dyadic combinations of endodontic medicaments on microbial growth inhibition. *Pediatr Dent* 12: 292-297.
  57. Pabla T, Gulati MS, Mohan U (1997) Evaluation of antimicrobial efficacy of various root canal filling materials for primary teeth. *J Ind Soc Pedod Prev Dent* 15: 134-140.
  58. Pelczar MJ, Chan ECS, Krieg NR (1998) Control of microorganisms by chemical agents. In: *Microbiology*, (5th edn). Tata Mc Graw Hill, USA. p. 494.



59. Hegde S, Lala PK, Dinesh RB, Shubha AB (2012) An *in vitro* evaluation of antimicrobial efficacy of primary root canal filling materials. J Clin Pediatr Dent 37: 59-64.
60. Praetzel JR, Ferreira FV, Weiss RN, Friedrich RS, Guedes-Pinto AC (2008) Antimicrobial action of a filling paste used in pulp therapy in primary teeth under different storage conditions. J Clin Pediatr Dent 33: 113-116.
61. Fujisawa S, Atsumi T, Kadoma Y, Sakagami H (2002) Antioxidant and prooxidant action of eugenol-related compounds and their cytotoxicity. Toxicology 177: 39-54.
62. Huang TH, Ding SJ, Kao CT (2007) Biocompatibility of various formula root canal filling materials for primary teeth. J Biomed Mater Res B Appl Biomater 80: 486-490.
63. Wright KJ, Barbosa SV, Araki K, Spangberg LS (1994) *In vitro* antimicrobial and cytotoxic effects of Kri 1 paste and Zinc oxide-eugenol used in primary tooth pulpectomies. Pediatr Dent 16: 102-106.