



Original

Metastases to Breast: Clinico-Pathological and Radiological Correlation

Parveen Shah, Farhat Mustafa*, Aiffa Aiman, Saba Shafi, Annu Charak, Danish Rafiq, Imza Feroz and Iqbal Khaliq Baba

Department of Pathology, Sher-i-Kashmir Institute of Medical Sciences, Kashmir, India

ARTICLE INFO

Received 19 Feb. 2014
Received in revised form 26 Feb. 2014
Accepted 25 Mar. 2014

Keywords:

Breast Metastasis,
Extra-mammary site,
Mammography.

Corresponding author: Department of Pathology Sher-i-Kashmir Institute of Medical Sciences, Soura, Srinagar - 190011 Jammu and Kashmir, India.
E-mail address: fm2683@gmail.com

ABSTRACT

Metastatic lesions to the breast are unusual. We present a series of 26 cases of metastatic tumors to breast from extra-mammary sites over a period of 29 years. There were 14 female and 12 male patients, and their ages ranged from 28 to 70 years. The tumor was in the upper outer quadrant in 16 patients. All 26 cases noticed a mass in the breast and more than half of the patients complained of discomfort and pain. The mammary symptoms were present for more than 4 months in all patients. Of the 26 cases, 13 cases had metastatic adenocarcinoma, 12 cases had metastatic squamous cell carcinoma and one case had poorly differentiated carcinoma. On Mammography 16 patients showed high density lesions and on ultrasonography lesions were hypoechoic. Prognosis is poor but appears slightly improved since availability of more refined chemo and immunotherapeutic regimens. The clinical, pathologic, and radiographic features of this problem are described.

© 2014 British Biomedical Bulletin. All rights reserved



Introduction

Metastatic tumors to breast represents a mere 1-2% of all breast tumors^{1,2} Common tumors that metastasize to the breast include those from the lung, prostate, thyroid, kidney, hematopoietic system and malignant melanoma³⁻⁵. In children rhabdomyosarcoma is reported to be the more common primary source of metastatic breast lesion. In comparison, metastatic neoplasms from gastrointestinal primaries are rare and include the stomach, pancreas, oesophagus and colon. The majority of these tumors are adenocarcinomas⁶. Metastasis to the male breast is also very infrequent and has been reported in prostatic adenocarcinoma⁷.

The discovery of a breast mass in a patient known to have had previous therapy for cancer at another site may present a difficult diagnostic and therapeutic problem. Accurate diagnosis of metastasis is therefore important in order to avoid an unnecessary mastectomy and to guide further therapy. Since metastatic mammary tumors are uncommon, our experience seems of value in summarizing the salient clinical, radiological and pathological features of a series of patients, in whom such neoplasms were found.

Materials and Methods

We studied 26 biopsy proved cases of metastasis to the breast over 29 years (1983-2012) in the department of pathology at SKIMS. There were 14 female and 12 male patients, and their ages ranged from 28 to 70 years (Table-1). The primary tumors seen in this series are shown in (Table -2). All cases with primary breast malignancies were excluded from the study. Cases which were proved clinically, histologically and radiologically as metastatic tumors were included in this study.

Pathological diagnosis of breast metastasis was obtained in all cases (Mastectomy-10, core biopsy-5, excisional biopsy-11). Fine needle aspiration had been done in 21 cases. All patients had palpable single or multiple breast lumps. No nipple discharge or skin retraction was noted in any of these patients. 15 (57%) of these patients gave no history of prior malignant neoplasm and the breast mass was the first presentation of an unknown extra-mammary primary. In 5 patients (19.23%), breast metastasis were found with the initial diagnosis of primary malignancy. In the remaining 6 patients (23.07%) the patients had other distant metastasis in addition to breast metastasis.

The clinical records and follow up data were studied and all the available gross and microscopic materials were reviewed.

Mammography and ultrasonography was performed in 18 patients. The imaging findings were analysed retrospectively by the radiologist. We analysed the location, size, multiplicity and presence of axillary lymphadenopathy with both imaging modalities. Internal density, shape, margin, and associated calcification or other findings for each lesion were evaluated on mammography. On ultrasonography we evaluated internal echogenicity, shape, margin, associated findings such as interrupted superficial fascia, skin thickening, architectural distortion and depth of each lesion. The size was expressed as the longest diameter of a nodule.

Results

Out of a total of 26 cases, 14 cases (53.84%) were females in 28-70 year age group, the average age being 56 years. There were 12 (46.15%) male patients with an average age of 58 years. (Table-1). The right breast was the site of metastasis in 10 patients (38.46%), the left in 14 (53.84%)

patients and both breasts in 2 (7.69%) patients. The tumor was in the upper outer quadrant in 16 patients, the upper inner quadrant in 6 patients, the lower inner quadrant in 2 patients and the lower outer quadrant in one patient. The tumor appeared multinodular and involved simultaneously more than one quadrant in one case.

In general, the symptoms were similar to those of primary mammary carcinoma. All 26 cases noticed a mass in the breast and more than half of the patients complained of discomfort and pain. The mammary symptoms were present for more than 4 months in all patients. Of the 26 cases, 13 cases had metastatic adenocarcinoma (Figures 1, 2) 12 cases had metastatic squamous cell carcinoma (Figures 3, 4) and one case had poorly differentiated carcinoma. The gross size of the mammary lesion varied from 0.5 to 4.5 cm, with an average of 2 cm. The masses were round or oval, well circumscribed, non-encapsulated, firm and multinodular. In about half of the cases the tumors were adherent to the skin and superficially located in the subcutaneous and the immediate breast tissue. None of the tumors were fixed to the chest wall. Nipple retraction or discharge was not observed. Eight cases had palpable enlargement of ipsilateral axillary lymph node.

Gross as well as microscopic examination demonstrated the multinodular nature of these tumors. They were sharply demarcated from the surrounding breast tissue with prominent periductal and perilobular distribution. Occasionally intimate admixture of benign mammary epithelial cells and malignant tumor cells could be observed. The lining cells of mammary ducts showed no signs of hyperplasia or atypia. Similarly, no evidence of lobular hyperplasia or atypia were found. Calcification and necrosis were not seen.

Frozen section and biopsy was done in all cases followed by local excision of the breast mass.

Radiological findings

Mammography and ultrasonography was performed in 18 patients. 16 patients showed multiple or diffuse lesions and two patients had single lesions. Bilateral involvement was seen in 2 patients. The metastatic nodules ranged in size from 0.5-3.5 cm. In 12 patients, however the maximum size of the lesion was less than 3 cm. Axillary lymphadenopathy was detected in 5 patients.

On Mammography 16 patients showed high density lesions. In 12 patients the lesions were round to oval, with poorly defined obscured margins. In none of the lesions calcification was seen. Nine patients showed associated secondary signs, such as architectural distortion or trabecular thickening. In 3 patients with breast metastasis from stomach cancer, diffuse parenchyma involvement was seen.

On ultrasonography in 12 cases lesions were hypoechoic. The lesions were irregularly shaped in 9 cases and round to oval in 6 cases. The lesional margins were poorly defined in 9 cases (50%) and well defined in rest of the 9 cases. Likewise the lesions were heterogenous in 9 cases and homogenous in 9 cases. Associated secondary signs such as architectural distortion, interrupted superficial fascia or skin thickening were seen in 12 cases. Lesions were predominantly located superficially i.e. 16 cases.

Treatment and follow up

The treatment used in these cases varied. Simple or radical mastectomy was performed in 14 cases. Surgery followed by radiation in 4 cases or irradiation alone in 8 cases. Almost all the patients received various forms of chemotherapy in addition to the

above modalities. The appearance of mammary metastasis in all the cases was soon followed by the appearance of other distant metastasis. Despite the various forms of initial treatments and chemotherapy, 23 of the 26 patients died of the disease within 2 years, on the average after the breast biopsy. In all who died disease had a fulminant course and involved several organs.

Two patients were lost to follow-up after 6 months of the diagnosis of metastatic disease to breast. One patient was diagnosed only 6 months back and is on treatment.

Discussion

The breast is an uncommon site of involvement by metastatic disease from extra mammary malignancies⁸. Metastasis to the breast apparently indicates the beginning of widespread dissemination of disease. Mammary manifestations of extra mammary neoplasms is extremely rare⁹. Women are affected 5-6 times more frequently than men⁸. This is in contradiction to our study where we have almost equal distribution of male and female cases.

Breast metastasis maybe the first manifestation of malignant disease or the first site of metastatic disease from a known primary malignancy⁸⁻¹¹. In our study 15 cases (60%) represented the first manifestation of malignant disease. It is not always easy to make an accurate clinical and histologic diagnosis. Even if adequate information is available and the patient is a known cancer patient it is often most difficult to differentiate between primary and metastatic mammary neoplasms¹²⁻¹⁵. This is particularly true if the breast mass is the primary presentation of an unknown extra-mammary primary. Careful examination of the patient's past and present symptoms should be considered at the time of decision⁹.

Cancers metastatic to the breast usually appear as superficial, sharply defined

multinodular masses with predilection to the upper outer quadrant⁹. Generally chest wall fixation, peau d orange appearance, associated paget's disease or skin retraction and nipple discharge are absent although adherence to the skin has been reported in 25 % of cases^{8,9}. Lack of nipple discharge is probably due to the extraductal location of metastatic tumors¹⁶. In our study multiple lesions were more prevalent as was the location of lesions in the upper outer quadrant.

The time interval from the diagnosis of primary extra mammary neoplasm to breast metastasis varies between 1 month and 15 years, with averages between 1 and 5 years¹⁷. Rarity of breast involvement by metastatic tumors is due to large areas of fibrous tissue, relatively poor blood supply and anatomically non-connected locations¹⁸. Female hormones may play role in cancer predisposition, based on the high occurrence of breast metastases in pubescent, lactating, and pregnant female¹⁷. Overall metastasis to the breast has been associated with poor prognosis with most patients dying within a year of diagnosis^{19,20}.

The mammographic findings of breast metastases are usually single, well-defined or slightly irregular margins without desmoplastic reaction and distortion of adjacent architecture. There is no spiculation or micro calcification. Rarely diffuse parenchymal and skin involvement is seen^{16,18,21-23}. Ultrasound scan shows a hypoechoic mass, which is sometimes heterogeneous or poorly defined without architectural distortion²³. These radiological features are in conformity with our observations. Although radiology can provide some information to distinguish primary breast cancer from metastatic disease, excisional or core biopsy is usually needed for final diagnosis.

Bohman and co-workers emphasized the close correlation between sizes of palpable lesions and mammographic appearance of metastatic breast nodule due to

the absence of desmoplastic reaction, in contrast to the primary tumors. This also is manifested as absence of spiculation on mammography¹⁶.

The histological diagnosis of a metastatic mammary neoplasm is more difficult than the primary carcinoma of the breast. To suggest mammary carcinoma one should search for the periductal and/or perilobular distribution of mammary cells, in the absence of intraductal carcinoma and/or lobular carcinoma in situ. Histologically correct and type specific identification of the tumor is of utmost importance not only to prevent unnecessary surgery but to direct attention to extra-mammary primary. The final diagnosis has to be made by a pathologist⁹.

Metastasis from GIT is rare⁶. An increased incidence from GIT primary in our study is explained by the fact that the incidence of GI malignancies is high in this part of the world²⁴.

Conclusion

Breast metastasis, although rare, should be considered in the differential diagnosis of primary breast carcinoma, particularly if there is a history of extra mammary malignancy because the treatment and prognosis differ significantly. A history of a concurrent or previous malignancy combined with the clinic-radiological assessment and pathological evaluation is essential to diagnose breast metastasis.

References

- Nielsen M, Andersen JA, Henriksen FW, Kristensen PB, Lorentzen M, Ravn V, Schiodt T, Thorborg JV, Ornvold K: Metastases to the breast from extra mammary carcinomas. *Acta Pathol Microbiol Scand* [A] 1981, 89:251-256.
- Shetty MR: Carcinoid tumor of the breast. *Eur J Surg Oncol* 1996, 22:307.
- Hartgrink HH, Lagaay MB, Spaander H, Mulder H, Breslau PJ: A series of carcinoid tumors of the breast. *Eur J Surg Oncol* 1995, 21: 609-612.
- Kashlan RB, Powell RW, Nolting SF: Carcinoid and other tumors metastatic to the breast. *J Surg Oncol* 1982, 20: 25-30.
- Vergier B, Trojani M, Mascarel I, Coindre JM, Le Treut A: Metastases to the breast: differential diagnosis from primary breast carcinoma. *J Surg Oncol* 1991, 48: 112-116.
- Kanthan R, Negreiros F, Kanthan SC: Colonic carcinoid metastatic to the breast. *Arch Pathol Lab Med* 2003, 127:1373-1375.
- Alexander HR, Turnbull AD, Rosen PP: Isolated breast metastases from gastrointestinal carcinomas: Report of two cases. *J Surg Oncol* 42:264, 1989.
- Toombs BD, Kalisher L: Metastatic disease to the breast: Clinical, pathological and radiographic features. *AJR* 129:673, 1977
- Hajdu, S. I. and Urban, J. A. (1972), Cancers metastatic to the breast. *Cancer*, 29: 1691-1696.
- D'Orsi CJ, Feldhaus L, Sonnenfeld M: Unusual lesions of the breast. *Radiol Clin North Am* 21:67, 1983.
- McCrea ES, Johnston C, Haney PJ: Metastases to the breast. *AJR* 141:685, 1983.
- DeCosse, J. J., Berg, J. W., Fracchia, A. A., and Farrow, J. H.: Primary lymphosarcoma of the breast. A review of 14 cases. *Cancer* 15: 1264-1268, 1962.
- Deeley, T. J.: Secondary deposits in the breasts. *Br. J. Cancer* 19: 738-743, 1965.
- Lattes, R.: Sarcomas of the breast. *JAMA* 201: 531-532, 1967.
- McDivitt, R. W., Stewart, F. W., and Berg, J. W: Tumors of the breast. In Atlas of Tumor of Pathology, second series. Washington, D. C., Armed Forces Institute of Pathology, 1968.
- Bohman LG, Bassett LW, Gold RH, et al: Breast metastases from extra mammary malignancies. *Radiology* 144:309, 1982.
- Vergier B, Trojani M, De Mascarel I et al: Metastatic to the breast: differential diagnosis from primary breast carcinoma. *J Surg Oncol* 1991; 48:112-116.
- Lee SK, Kim WW, Kim SH, Hur SM, Kim S, Choi JH, Cho EY, Han SY, Hahn BK,

- Choe JH, Kim JH, Kim JS, Lee JE, Nam SJ, Yang JH. Characteristics of metastasis in the breast from extra mammary malignancies. *J Surg Oncol* 2010; 101:137-140.
19. Williams SA, Ehlers RA, Hunt KK, Yi M, Kuerer HM, Singletary SE, Ross MI, Feig BW, Symmans WF, Meric-Bernstam F. Metastases to the breast from nonbreast solid neoplasms: presentation and determinants of survival. *Cancer* 2007; 110:731-737.
 20. Min Yong Yoon, Chang Seok Song, MiHaeSeo, Min Jae Kim, Tae Yun Oh, Un Ha Jang, HyonJooKwag, Hee Sung Kim, Si Young Lim, Seong Yong Lim, Seung Sae Lee. A Case of Metachronous Metastasis to the Breast from Non-Small Cell Lung Carcinoma. *Cancer Res Treat.* 2010; 42:172-175.
 21. Noguera JJ, Martínez-Miravete P, Idoate F, Diaz L, Pina L, Zornoza G, Martínez-Regueira F. Metastases to the breast: A review of 33 cases. *Australas Radiol* 2007; 51:133-138.
 22. Mozaffari A, Rashidi I, Paziar F. Extra mammary tumors metastasis to the breast. *Pak J Med Sci* 2008; 24:468-470.
 23. Lee SH, Park JM, Kook SH *et al.* Metastatic tumors to the breast: mammographic and ultrasonographic findings. *J Ultrasound Med* 2000; 19:257-262.
 24. Rasool MT, Lone MM, Wani ML, Afroz F, Zaffar S, Mohib-ulHaq M. Cancer in Kashmir, India: Burden and pattern of disease. *J Can Res Ther* 2012; 8:243-6.

Table 1. Age distribution of patients

Age (years)	Total no.	Female	Males
20-29	1	1	-
30-39	3	2	1
40-49	1	-	1
50-59	10	8	2
60-69	8	2	6
70 and above	3	1	2
Total	26	14	12

Table 2. Malignant tumors metastatic to breast

Primary Tumor	No. of patients		Metastasis to breast		
	Males	Females	Right	Left	Both
Lung carcinoma	3	3	2	4	-
Ovarian carcinoma	-	2	1	1	-
Oesophageal carcinoma	2	4	2	4	-
Prostatic carcinoma	2	-	1	1	-
Gastric carcinoma	2	1	1	2	-
Pancreatic carcinoma	1	-	1	-	-
Carcinoma colon	1	2	2	1	-
Carcinoma rectum	1	2	-	1	2
Total	12	14	10	14	2

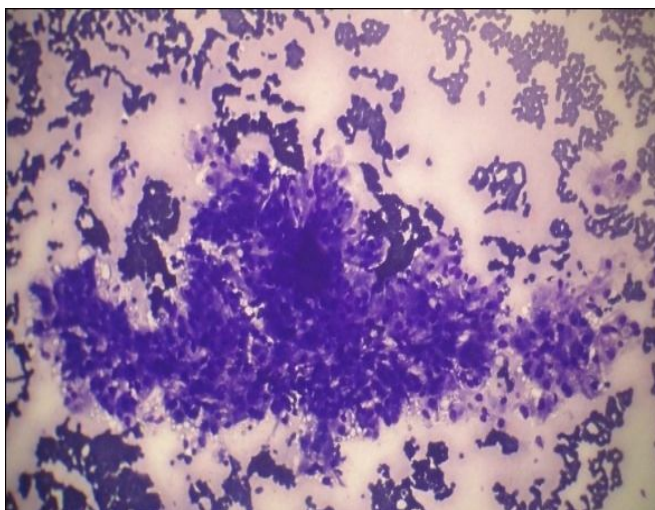


Figure 1. Photomicrograph showing tumor cells arranged in papillary configuration with individual cells having abundant vacuolated cytoplasm in adenocarcinomas metastasis to breast (MGG 10X)

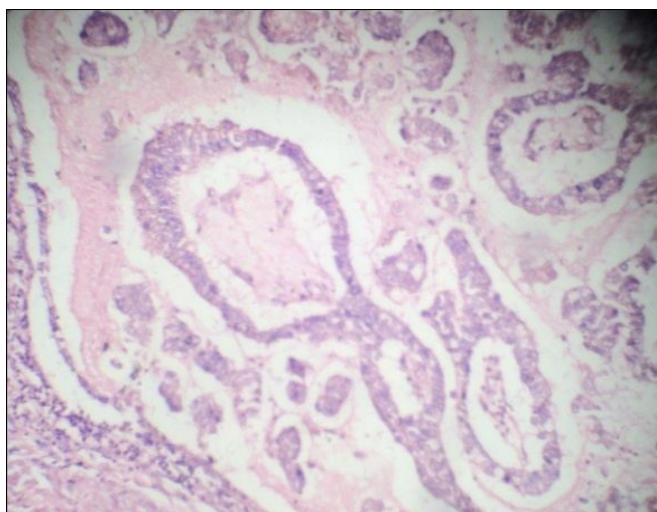


Figure 2. Photomicrograph showing well formed glands in adenocarcinoma metastasis to breast (H&E 20X)

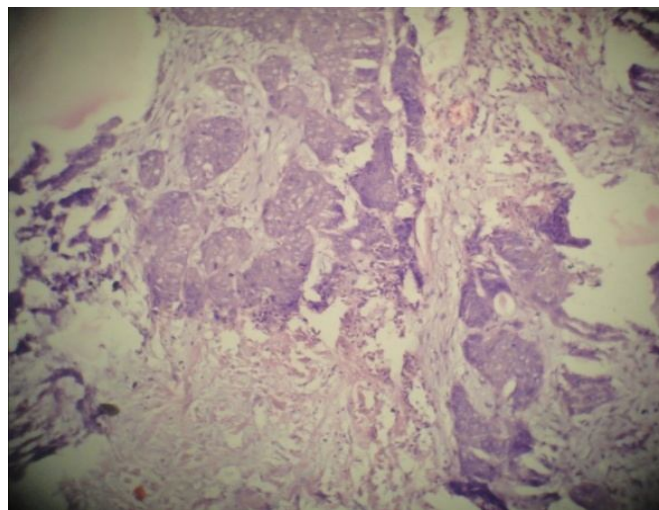


Figure 3. Photomicrograph showing squamous cell carcinoma metastasis to breast (H&E 10X)

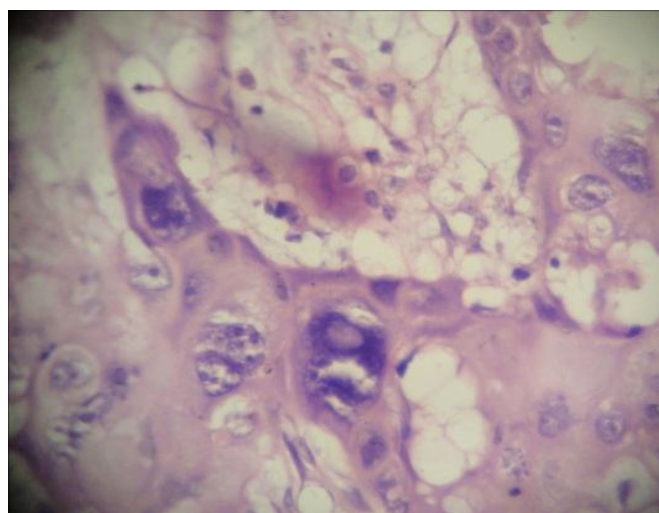


Figure 4. Photomicrograph showing large pleomorphic tumor cells in squamous cell carcinoma metastasis to breast (H&E 40X)