



## Original

# Immune Hemolytic Anemia in a Patient with *Plasmodium vivax* Malaria

Deepak Nayak M.\*, Sushma V. Belurkar and Anna Joseph Amprayil

Department of Pathology, Kasturba Medical College-Manipal, Manipal University, Manipal 576104, India

### ARTICLE INFO

Received 14 May, 2014  
Received in revised form 06 June, 2014  
Accepted 10 June, 2014

#### Keywords:

*Plasmodium vivax*;  
Hemolytic anemia;  
Jaundice.

Corresponding author: Deepak Nayak M.  
Department of Pathology, Kasturba  
Medical College-Manipal, Manipal  
University, Manipal 576104, India.  
E-mail address:  
[drdeepak.manipal@gmail.com](mailto:drdeepak.manipal@gmail.com)

### ABSTRACT

The combination of anemia in malarial infestations has been well documented in literature. But an immune hemolytic anemia developing within days of treatment for *Plasmodium vivax* malaria has seldom been reported. We present a case of a patient with vivax malaria who developed severe anemia and jaundice on day seven of initiating treatment with artesunate; necessitating expedient measures. This case highlights the importance, yet under-reported association of *Plasmodium vivax* malaria and immune-mediated hemolysis.

© 2014 British Biomedical Bulletin. All rights reserved

## Introduction

Malaria continues to be an important disease in India. The varied presentations of the disease and its diversity in terms of hematological manifestations have been well endowed in literature. By and large, anemia seen in malaria is multifactorial. This anemia ranges from an accelerated red blood cell removal by the spleen to ineffective erythropoiesis. Drug-induced hemolytic anemia is the other dimension to this aspect. However, the theory of immune-mediated hemolysis in malaria has gathered the attention of researchers in recent years. We describe here a rare case report where immune-mediated hemolysis developed in *Plasmodium vivax* malaria after completing a course of treatment.

## Case Report

A 16-year old male patient with a two-day history of high grade, intermittent fever with chills presented to the hospital. Peripheral smear and quantitative buffy coat (QBC) test showed both schizonts and ring forms of *Plasmodium vivax* malaria parasite. On admission, his hemoglobin was 9.8g/dl and platelet count was 40,000/mm<sup>3</sup>. The peripheral smear did not show hemolysis. As such, a follow up count for thrombocytopenia was advised. He was placed on intravenous artesunate for 5 days. Fever subsided on the third day of treatment. A repeat peripheral smear and QBC test were negative for the parasite. The patient was subsequently discharged.

However, the patient appeared for follow-up on the seventh day and complained of fatigue and mild lumbar pain. He was re-admitted and his hemoglobin had suddenly dropped to 6.3g/dl. The peripheral smear and QBC test performed were negative for the parasite. But the smear showed signs of hemolysis; evidenced by spherocytes and polychromasia (figure 1). A

Coomb's test was advised to ascertain an immune-mediated hemolysis; which showed a weak positivity for direct antibodies. Clinically, the patient was afebrile but pale. The biochemical tests showed a raised unconjugated bilirubin (6.3mg/dl) which confirmed the pre-hepatic hemolytic anemia. Other investigations showed a high reticulocyte count of 7.18%. The glucose-6-phosphate dehydrogenase (G6PD) enzyme assay was normal; although no bite or blister cells were appreciated in the smear. The patient received 2 units of packed red blood cells under steroid cover. On the twelfth day, the hemoglobin stabilized and picked up.

## Discussion

Anemia in malaria is not an uncommon association. The prevalence of anemia depends on many variables such as age and nutritional status of the patient and endemicity. The mechanism of anemia is caused by a variety of pathophysiologic mechanisms which include accelerated RBC removal by the spleen, obligatory RBC destruction at parasite schizogony (due to reduced red cell deformation of parasitized and non-parasitized erythrocytes) and ineffective erythropoiesis.<sup>1</sup> The recent advancements have shown that a variety of cytokine dysregulations are indeed vital participants in inducing and accelerating the pathogenesis of hemolysis in malaria. They include a significant increase in interferon (IFN) gamma, interleukin (IL)-6, tumour necrosis factor (TNF)-alpha, IL-1, hypoxia inducing factor (HIF)-1 and decrease in IL-10 and IL-12 levels.<sup>1</sup> Drug-mediated anemia has also been postulated. However, the crucial aspect of treatment in malaria is that the extent of hemolysis is much greater than that seen in other parasite-induced diseases. Thus, an underlying immune-mediated pathology has been suggested.<sup>2</sup>

There were similar trends in the present case. The sudden drop in hemoglobin was noted after the treatment course was completed; necessitating a packed red blood cell transfusion. The peripheral smear and QBC test was negative for malarial parasite. Hence, a direct parasite mediated cell lysis could be ruled out. The raised reticulocyte count along with a weak-positive direct Coombs' test point towards an immune-mediated cell destruction. Also corroborating these laboratory evidences is the clinical response after initiating corticosteroid therapy. A run through the literature reveals that a proportion of patients suffering from malaria develop immune hemolysis.<sup>3</sup> The reasons for immune hemolysis are multifactorial. The mechanisms include: a) serum antibodies directed against the parasite antigens sticking to red cells b) immune complex deposition leading to a by-stander hemolysis due to a parasite antigen or drug antibody complex, or c) due to oxidative damage and aggregation of red cell anion channel protein, subsequent coating of this denatured protein by naturally occurring autoantibody followed by their removal by macrophages in the reticuloendothelial system.<sup>4</sup>

In addition, increased levels of cytokines, including TNF-alpha can induce macrophages, which, in a hyperactive stage, may reduce their threshold for the amount of antibody coating needed for phagocytosis. Other postulated mechanism includes a loss of complement regulatory proteins CD-55 and CD-59 in parasitized cells; which are known to protect RBCs from inadvertent complement-mediated lysis. This coupled with increased levels of immune complexes in malarial infection makes RBCs susceptible to complement mediated lysis.<sup>1</sup>

While hemolysis has been reported in cases of *Plasmodium falciparum* malaria; both immune and non-immune; an association with *P. vivax* has seldom been

reported. To the best of our knowledge, there have been two single case reports of association of malaria and autoimmune hemolysis, from Korea and Canada.<sup>3,5</sup> Despite a high degree of prevalence of malaria in India, only sporadic case reports have surfaced.<sup>6,7</sup> This scarcity in literature may be attributed to the rarity of this phenomenon or due to under-recognition of this clinical phenomenon.

## Conclusion

Anemia in *P. vivax* malaria has been assigned to a number of aetiologies. Immune hemolytic anemia is probably the least mentioned one. This case is presented here to highlight the importance of identifying autoimmune hemolysis if a patient with malaria develops post treatment hemolysis or persistent anemia.

## Authors' Contributions:

Dr. Deepak Nayak M.: Writing the manuscript draft, consultation and correspondence.

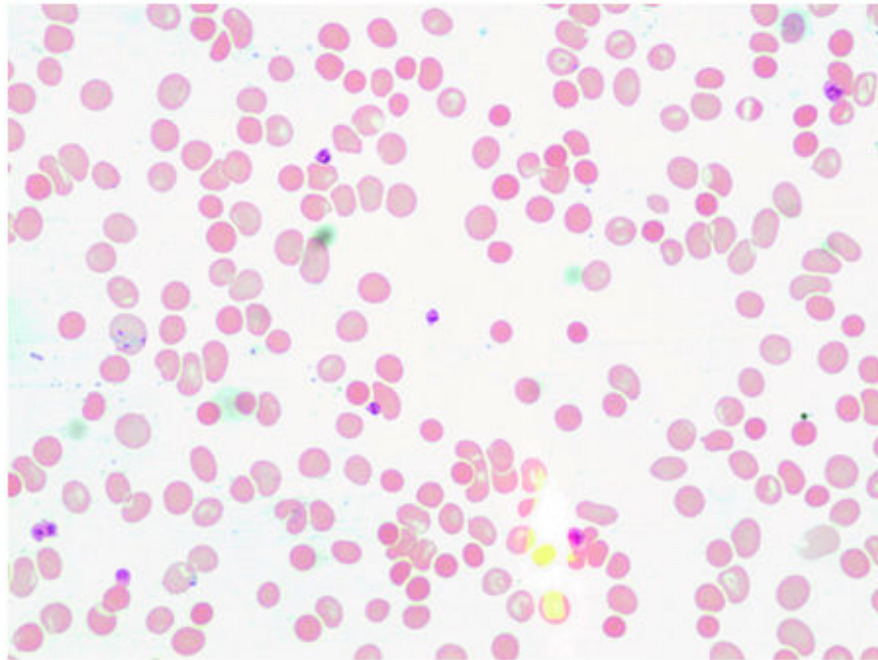
Dr. Sushma Belurkar: Expert opinion.

Dr. Anna Joseph Amprayil: data collection.

## References

1. Ghosh K, Ghosh K. Pathogenesis of anemia in malaria: A concise review. *Parasit Res* 2007; 101:1463-1469.
2. Dhaliwal G, Cornett PA, Tierney LM jr. Hemolytic anemia. *Am Fam Physician* 1979; 69:2599-606.
3. Drouin J, Rock G, Jolly E. Plasmodium falciparum malaria mimicking autoimmune hemolytic anemia during pregnancy. *Can Med Assoc J* 1985; 132.
4. Turrini F, Gribaldi G, Carta F, Mannu F, Arse P. Mechanism of band-3 oxidation and clustering in the phagocytosis of Plasmodium falciparum-infected erythrocytes. *Rodex Report* 2003; 8:300-303.

5. Lee S W, Lee S E, Chung B H, Hwang T J, Shin H S. A case of Plasmodium vivax malaria associated with autoimmune hemolytic anemia. *Infect Chemother* 2008; 40:63-66.
6. Sharma V, Samant R, Hegde A, Bhaja K. Autoimmune hemolysis in malaria: A report of three cases. *JAPI* 2012; 60:129-130.
7. Deshpande RH, Kulkarni RV. Cold agglutinin disease with malaria – a case report. *Int J Pharm Bio Sci* 2012 3(3): 800 – 803.



**Figure 1.** Peripheral smear showing sparse red blood cells, spherocytes and polychromasia (Leishman; x200)