

Comparison of Therapeutic Effects of 8 mg Dexamethasone Intramuscular Administered Pre-operatively vs. Post Operatively after the Surgical Extraction of Impacted Mandibular Third Molars

Khurram Latif Shah^{1*},
Abdulaziz Saud Al Lbad²,
Yusef Musirrah Al Anazi³,
Yusef Ahmad Al Khalaf⁴,
Mustafa Mohammed Balto⁵
and Zainab Jaafar Albahrani⁶

Abstract

Objective of this study was aimed to compare the therapeutic effects of 8 mg dexamethasone intramuscular administered pre-operatively vs post-operatively after the surgical extraction of impacted mandibular third molars, in Al-Qurayyat, Saudi Arabia, population. One hundred and fifty patients who visited the Department of Oral and Maxillofacial Surgery of Gurayat specialized dental center, Al-Qurayyat, Saudi Arabia, were included in the study. The study was conducted from February 2018 to August 2018. 150 patients constituted the study and were randomly divided into two groups. Group A received 8 mg dexamethasone (intramuscular) 1hr pre-operatively. Group B received 8 mg dexamethasone (intramuscular) immediately after the surgery. According to the gender there were 81(54%) males and 69 (46%) females, in both the groups combined. Males to females' ratio was 1.17: 1 in this study. Post-operative 1st and 3rd day follow-up showed that there was a significant difference between the two groups in terms of swelling and mouth opening (P=0.000). Overall, Group A showed much better results as far as the post-operative swelling and mouth opening was concerned. There was no statistical difference in the scores when the post-operative pain was evaluated on 1st, 3rd and 7th day (P=0.679, P=0.755, P=0.202). The depth, angulation and the position of the tooth did not affect the study in terms of significance (P=0.626, P=0.874, P=1.000). It was concluded that preoperative administration of single dose of dexamethasone intramuscularly was more effective than the post-operative period, in reducing the swelling and trismus.

Keywords: Dexamethasone; Post-operative swelling; Trismus; Intramuscular

- 1 Department of Oral and Maxillofacial, Gurayat General Hospital, Qurayyat, Saudi Arabia
- 2 Department of Oral and Maxillofacial, Specialized Dental Center, Al-Qurayyat, Saudi Arabia
- 3 Department of Oral Medicine, Specialized Dental Center, Al-Qurayyat, Saudi Arabia
- 4 Department of Oral and Dental Surgery, Al Dammam, Saudi Arabia
- 5 General Dentist, Ministry of Health, Al-Qurayyat, Saudi Arabia
- 6 General Dentist, Al-Hassa Psychiatric Hospital, Al-Hassa, Saudi Arabia

*Corresponding author: Khurram Latif Shah

✉ kshah@moh.gov.sa

Department of Oral and Maxillofacial, Gurayat General Hospital, Qurayyat, Saudi Arabia.

Tel: +966-508248985

Received: June 11, 2018, Accepted: June 26, 2018, Published: June 29, 2018

Introduction

The Mandibular third molars are the most commonly impacted teeth ranging from 16.7% to 68.6% among general population [1,2]. They usually require extraction either in the early or the late life time of a person and most common procedure done in the maxillofacial clinics worldwide [3].

There are various indications for extraction of the impacted third molars, such as pericoronitis, pre or post-orthodontic treatment, neoplasms, cystic and infective lesions of the mandible, tooth transplantation, and to avoid bone loss/caries/damage to adjacent tooth [4]. The surgical procedure to extract

the wisdom teeth accompanies the post-operative complications like pain, swelling, trismus, bruising, and difficulty in chewing and swallowing [5]. In the past, various techniques and medications have been used to improve the quality of life of the patient in the post-operative recovery period and to minimize the adverse

effects of the surgery. Corticosteroids have proven to be the most effective [6-8]. Corticosteroids are natural steroid hormones that are produced in the adrenal cortex of vertebrates. They are 21 carbon compounds having a cyclopentano perhydrophenanthrene (steroid) nucleus. They were discovered by Dr. William C. Kendall, who later on, together with Drs. Phillip S. Hench and Tadeus Reichstein, won a Nobel Prize for Physiology or Medicine. It was first used to reduce the inflammatory process of rheumatoid arthritis [9]. Due to least adverse effects on leukocyte chemotaxis, which is important in inflammation and healing, dexamethasone and methylprednisolone have been extensively used in various oral surgical procedure [10].

Glucocorticoids such as dexamethasone and methylprednisolone exert their anti-inflammatory reaction by binding to specific receptor within the cell. The result of the receptor-steroid complex is the regulation of the synthesis of inflammatory autacoids and immune-related cytokines [11,12].

There is adequate evidence suggesting that the excess of the glucocorticoids can lead to euphoria and psychosis, whereas deficiency results in lethargy, apathy and depression [12].

Dexamethasone has proven itself to be one of the most effective anti-inflammatory agents and this has been a prime reason for its use following the minor and the major surgical procedures in the field of oral and maxillofacial surgery across the globe since 3-4 decades [13].

A single large dose of glucocorticoid or a short course of the therapy (1-7 days), in the absence of local or systemic contraindications, is every likely to be harmless [14].

There is no clear consensus regarding the dose, timing, route and duration of administration of dexamethasone [15,16]. In this randomize clinical trial we compared the effects of intramuscular dexamethasone injection Prior to and after the extraction of impacted lower third molars.

Materials and Methods

The One hundred and fifty healthy patients requiring surgical removal of the mandibular impacted third molar under local anaesthesia constituted the study group. All the patients reported to the outpatient clinic, Oral and Maxillofacial Surgery Department, Gurayat Dental Centre, Saudi Arabia. The duration of study was 6 months, including the follow up, starting from February 2018 to August 2018.

Complete study protocol was explained to the patients who fulfilled the inclusion criteria.

Inclusion criteria

1. Al Qurayyat, Saudi Arabia, population.
2. Patients indicated for surgical extraction of impacted lower third molar/molars.
3. Age of the patient, 18 years or older.
4. Medically/systemically fit.
5. Unilateral or bilateral, partial or complete, bony impacted

mandibular third molar.

6. All patients who agree to participate in the study.

Exclusion criteria

1. Patient with history of allergy to dexamethasone.
2. Pregnant or lactating female.
3. Simple or non-surgical extraction.
4. Any surgery extending more than 45 min of time period.

Demographic details and the written informed consent were entered on a Proforma and signed by patients.

All patients were subjected to clinical and radiographic examination, by single examiner (periapical x-ray, Orthopantomogram OPG). The patients were randomly distributed into two groups using the computer based software "Epicalc200". Each group constituted of 75 patients. Both researcher and the patients were blind at the time of randomization. Patients in Group A received 8 mg dexamethasone (intramuscular) 1 hr pre-operatively. Patients in Group B received 8 mg dexamethasone (intramuscular) immediately after surgery.

Surgical technique

All the surgeries were performed by the same maxillofacial surgeon. Patients were advised to rinse their mouth by 0.12% Chlorhexidine mouthwash. Local anaesthesia, 2% Lidocaine (1:100000 epinephrine) was administered to all the patients. Three sided mucoperiosteal flap was reflected, bone guttering was done under sterile saline irrigation and if required the tooth was sectioned into multiple pieces. Once the tooth was delivered from the socket, the socket was irrigated with 0.12% Chlorhexidine and normal saline wash. The walls of the socket were smoothed and flap was repositioned and sutured by 3/0 or 4/0 black silk. The patients were given the routine post-operative home care instruction. The sutures were removed at 7th day follow up. The duration of the surgery ranged from 30-45 minutes, starting from incision until the last suture was placed.

Assessment of the patients

Swelling

Facial measurements were taken in 3 planes using modified measuring tape method described by Ustun, Gabka, Matsumara, Schultze-Mosgau and co-authors [17-19]. The three facial planes (cm) were:

M1: Distance from the tragus of the ear to the corner of the mouth.

M2: Distance from the tragus of the ear to the pogonion.

M3: Distance from lateral canthus of the eye to the angle of the mandible.

The sum of all these measurements were considered as the base line of that side, and the mean was extracted from them. The measuring was done pre-operatively, on the 1st, 3rd and 7th days post operatively.

Trismus

Maximum interincisal opening was measured pre-operatively, 1st, 3rd and 7th days post-surgery, by using calibrated Vernier calliper [20].

Pain

Visual analog scale was used to analyzed the intensity of the pain (0-10) 1st, 3rd and 7th days post-surgery (Figure 1) [21].

Statistical analysis

Data was analyzed by using SPSS 21.0. Quantitative variables were presented as means and standard deviations. Qualitative variables were presented as frequencies and percentages. The results of the two groups were compared using t-test and chi-square test. The level of significant was set at $P < 0.05$.

Results

150 healthy patients were included in the study and results were analyzed. These patients were divided into 2 groups. Group A; 75 patients received intra-muscular 8 mg dexamethasone 1 hour pre-operatively and Group B; 75 patients received intra-muscular 8 mg dexamethasone immediate post-operatively. The patients were randomly divided into two groups. According to the gender there were 81(54%) males and 69 (46%) females, in both the groups combined. Males to female's ratio was 1.17: 1 in this study.

Post-operative 1st and 3rd day follow-up showed that there was a significant difference between the two groups in terms of swelling and mouth opening ($P=0.000$). Overall, Group A showed much better results as far as the post-operative swelling and mouth opening was concerned. There was no statistical difference in the

scores when the post-operative pain was evaluated on 1st, 3rd and 7th day ($P=0.679$, $P=0.755$, $P=0.202$).

The depth, angulation and the position of the tooth did not affect the study in terms of significance ($P=0.626$, $P=0.874$, $P=1.000$) (Tables 1-8).

Discussion

Asurgical insult in the oral cavity leads to tissue injury characterized by increased osmotic pressure in capillaries (Starling law). It states that the fluid movement due to filtration across the wall of a capillary is dependent on the balance between the hydrostatic pressure gradient and the oncotic pressure gradient across the capillary. It presents itself as hyperaemia, vasodilatation, increased capillary permeability with liquid accumulation in the interstitial space and cellular migration [22,23].

The post-operative tissue response in 3rd molar extractions is highly unpredictable. Gender, weight, duration of surgery, degree and depth of impacted tooth, surgical methods used, density of bone, skill of the operator, angulation and size of the tooth, a proximity of the tooth to the vital structures, amount of the tooth developed and association with a pathological lesion affect the post-operative swelling, pain, trismus, compromised oral intake of fluids and diet, aesthetic deformity, fracture of the angle of the mandible and infection [24,25].

Corticosteroids have been used since long by many surgeons to decrease the post-operative sequelae in 3rd molar surgeries. According to the literature review conducted by Francesco and co-authors [26] analysis of the scientific publications in the last 20 years revealed that there were no definite protocols relative to different molecules or regimens, time and route of administration of corticosteroids in preventing the post-operative adverse effects in 3rd molar surgeries. Dexamethasone, dexamethasone sodium phosphate, dexamethasone acetate, methylprednisolone, methylprednisolone acetate and methylprednisolone sodium succinate have been extensively studied in the last 5 to 6 decades and their therapeutic effects, in the 3rd molar surgery, have been documented. It is a proven fact that Long-acting steroids give better results than short-acting ones and intramuscular and intravenous routes of administration have almost same effects [27,28].

There are various factors which influence the post-operative outcomes in an impacted third molar surgery. Factors like age, gender, duration of surgery, angulation and depth of impacted tooth and operator skill commonly affect the significance of the study. In our study they were statistically insignificant and did not affect the comparative analysis between the two groups.

A study conducted by Hashem M revealed that pre-operative administration of dexamethasone is more effective than the post-operative period [29]. Post-operative edema on 2nd, 5th and 7th day was evaluated for both groups and showed significant results on all the occasions. For Group B (post-operative group) P-value was 0.003, 0.003 and 0.038 respectively showing that on all the occasions there was statistical increase in the swelling and edema in Group B. Our study showed almost similar results as there was significant difference on the 1st and 3rd day follow-up after

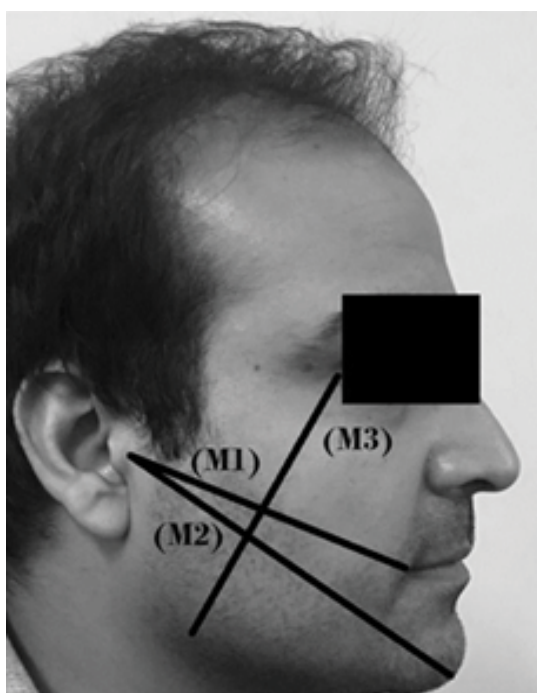


Figure 1 Three facial planes according to the Schultze-Mosgau [19].

Table 1 Distribution of the patients according to the gender.

Description		Frequency and Percentages		Total
		Group A	Group B	
Gender of the patients	Females	37(49.33%)	32(42.67%)	69(46%)
	Males	38(50.67%)	43(57.33%)	81(54%)
Total		75(100%)	75(100%)	150(100%)

Group A= 8 mg Intra-muscular Dexamethasone 1 Hour Pre-operatively
Group B= 8 mg Intra-muscular Dexamethasone Immediate Post-operatively

Table 2 Descriptive statistics of age of the patients (Years).

Description	Group A	Group B	Combined Groups(Total)
Total number of Patients (N)	75	75	150
Mean	25.67	25.57	25.62
Standard Deviation	5.50	5.75	5.61
Standard Error Mean	0.64	0.66	0.65
Minimum age of a patient (years)	18	18	18
Maximum age of a patient (years)	40	40	40

Group A= 8 mg Intra-muscular Dexamethasone 1 Hour Pre-operatively
Group B= 8 mg Intra-muscular Dexamethasone Immediate Post-operatively
Equal Variance assumed F= 0.039, t-test=0.102
P-value= 0.919

Table 3 Descriptive statistics of mean values of swelling (cm).

Description	Group A	Group B	Equal Variance (F)	t-test	Significance Value (P)
Pre-operative Swelling (cm)	11.69	11.83	0.24	-1.091	0.277
Post-operative 1 st Day Swelling (cm)	12.214	15.112	1.39	-12.89	0.000
Post-operative 3 rd Day Swelling (cm)	12.146	13.852	25.732	-5.895	0.000
Post-operative 7 th Day Swelling (cm)	11.815	11.927	1.520	-0.869	0.386

Group A= 8 mg Intra-muscular Dexamethasone 1 Hour Pre-operatively
Group B= 8 mg Intra-muscular Dexamethasone Immediate Post-operatively

Table 4 Descriptive statistics of mean values of mouth opening (mm).

Description	Group A	Group B	Equal Variance (F)	t-test	Significance Value (P)
Pre-operative Mouth Opening (mm)	48.926	49.176	0.036	-0.526	0.600
Post-operative 1 st Day Mouth Opening (mm)	38.284	31.120	1.946	12.642	0.000
Post-operative 3 rd Day Mouth Opening (mm)	40.841	36.425	0.046	5.910	0.000
Post-operative 7 th Day Mouth Opening (mm)	48.032	48.722	0.560	-1.072	0.285

Group A= 8 mg Intra-muscular Dexamethasone 1 Hour Pre-operatively
Group B= 8 mg Intra-muscular Dexamethasone Immediate Post-operatively

surgery (p-value= 0.000 and 0.000 respectively) but insignificant findings on 7th day (p-value= 0.386). Further in their study, for trismus, only after 7 days, group B showed statistically significant higher mean% reduction in maximum interincisal opening value than group A (p-value= 0.021). This contradicts with our study in which group B showed statistically significant higher mean% reduction in maximum interincisal opening value on 1st and 3rd days and insignificant values on 7th day (p-value= 0.000, 0.000, 0.285 respectively). There are multiple studies which are consistent with the findings of our study. Laureano Filho compared the efficacy of different doses of dexamethasone given 1 h pre-operatively [30]. They found a significant reduction of post-operative complications with the use of 8 mg of dexamethasone.

Majid [16] presented reports on the effects of dexamethasone in 2011. In one of the reports, he compared the effect of submucosal and intramuscular injection of 4 mg dexamethasone after third molar surgery in his subjects. Both routes produced significantly less swelling and pain than control. Deo and Shetty studied the efficacy of single injection of a higher dose (8 mg) of dexamethasone given pre-operatively in the third molar surgery [31]. They found that dexamethasone proved significantly effective in reducing swelling and trismus on the second day post-operative. Majid and Mahmood compared the effect of giving post-operative dexamethasone using various routes of administration, namely intramuscular injection, intravenous injection, oral tablets, submucosal injection and endo-alveolar application [32]. Their study revealed no significant differences

Table 5 Descriptive statistics of mean values of pain (VAS*).

Description	Group A	Group B	Equal Variance (F)	t-test	Significance Value (P)
Pre-operative Pain Score	0.00	0.00	t cannot be extracted because standard deviations of both groups are zero.		
Post-operative 1 st Day Pain Score	4.45	4.53	0.572	-0.014	0.679
Post-operative 3 rd Day Pain Score	2.43	2.40	1.051	0.313	0.755
Post-operative 7 th Day Pain Score	0.16	0.08	6.422	1.282	0.202

Group A= 8 mg Intra-muscular Dexamethasone 1 Hour Pre-operatively
Group B= 8 mg Intra-muscular Dexamethasone Immediate Post-operatively
*VAS= Visual Analog Scale (0-10)

Table 6 Distribution according to the angulation of impacted teeth among the groups.

Description	Angulation of Impacted Tooth*				Total	
	Disto-Angular	Horizontal	Mesio-Angular	Vertical		
Study Groups	A Count	14	14	32	15	75
	% within study groups	18.7%	18.7%	42.7%	20.0%	100.0%
	B Count	18	13	31	13	75
	% within study groups	24.0%	17.3%	41.3%	17.3%	100.0%
Total	Count	32	27	63	28	150
	% within study groups	21.3%	18.0%	42.0%	18.7%	100.0%

Group A= 8 mg Intra-muscular Dexamethasone 1 Hour Pre-operatively
Group B= 8 mg Intra-muscular Dexamethasone Immediate Post-operatively
*Winter's Classification for Angulation of The Impacted Teeth
Pearson Chi-Square test= 0.874

Table 7 Distribution according to the level of impacted teeth among the groups.

Description	Level of Impacted Tooth*			Total	
	A	B	C		
Study Groups	A Count	20	40	15	75
	% within study groups	26.7%	53.3%	20.0%	100.0%
	B Count	18	37	20	75
	% within study groups	24.0%	49.3%	26.7%	100.0%
Total	Count	38	77	35	150
	% within study groups	25.3%	51.3%	23.3%	100.0%

Group A= 8 mg Intra-muscular Dexamethasone 1 Hour Pre-operatively
Group B= 8 mg Intra-muscular Dexamethasone Immediate Post-operatively
*Pell & Gregory Levels of the Impacted Teeth
Pearson Chi-Square test= 0.626

Table 8 Distribution according to the class of impacted teeth among the groups.

Description	Class of Impacted Tooth*			Total	
	I	II	III		
Study Groups	A Count	0	40	35	75
	% within study groups	0.0%	53.3%	46.7%	100.0%
	B Count	0	40	35	75
	% within study groups	0.0%	53.3%	46.7%	100.0%
Total	Count	0	80	70	150
	% within study groups	0.0%	53.3%	46.7%	100.0%

Group A= 8 mg Intra-muscular Dexamethasone 1 Hour Pre-operatively
Group B= 8 mg Intra-muscular Dexamethasone Immediate Post-operatively
*Pell & Gregory Class of the Impacted Teeth
Pearson Chi-Square test=1.000

among groups on any follow-up days in terms of swelling, pain and trismus in the subjects. They stated that "to control the swelling, the best results were obtained via the intravenous

route, followed by the intramuscular, submucosal, oral and endo-alveolar routes in a descending order".

Warraich found dexamethasone was significantly beneficial in reducing pain and trismus [19]. Their patients were also satisfied as they suffered fewer complications post-operatively. In summary, dexamethasone has proven to be an effective agent for reducing pain, swelling and trismus to a certain degree, irrespective of the route and the timing of administration. Variations in the results may be because of differences in surgical methods, differences in individual response to treatment and differences in the methodology used.

Further studies should be carried out to evaluate the effect of various corticosteroids in difficult and lengthy surgeries. These surgeries might advocate the use of the steroids for longer durations. Their effects might also differ due to the tissue response to extensive surgical trauma. Variables, like presence

of infection, weight of the patient, associated pathological conditions, systemically compromised patients; extractions requiring general anesthesia, etc. should also be studied to evaluate the effect of the steroids.

Conclusion

It was concluded from the study that superior post-operative therapeutic effects are achieved by pre-emptive administration of 8 mg intramuscular injection of dexamethasone as compared to post-surgical administration in impacted third molar surgeries. Post-operative swelling and trismus were significantly reduced in the early post-surgical period. Pain on the other hand showed no significant reduction in the intensity in either of the groups.

References

- 1 Lima CJ, Silva LC, Melo MR, Santos JA, Santos TS (2012) Evaluation of the agreement by examiners according to classification of third molars. *Med Oral Patol Oral Cir Bucal* 17: 281-216.
- 2 Kaya GS, Aslan M, Ömezli MM, Dayi E (2010) Some morphological features related to mandibular third molar impaction. *J Clin Exp Dent* 2: 12-17.
- 3 Shepherd JP, Brickley M (1994) Surgical removal of third molars. *BMJ* 309: 620-621.
- 4 Spiotto MT, Juodzbalys G, Daugela P (2013) Mandibular third molar impaction: Review of literature and a proposal of a classification. *J Oral Maxillofac Res* 4: 1-12.
- 5 Bouloux GF, Steed MB, Perciaccante VJ (2007) Complications of third molar surgery. *Oral Maxillofac Surg Clin North Am* 19: 117-128.
- 6 Kirmeier R, Truschneegg A, Payer M, Acham S, Schulz K, et al. (2007) Evaluation of a muscle relaxant on sequelae of third molar surgery: A pilot study. *Oral Surg Oral Med Oral Pathol Oral Radiol Endod* 104: 8-14.
- 7 Markovic A, Todorovic L (2007) Effectiveness of dexamethasone and low-power laser in minimizing edema after third molar surgery: A clinical trial. *Int J Oral Maxillofac Surg* 36: 226-229.
- 8 Chopra D, Rehan HS, Mehra P, Kakkar AK (2009) A randomized, double blind, placebo-controlled study comparing the efficacy and safety of paracetamol, serratiopeptidase, ibuprofen and betamethasone using the dental impaction pain model. *Int J Oral Maxillofac Surg* 38: 350-355.
- 9 Hench PS, Kendall EC, Slocumb CH, Polley HF (1949) The effect of a hormone of the adrenal cortex (17-hydroxy-II-dehydrocorticosterone; compound E) and of pituitary adrenocorticotrophic hormone on rheumatoid arthritis. *Proc Staff Meet Mayo Clin* 24: 181-197.
- 10 Peterson LJ (2003) Principles of management of impacted teeth. *Contemporary oral and Maxillofacial* (4th ed) St Louis: CV Mosby, Surgery pp: 184-213.
- 11 Rhen T, Cidlowski JA (2005) Anti-inflammatory action of glucocorticoids: New mechanisms for old drugs. *N Engl J Med* 353: 1711-1723.
- 12 Stewart PM, Krone NP (2011) The adrenal cortex Williams Textbook of Endocrinology. 12th ed. Philadelphia, Pa: Saunders Elsevier.
- 13 Kiran S, Gupta AK, Dhingra D, Prakash S, Kinikar K, et al. (2016) Comparison and evaluation of role of dexamethasone and diclofenac sodium in control of postoperative pain and swelling following third molar surgery: A clinical study. *Int J Oral Care Res* 1: 107-117.
- 14 Schimmer BP, Funder JW (2011) ACTH, adrenal steroids and pharmacology of the adrenal cortex. Goodman and Gilman's The Pharmacological Basis of Therapeutics. 12th ed. New York, NY: McGraw-Hill Companies Inc.
- 15 Alexander RE, Thronson RT (2000) A review of perioperative corticosteroid use in dentoalveolar surgery. *Oral Surg Oral Med Oral Pathol Oral Radiol Endod* 90: 406-415.
- 16 Majid OW, Mahmood WK (2011) Effect of submucosal and intramuscular dexamethasone on postoperative sequelae after third molar surgery: Comparative study. *Br J Oral Maxillofac Surg* 49: 647-652.
- 17 UStün Y, Erdogan O, Esen E, Karsli ED (2003) Comparison of the effects of 2 doses of methylprednisolone on pain, swelling, and trismus after third molar surgery. *Oral Surg Oral Med Oral Pathol Oral Radiol Endod* 96: 535-539.
- 18 Gabka J, Matsumura T (1971) Measuring techniques and clinical testing of an anti-inflammatory agent (tantum). *Munch Med Wochenschr* 113: 198-203.
- 19 Warraich R, Faisal M, Rana M, Shaheen A, Gellrich NC, et al. (2013) Evaluation of postoperative discomfort following third molar surgery using submucosal dexamethasone. A randomized observer blind prospective study. *Oral Surg Oral Med Oral Pathol Oral Radiol* 116: 16-22.
- 20 DE Santana-Santos T, De Souza-Santos AA, Martins-Filho PR, Da Silva LC, De Oliveira E Silva ED, et al. (2013) Prediction of postoperative facial swelling, pain and trismus following third molar surgery based on preoperative variables. *Med Oral Patol Oral Cir Bucal* 18: 65-70.
- 21 Jarrah MH, Al-Rabadi HF, Imrayan M, Al-share AA (2015) Single dose of dexamethasone with or without ibuprofen effects on post-operative sequelae of lower third molar surgical extraction. *JRMS* 22: 41-45.
- 22 Messer EJ, Keller JJ (1975) The use of intraoral dexamethasone after extraction of mandibular third molars. *Oral Surg Oral Med Oral Pathol* 40: 594-598.
- 23 Beirne OR, Hollander B (1986) The effect of methylprednisolone on pain, trismus, and swelling after removal of third molars. *Oral Surg Oral Med Oral Pathol* 61: 134-138.

- 24 Akadiri OA, Okoje VN, Arotiba JT (2008) Identification of risk factors for short-term morbidity in third molar surgery. *Odontostomatol Trop* 31: 5-10.
- 25 Akadiri OA, Obiechina AE (2009) Assessment of difficulty in third molar surgery: A systematic review. *J Oral Maxillofac Surg* 67: 771-774.
- 26 Sortino F, Cicciu M (2011) Strategies used to inhibit postoperative swelling following removal of impacted lower third molar. *Dent Res J* 8: 162-171.
- 27 Das J, Sreejith V, Anooj P, Vasudevan A (2015) Use of Corticosteroids in third molar surgery: Review of literature. *Uni Research J Dent* 5: 171.
- 28 Vyas N, Agarwal S, Shah N, Patel D, Aapaliya P (2014) Effect of single dose intramuscular methylprednisolone injection into the masseter muscle on the surgical extraction of impacted lower third molars: A randomized controlled trial. *Kathmandu Uni Med J* 12: 4-8.
- 29 Al-Shamiri HM, Shawky M, Hassanein N (2017) Comparative assessment of preoperative versus postoperative dexamethasone on postoperative complications following lower third molar surgical extraction. *Int J Dent* 1-7.
- 30 Filho JRL, Maurette PE, Allais M, Cotinho M, Fernandes C (2008) Clinical comparative study of the effectiveness of two dosages of dexamethasone to control post-operative swelling, trismus and pain after the surgical extraction of mandibular impacted third molars. *Med Oral Patol Oral Cir Bucal* 13: 129-132.
- 31 Deo SP, Shetty P (2011) Effect of submucosal injection of dexamethasone on post-operative sequelae of third molar surgery. *J Nepal Med Assoc* 51: 71-77.
- 32 Majid OW, Mahmood WK (2013) Use of dexamethasone to minimise post-operative sequelae after third molar surgery: Comparison of five different routes of administration. *Oral Surg* 6: 200-208.