

## Clinicotherapeutic Profile of Patients Suffering from Sinusitis

Sandhu S<sup>1</sup>, Gupta V<sup>2</sup> and Matreja PS<sup>3</sup>

### Abstract

**Background:** Sinusitis is a group of diseases which affects the mucosa of nose and PNS. There are various anatomical variations that may at times be the cause of disease by blocking the normal drainage of PNS. In India approximately 15% population suffers from PNS. It is not just health implication but also affect the economic and quality of life aspects of affected patients. The purpose of study was to characterize the clinic therapeutic profile of patients suffering of sinusitis and to correlate the clinical profile with treatment.

**Methodology:** This prospective observational study was conducted on 50 patients visiting outpatients department of otorhinolaryngology, after they gave a written informed consent. Patients with symptoms of sinusitis were evaluated with anterior rhinoscopy, diagnostic nasal endoscopy, confirmation of diagnosis was done using radiological investigation.

**Results:** The main clinical symptoms present in all patients were nasal obstruction, postnasal drip, headache, and sneezing. Few patients also reported facial pain, hyposmia/anosmia, cough, fatigue and fever. Treatment given to patients included antibiotics to 20 patients, oral decongestant to 14 patients, nasal decongestant to 16 patients, analgesic to 1 patients, and oral steroid to 1 patients. Septoplasty was done in 32 patients, whereas, functional endoscopic sinus surgery was done in 8 patients.

**Conclusion:** In the present study most common symptoms were nasal obstruction, post nasal drip, headache and sneezing. Most common anatomical variation was septal deviation. Septoplasty was adequate for treatment of sinusitis with deviated septum and functional endoscopic sinus surgery was most effective treatment for chronic sinusitis.

**Keywords:** Sinusitis; Septal deviation; Nasal obstruction; Post nasal drip

- 1 Gian Sagar Medical College and Hospital, Village Ram Nagar, District Patiala 140601, Punjab, India
- 2 Department of Otorhinolaryngology, Maharishi Markandeshwar Institute of Medical Science and Research, Solan 173229, Himachal Pradesh, India
- 3 Department of Pharmacology, Teerthankar Mahavir Medical College & Research Center, TMU, Moradabad, 244001, Uttar Pradesh, India

**Corresponding author:** Matreja PS

✉ drpsmatreja@gmail.com

Professor and Head, Department of Pharmacology, Teerthankar Mahavir Medical College & Research Centre, TMU Moradabad, Uttar Pradesh, India

**Tel:** +91-9855001847

**Citation:** Sandhu S, Gupta V, Matreja PS. Clinicotherapeutic Profile of Patients Suffering from Sinusitis. J Transm Dis Immun. 2017, 1:1.

**Received:** December 01, 2016; **Accepted:** December 26, 2016; **Published:** January 07, 2017

### Introduction

Sinusitis affects the mucosa of nose and Para nasal sinus (PNS) affecting approximately 15% population in India. The manifestations of sinusitis vary from headache, postnasal discharge (PND), facial pressure, nasal congestion, nasal obstruction, smell disorders, cough to Eustachian tube dysfunction. Endoscopic examination detects and evaluates the anatomical evaluations like septal deviation and other inflammatory changes abnormal purulent secretions, inflammatory edema, polypoidal changes, and fungal accumulation. Plain radiograph can give an idea about involvement of sinuses but exact involvement and extent of disease can only be best judged on CT scan [1].

A study done on patients with chronic rhino sinusitis found that the most frequent symptoms were nasal obstruction; headache; nasal congestion and post nasal discharge. The nasal septums were significantly deviated and inferior turbinate hypertrophy was observed in patients [2]. Another study on chronic rhino sinusitis found that all the patients had more than one symptom with all of them presenting with nasal obstruction and nasal discharge [3]. One study done to evaluate differences in the frequency of symptoms and disease severity in patients with nasal septal deviation (NSD) compared with chronic rhino sinusitis (CRS) showed overall sin nasal symptoms were more prevalent in CRS

group with nasal congestion, runny nose, earache, toothache, and smelling disorder more common in the CRS group [4]. Another study done to examine the role of isolated nasal septal deviation (NSD) in the pathogenesis of chronic rhino sinusitis (CRS) showed that only gross deviation of the nasal septum was a risk factor for the development of CRS [5].

A study done to compare the rate of Sino nasal anatomical variations with development and severity of chronic rhino sinusitis patients showed septal deviation, concha bullosa, overpneumatized ethmoid bulla, pneumatised uncinate with no statistically significant difference between study and control group and no statistically significant correlation between Sino nasal anatomical variations and pathologies of the Para nasal sinus [6]. Another study CT-scan as a diagnostic modality for evaluating the Para nasal sinuses showed that septal deviation was the most common normal variation followed by agger nasi cell, concha bullosa, and hypo plastic frontal sinus with a strong association between the existence of Concha bullosa and septal deviation in the opposite directions [7].

A study done evaluate the important symptoms of patients undergoing functional endoscopic sinus surgery (FESS) showed that top three symptoms were postnasal drip, nasal obstruction, and facial congestion in terms of prevalence and severity; with an improvement in symptom scores following FESS [8]. Many studies have been done in different geographic areas have shown a varying pattern of symptoms of sinusitis [9]. A thorough literature search revealed that there are minimal studies done in this region, hence we considered it worthwhile to study the clinic therapeutic profile of patients with sinusitis and to find out the correlation of clinical profile with treatment.

## Material and Methods

This prospective, observational study was conducted on the patients visiting in department of Otorhinolaryngology in a Tertiary Care Hospital in North India suffering from sinusitis in a period of two months from June-July, 2014. 50 patients visiting in outpatients department with sinusitis were enrolled in the study after they gave written informed consent. The study protocol was approved by the Institutional Ethics Committee of the Institute prior to start of the study. All males and female patients more than 18 years of age coming to outpatients department with one of the following symptoms: onset with persistent symptoms, onset with severe symptoms and onset with worsening of symptoms were included in the study. Any patient with altered mental status, history of illegal drug use, history of radiations or chemotherapy and any co morbid medical or surgical disease were excluded from the study. Pregnant and lactating females were also excluded from the study.

## Procedure

Patients with nasal obstructions were evaluated with anterior rhinoscopy, diagnostic nasal endoscopy. The patients were evaluated for any anatomical malformations like DNS, concha bullosa paradoxical turbinate, inferior turbinate hypertrophy, nasal polypii etc. Further confirmation of diagnosis was done

using radiological investigation in the form of non-contrast CT scan Para nasal sinuses. Allergic tendencies of the patients were also noted.

## Statistical analysis

The data was tabulated as mean  $\pm$  standard deviation (SD). Results were analyzed using non parametric tests (Chi-Square Test), parametric tests (two tailed student t-test) and correlation (Pearson correlation coefficients) analysis. A  $p < 0.05$  was considered statistically significant.

## Observations and Result

In this study 50 patients were enrolled, the most common presenting clinical symptoms from the participants was nasal obstruction ( $n=48$ ) followed by nasal drip ( $n=42$ ), headache ( $n=36$ ) and sneezing ( $n=30$ ). A few of participants also reported complaints of facial pain ( $n=12$ ), hyposomia/ anosmia ( $n=11$ ), cough ( $n=10$ ) and fatigue ( $n=4$ ). The least common complaint was of fever which was found in 4 participants.

## Anatomical variations

Anterior rhinoscopy was done on all patients and the findings are presented in **Figure 1**. The most common observation seen in participants was deviated nasal septum, whereas the least common presentation in anterior rhinoscopy was inferior turbinate hypertrophy seen in 3 participants. Out of the 40 participants who had deviated nasal septum, 16 participants had right sided deviation and 24 had left sided deviation.

## Diagnostic tests

Diagnostic nasal endoscopy was done in all participants, 26 participants had positive finding in endoscopy, 23 of these participants had edematous nasal mucosa and three patients showed inferior turbinate hypertrophy. Plain radiograph of all the participants was done and revealed that 40 patients had deviated nasal septum

## Computerized tomography scan (CT scan)

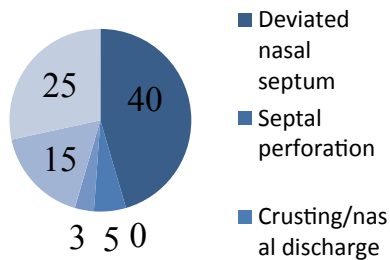
The CT scan findings of the participants is shown in **Figure 2**, the most common observation was sinusitis which was present in 16 participants, 8 participants had maxillary sinusitis, and 4 participants had sphenoidal sinusitis, frontal sinusitis and ethmoidal sinusitis each. Nasal polyposis was found in 15 participants, 12 out of these participants had bilateral ethmoidal polyposis and the rest had antrochoanal polyp.

## Treatment

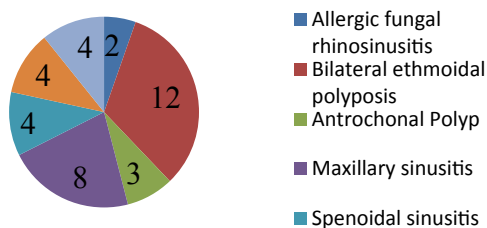
Septoplasty was done in 32 patients and functional endoscopic sinus surgery was done in 8 patients. Pharmacotherapy given to the participants is shown in **Figure 3**, 20 participants were on antibiotic followed by 16 on nasal decongestants, 14 on oral decongestants.

## Clinical symptom and treatment

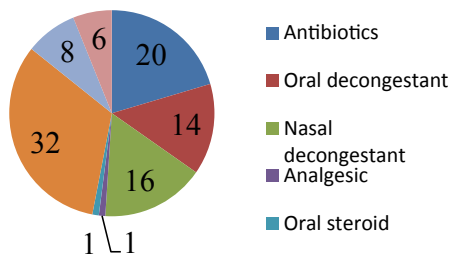
Septoplasty was done in 32 participants in which the most common symptoms was nasal obstruction in 28 participants



**Figure 1** Anterior Rhinoscopy finding in patients.



**Figure 2** CT scan finding in all patients.



**Figure 3** Treatment performed in patients.

, nasal discharge in 23 participants, sneezing 20 participants, headache 20 participants, DNS in 32 participants, hyposmia in 7 participants, and facial pain in 6 participants.

FESS was done in 8 participants in which most common symptoms was headache in 7 participants, facial pain in 5 participants, nasal obstruction in 6 participants, nasal discharge in 6 participants, sneezing in 3 participants. Antibiotics were given to 20 participants, common symptoms in them were nasal obstruction, nasal discharge in 20 participants, sneezing in 17 participants, and facial pain in 4 participants. Oral decongestants were given to 14 participants having common symptoms of nasal obstruction in 14 participants, nasal discharge in 12 participants, headache in 10 participants, sneezing in 9 participants, hyposmia in 2 participants, cough in 3 participants, fever in 1 participants, and facial pain in 3 participants. Nasal decongestant were given in 16 participants having common symptoms of nasal obstruction in 10 participants, nasal discharge in 8 participants, headache in 8 participants, sneezing in 5 participants, hyposmia in 2, and fever in one participants. The symptoms of nasal obstruction, nasal discharge and sneezing were significantly correlated with the treatment performed on patients (**Table 1**)

## Discussion

The results of our study have shown that the most common presenting clinical symptoms from the participants was nasal obstruction followed by nasal drip, headache and sneezing. Anterior rhinoscopy demonstrated that the most common observation seen in participants was deviated nasal septum and least common presentation was inferior turbinate hypertrophy. Diagnostic nasal endoscopy showed edematous nasal mucosa in more than 90% of patients, and plain radiograph revealed that 40 patients had deviated nasal septum. The CT scan findings showed most patients had sinusitis followed by nasal polyposis with septoplasty preferred in most patients. The symptoms of nasal obstruction, nasal discharge and sneezing were significantly correlated with the treatment performed on patients.

A study was done to evaluate differences in the frequency of symptoms and disease severity showed that nasal obstruction, postnasal drip, and smelling disorder were significantly more common in the CRS group [4]. The results of our study are quite similar as the most common symptoms were nasal obstruction, post nasal drip, headache and sneezing same as this study, but the complaints of anosmia/ hyposmia were minimal in our study.

Another study showed that all the patients presented with nasal obstruction and nasal discharge as most common symptom but fatigue, ear pain/ pressure/ fullness and dental pain were not that common [3]. Though like this study the presenting complaint in our study was also nasal obstruction and discharge but our study also showed that headache was also one of the common complaints along with sneezing. A study done by Buljick-Cupic, et al. showed deviation of nasal septum as common anatomical variation on anterior rhinoscopy with correlation between sinonasal disorder and anatomical variations [10]. The results of our study are quite similar as the most common anatomical variation was nasal septal deviation though patients also presented with inferior turbinate hypertrophy. One study revealed that septal deviation was most common anatomical variation and patients have more left sided deviation than right sided deviation [7]. The results of our study are quite similar as the most common presentation was nasal septal deviation and left sided was more common. Another study also showed inferior turbinate hypertrophy as common symptom [2], though there were report of inferior turbinate hypertrophy in our study but it was not the most common finding.

Few studies done to assess the incidence of fungal rhinosinusitis reported an overall incidence of 7.3% among patients suffering from rhinosinusitis in CT scan, our study also reported 2 patients with allergic fungal rhinosinusitis in CT scan [11]. CT scan finding showed involvement of sinus with maxillary sinus being the most commonly involved followed by anterior and posterior ethmoidal sinus, frontal sinus and sphenoid sinus in a study [3]. In our study also CT scan showed sinusitis as most common finding with maxillary sinus being most commonly involved followed by ethmoidal, sphenoidal and frontal sinusitis.

A number of studies done for treatment of sinusitis demonstrated that septoplasty alone was adequate and effective for treatment

**Table 1:** Correlation of treatment with symptoms.

Treatment	Nasal Obstruction	Nasal Discharge	Sneezing	Headache	DNS	Hyposmia	Facial Pain	Cough	Fever
<b>Septoplasty (n=32)</b>	28	23	20	20	32	7	6		
<b>FESS(n=8)</b>	6	6	3	7			5		
<b>Antibiotics (n=20)</b>	20	20	17				4		
<b>Oral Decongestants (n=14)</b>	14	12	9	10		2	3	3	1
<b>Nasal Decongestants (n=16)</b>	10	8	8	5		2			1
	r=0.96	r=0.90	r=0.93	r=0.88	Not done	r=0.99	r=0.53	Not done	Not done
	p<0.05*	p<0.05*	p<0.05*	p>0.05		p>0.05	p>0.05		

\*p<0.05 using Pearson correlation coefficients

of sinusitis with deviated septum [12,13]. In present study also majority of patients preferred septoplasty and was effective in treatment of symptoms.

There are certain limitations in our study, firstly the sample size is small, a larger sample size could have given different results, as this study was to conducted over a period of two months hence that was not possible. Secondly, the duration of study was small as it was a sponsored study and had to be completed in two months.

To conclude in the present study most common symptoms were nasal obstruction, post nasal drip, headache and sneezing. Most common anatomical variation was septal deviation. Patients had

more left sided septal deviation. The maxillary sinus was the most commonly involved followed by ethmoidal sinus, frontal sinus and sphenoidal sinus. In the treatment septoplasty alone was adequate for treatment of sinusitis with deviated septum.

## Source of Funding

This projects is a part of ICMR-STs (Indian Council of Medical Research-Short term Studentship Program) 2014. The project has been supported by ICMR-STs 2014 program.

## Conflict of Interest

Authors declared no conflict of interest.

## References

- 1 Sood VP (2011) Chronic rhinosinusitis. ECAB Clinical Update: Otorhinolaryngology. (1stedn) Elsevier Health Sciences, pp. 75-83.
- 2 Madani SA, Hashemi SA, Javan S, Hoseini AA (2014) Anatomical variants, clinical presentation and pathological finding in patients suffering from chronic rhinosinusitis underwent functional endoscopic sinus surgery. Int J Med Med Sci 6: 190-194.
- 3 Amodu EJ, Fasunla AJ, Akano AO, Olusesi AD (2014) Chronic rhinosinusitis: correlation of symptoms with computed tomography scan findings. The Pan African Medical Journal 18: 40.
- 4 Naeimi M, Garkaz M, Naeimi MR (2013) Comparison of sinonasal symptoms in patients with nasal septal deviation and chronic rhinosinusitis. Iranian Journal of Otorhinolaryngology 25: 11-16.
- 5 Yasan H, Doğru H, Baykal B, Döner F, Tüz M (2005) What is the relationship between chronic sinus disease and isolated nasal septal deviation? Otolaryngol Head Neck Surg 133: 190-193.
- 6 Kaygusuz A, Haksever M, Akduman D, Aslan S, Sayar Z (2014) Sinonasal anatomic variation: their relationship with chronic rhinosinusitis and effect in the severity of disease – a computerized tomography assisted anatomical and clinical study. Indian Journal of Otolaryngology and Head & Neck Surgery 66: 260-6.
- 7 Daghighi M, Daryani A, Nejad KC (2006) Evaluation of anatomical variations of paranasal sinuses. The Internet Journal of Otorhinolaryngology, 7.
- 8 Ling FT, Kountakis SE (2007) Important clinical symptoms in patients undergoing functional endoscopic sinus surgery for chronic rhinosinusitis. Laryngoscope 117: 1090-1093.
- 9 Poorey VK, Gupta N (2014) Endoscopic and computed tomographic evaluation of influence of nasal septal deviation on lateral wall of nose and its relation to sinus disease. Indian Journal of Otolaryngology and Head & Neck Surgery 66: 330-335.
- 10 Buljick-Cupić MM, Savović SN, Jovičević JS (2008) Influence of anatomic variations of the structures of the middle nasal meatus on sinonasal diseases. Med Pregl 61: 135-141.
- 11 Satish HS, Alokkan J (2013) Clinical Study of Fungal Rhinosinusitis. ISOR Journal of Dental and Medical Sciences 5: 37-40.
- 12 Poachanukoon O, Nanthapaisal S, Chaumrattanakul U (2012) Pediatric acute and chronic rhinosinusitis: comparison of clinical characteristics and outcome of treatment. Asian Pac J Allergy Immunol 30: 146-51.
- 13 Nawaiseh S, Al-Khtoum N (2010) Endoscopic septoplasty: retrospective analysis of 60 cases. J Pak Med Assoc 60: 796-8.