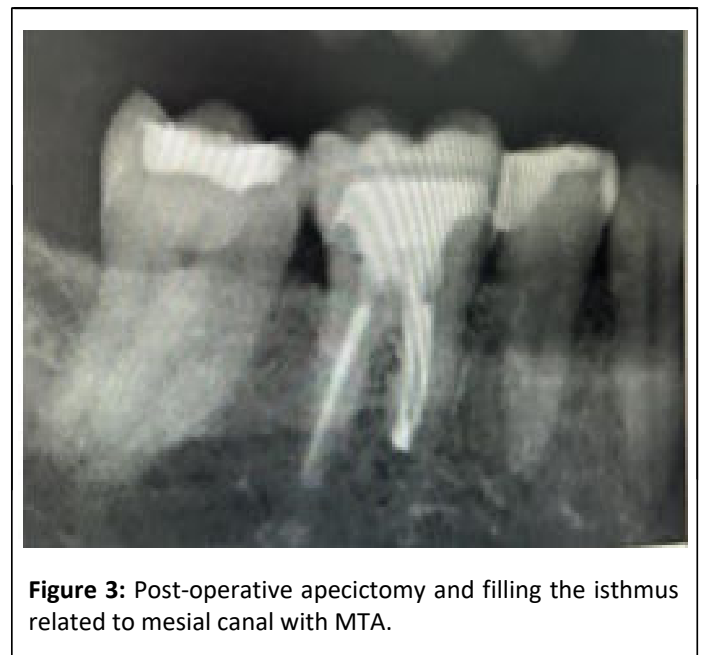
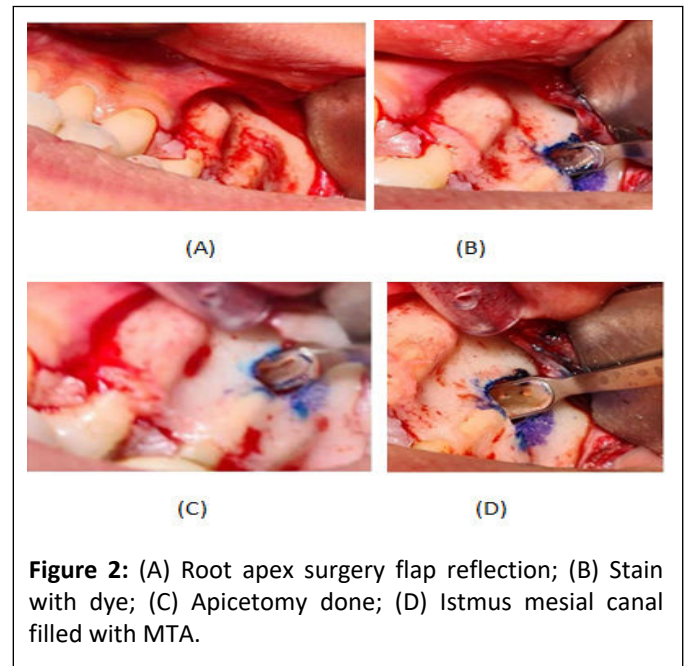
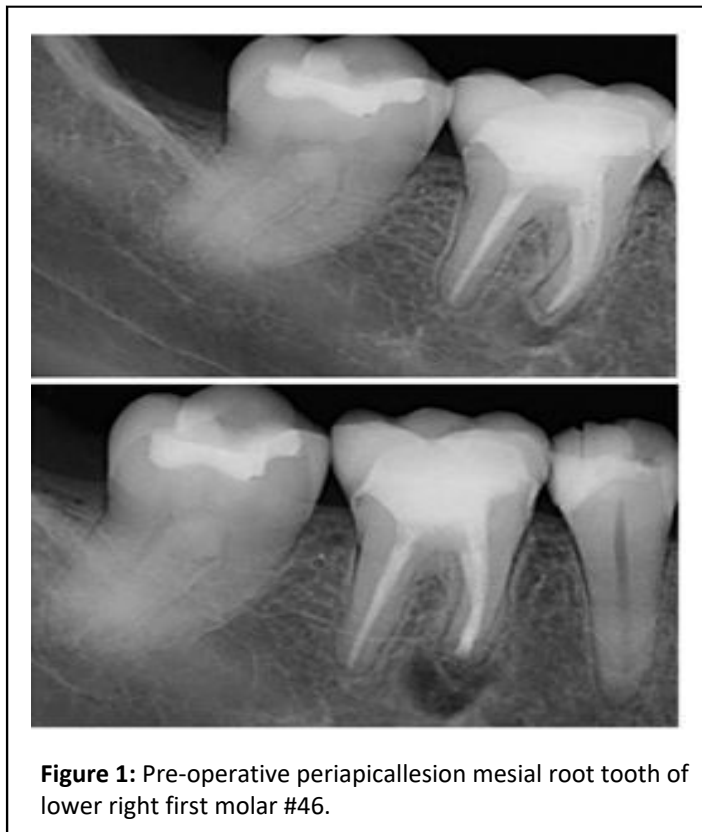



present in premolars and molars at the 3 mm level from the apex in about 80% to 90% of instances when undertaking apical surgery [4]. And the incidence of isthmus failure in mandibular first molar as shown in von Arx T, et al. study was 83%.

## Case Presentation

38 years old female, medically fit, came to Princes Sultan Military Medical City (PSMMC) primary care dental center complaining from slightly discomfort related to lower right area when blending her foundation makeup by beauty blender. After examination tooth #46 is endodontically treated tooth 10 years ago with excellent obturation and there is Symptomatic Apical Periodontitis (SAP). The endodontist decided to do exploratory surgery to check the reason. He found missing apical isthmus related to mesial canal. Apicectomy done and the isthmus closed with MTA (Figures 1-3).



## Discussion

The intricate anatomical nature of the root canal is one of the root canal treatment's challenges. Anatomic complexity is made up of many different components, such as the fin and lateral canal, and isthmuses in particular present difficulties for endodontists [5]. No precise technique for cleaning and shaping an isthmus has yet been developed, despite the fact that numerous preparation and irrigation procedures have been presented to get around the anatomical complications. The dental operating microscope, ultrasonic, modern microsurgical equipment, and biocompatible root-end filling materials are some of the technological advancements used in modern microsurgical periradicular surgery, which has produced highly successful treatment outcomes.

The increased success rates were attributed to a superior surgical site examination and the exact preparation of root-ends with micro-instruments using high magnification and improved illumination. In order to create a cavity that can be effectively filled during root end resection surgery, root-end preparation tries to remove filling material, irritants, necrotic tissue, and residues from the canals and the isthmus. The optimal root-end preparation is a class I cavity with walls parallel to and inside the anatomic shape of the root canal space that extends at least 3 mm into the root dentin. The prevalent practice in conventional surgical procedures, the use of rotating burs in a micro-handpiece, is no longer able to provide this therapeutic need. The brand or kind of tip is not clinically significant for an effective ultrasonic preparation, but rather how the tip is used. The secret to successful ultrasonic preparation is to repeatedly apply very little pressure. A softer touch improves cutting efficiency, whereas continuous pressure, as that applied by a handpiece, reduces cutting effectiveness. This is so that ultrasound can operate through vibration rather than pressure.

To increase the success rates of endodontic microsurgery for posterior teeth, an isthmus must be identified and treated. A missed isthmus, can result in failure [6]. According to Sunil Kim, et al., isthmus-present teeth had a worse success rate for endodontic microsurgery than isthmus absent teeth did. The complexity of the isthmus preparation method itself is one of the causes of the significantly lower success rate in teeth with isthmus presence. In comparison to teeth with an absent isthmus, teeth with an extant isthmus must be more weakened in order to create space for a root canal. This lowers the success rate of the surgery [7]. At the short-term follow-up after one year and the long-term follow-up after five to seven years, the clinical success of cases treated with microsurgery is reported to be as high as 96.8% and 91.5%, respectively. Similar findings have been revealed by recent prospective studies with long-term follow-up [8].

## Conclusion

Even with good endodontic treatment missing isthmus can be found and cause failure of treatment. As studies shown microsurgery is predictable and effective treatment for this mishap.

## References

1. Siqueira JF Jr (2001) Aetiology of root canal treatment failure: Why well-treated teeth can fail. *Int Endod J* 34:1-10
2. Friedman S (2011) Outcome of endodontic surgery: A meta-analysis of the literature—part 1: comparison of traditional root-end surgery and endodontic microsurgery. *J Endod* 37:577-578
3. Kratchman SI (2007) Endodontic microsurgery. *Compend Contin Educ Dent* 28:399-405
4. Floratos S, Kim S (2017) Modern endodontic microsurgery concepts: A clinical update. *Dent Clin North Am* 61:81-91
5. von Arx T (2005) Frequency and type of canal isthmuses in first molars detected by endoscopic inspection during periradicular surgery. *Int Endod J* 38:160-168
6. Kim S, Jung H, Kim S, Shin SJ, Kim E (2016) The influence of an isthmus on the outcomes of surgically treated molars: A retrospective study. *J Endod* 42:1029-1034
7. Setzer F, Harley M, Cheung J, Karabucak B (2021) Possible causes for failure of endodontic surgery—A retrospective series of 20 resurgery cases. *Eur Endod J* 6:235-241
8. Tabassum S, Khan FR (2016) Failure of endodontic treatment: The usual suspects. *Eur J Dent* 10:144-147