



Case Report

An Extra - Stomodeul Location of Tooth Causing Epistaxis – Role of Dental Surgeon

Shabnam Zahir, Sudipta Kar*, Pratik Kumar Lahiri and Subrata Sarkar

Guru Nanak Institute of Dental Science & Research, India

ARTICLE INFO

Received 17 Aug. 2015
Received in revised form 30 Aug. 2015
Accepted 05 Sep. 2015

Keywords:

Stomodeum,
Epistaxis,
Tooth,
Nasal.

Corresponding author: 21F, Charakdanga Road, Uttarpara, Hooghly - 712258, West Bengal, India

E-mail address:
dr.sudiptakar@yahoo.com

ABSTRACT

The persistence of tooth outside stomodeum i.e. oral cavity is a rare phenomenon which may cause different problems due to its unusual location. As a dental surgeon we regularly have faced intraoral bleeding, on the other hand epistaxis is a common disorder in children that is frequently manifested by bleeding from nose due to irritation in the nasal mucosa commonly faced by the ENT specialist. Common causes of manifestation of epistaxis may be local inflammatory diseases of the nose, infections, vascular malformations, and trauma. We have reported a case of recurrent epistaxis due to an ectopic tooth in the nasal cavity in this article. In this case ENT specialist has referred this case to us for proper evaluation.

Introduction

Extrastomodeul position of teeth is an unusual phenomenon. The presences of teeth have been reported in ovaries, testes, anterior mediastenum, presacral region, maxillary sinus, chin, nose and even orbit. Approximately fifty reported cases of a tooth in nasal cavity had been reported.¹⁻³

In general, cases of intranasal tooth in surgically repaired cleft lip and cleft palate are comparatively rare, intra nasal

canine tooth in repaired cleft lip and cleft palate being rarer. The prevalence of intranasally erupted tooth in unilateral and bilaterally developed cleft palate is 0.40% & 0.61% respectively. Till date only few cases of intra nasal tooth with repaired cleft lip and repaired palate had been reported.⁴ Etiology behind intranasal eruption of tooth is not very clear. Incomplete union of embryonic processes may be regarded as



one of the causes behind intranasal displacement of tooth bud.¹ Surgical procedure associated with repair of developmental cleft lip or palate may further accentuate the intranasal displacement of tooth bud. It may be manifested with different varieties of symptoms like nasal obstruction, recurrent sinusitis, headache, asymptomatic etc or may be rarely epistaxis.

Case Report

A nine years of age bengali girl child was referred to the Department of Pedodontics and Preventive Dentistry, Guru Nanak Institute of Dental Sciences & Research, Kolkata from the Institute of Child Health with a complain of the presence of a hard structure near the nostril. Patient did not complain any other associated symptoms except occasional bleeding from nose on slight provocation. Patient first consulted with an ENT specialist and he discovered the hard substance within nose and referred the patient to our department. Medical history revealed that the girl child was a preterm baby delivered by surgical caesarean section. At birth she had bilateral cleft lip and cleft palate. Bilateral cleft lip was surgically repaired at 6 months of age and cleft palate was surgically repaired by two consecutive surgeries. At the age of 1 year, palatoplasty was done and revision of cleft lip was again performed at an age of 8 years. The patient is the second child of a lower middle class Bengali family without any reported familial incidence of cleft lip and cleft palate. Extra oral examination reveals short mid facial height along with depressed left ala of nostril. Facial profile was concave and a bilateral scar mark was present on philtrum of lip. Tip of tooth was visible in the left nostril (Fig - 1). Orthopantomogram revealed mixed dentition along with septal perforation due to canine tooth in nasal cavity (Fig- 2).

Management

After thorough clinical, hematological and radiographical examination, the extrastomodeul tooth was planned to be extracted under Local anesthesia. Anterior superior nerve block, anterior palatine nerves block and infra orbital nerve block on the left side was given with 4 C.C. of 2% xylocaine HCL with adrenaline. One end of 3- 0' black thread was tied up with nasally erupted tooth and other end of the thread was outside the oral cavity to prevent slippage of tooth (Fig – 3). Extraction of nasally erupted tooth was done by forceps method. Suturing was done through nasal aspect (Fig – 4) after extraction, antibiotics, nasal drops and post operative instructions were given. Sutures were removed after 7 days. Extracted tooth was 19 mm in length and its shape resembled a canine tooth, so the extracted intranasal tooth is a supernumerary deciduous canine as deciduous canine is erupted and developing permanent canine is visible in the radiograph.

Discussion

Extrastomodeul eruption of tooth in nasal cavity in cleft lip and cleft palate is a rare and unusual phenomenon .Till date, only a few such cases have been published by various investigators.⁵⁻⁹ The extrastomodeul eruption of teeth occurs in a varies locations such as maxillary sinus,³ orbit,⁴ and nasal cavity.⁶⁻⁹ Exact true etiology of nasally erupted tooth in cleft palate and cleft lip case is not well understood. One group of author conveyed that incomplete union of embryonic processes may be one of the causes of ectopic eruption of tooth. According to some, surgical repair of cleft palate and lip may occasionally displace the developing tooth bud within the nasal cavity.⁶ Intranasal teeth can be permanent deciduous or may be of supernumerary in origin. Case reports had

indicated that most intranasal teeth appear as a unilateral single tooth in the nasal cavity, rather than multiple teeth in the nose, or teeth in both nasal cavities.¹⁰ The underlying etiology remains indefinite but the literature mentions different causes of intranasal tooth development that include cleft palate, maxillofacial trauma, previous odontogenic infection, and hereditary factors including Gardner's syndrome and cleidocranial dysostosis. Intranasal teeth manifest a variety of symptoms that include the sensation of a foreign object¹² in the nose, unilateral nasal obstruction,¹¹ purulent discharge from nose, bloodstained rhinorrhea,³ and repeated epistaxis. Nasal or facial pain,¹³ headache nasolacrimal duct obstruction.¹⁴ Intranasal teeth may also be asymptomatic and identified incidentally on a routine radiographic or clinical examination. Clinically, intranasal teeth occur most commonly on the floor of the nose. The removal of nasal teeth may be done under direct vision with headlight illumination but the endoscopic approach is recommended by ENT specialists because of good illumination, proper visualization, accurate dissection and minimum injury to nasal mucosa.^{15,16} in our case we took the help of dental halogen light for proper illumination. The tooth may be embedded in the nasal mucosa surrounded by debris, ulcerative materials, and granulation tissues as a result of which a differential diagnosis should be formulated. The differential diagnoses may be foreign body; rhinolith; inflammatory lesions due to syphilis, tuberculosis, or fungal infection with calcification; benign cyst and tumors like dermoid cysts, hemangioma, osteoma, calcified polyps, and enchondroma, as well as malignant tumors like chondrosarcoma and osteosarcoma. Erupted extrastomodeul hard white mass without nasal mucosal covering resembled tooth made our diagnosis straightforward.

Conclusion

Diagnosis of extra - stomodeul location of tooth is often a challenge to the stomatologist. Dental surgeons and ENT specialists are commonly faced different problems involving oro nasal, oro antral, temporomandibular joint and associated structures. Combined or inter disciplinary approach may be help full in diagnosis of different complicated problems like our case.

Acknowledgement

Department of Pedodontics & Preventive Dentistry, Guru Nanak Institute of Dental Sciences & Research, Kolkata - 114

References

1. Gupta YK, Shah N. Intranasal tooth as a complication of cleft lip and alveolus in a four year old child: a case report and literature review. *Int J Paediatr Dent.* 2001; 11(3):221-4.
2. Rao A. B. N. Aberrant canine tooth in the nose. *Journal of Laryngology.* 1953; 67:370-371.
3. Hiranandani LH, Melgiri RD. Supernumerary tooth in the nose. *J Laryngol Otol* 1968; 82: 845-8.
4. Medeiros AS, Gomide MR, Costa B, Carrara CF, das Neves LT. 2000. Prevalence of intranasal ectopic teeth in children with complete unilateral and bilateral cleft lip and palate. *Cleft Palate Craniofac J* 37: 271-273.
5. Endicott, C.L. A case of a supernumerary incisor erupting into the nose. *Br Dent J.* 1934; 56:385-386.
6. King NM, Lee AMP. An intranasal tooth in a patient with a cleft lip and palate:report of case. *J Am Dent Assoc.*1987; 114:475-478.
7. Ranalli DN, McWilliams BJ, Gorrett WS Jr. Tooth and foreign object in nasal fossa of a child with cleft: case report. *Pediatr Dent* 1990; 12:183-4.

8. Ranalli, D.N. Intranasal tooth in a patient with cleft lip and alveolus. *Cleft Palate Craniofac J.* 1996; 33:530.
9. Yeung, K.H., Lee, K.H. Intranasal tooth in a patient with a cleft lip and alveolus. *Cleft Palate Craniofac J.* 1996; 33:157-159.
10. Kakade A, Gandhi MM, Damle SG. Management of nasally erupting deciduous canine in operated cleft lip and alveolus patient. *J Indian Soc Pedod Prev Dent.* 2006 Mar; 24(1):40-1.
11. Hirschler WJ. Nasal teeth. *Arch Otolaryngol* 1938; 28: 911-25.
12. Bertrand L. Dent Surnumeraire dans les fosses nasales. *Canad Dent Assoc J* 1964; 30: 217-72.
13. Chopra SS, Joshi MR. Mesiodens erupted in the nasal cavity. *J Oral Surg.*1969; 28:856-858.
14. Alexandrakis G, Hubbell RN, Aitken PA. Nasolacrimal duct obstruction secondary to ectopic teeth. *Ophthalmology.* 2000; 107:189-92.
15. Lee FP. Endoscopic extraction of an intranasal tooth: a review of 13 Cases. *Laryngoscope* 2001; 111:1027-31.
16. Spencer MG. Couldery AD. Nasal tooth. *J Laryngol Otol* 1985; 99:1147-50.

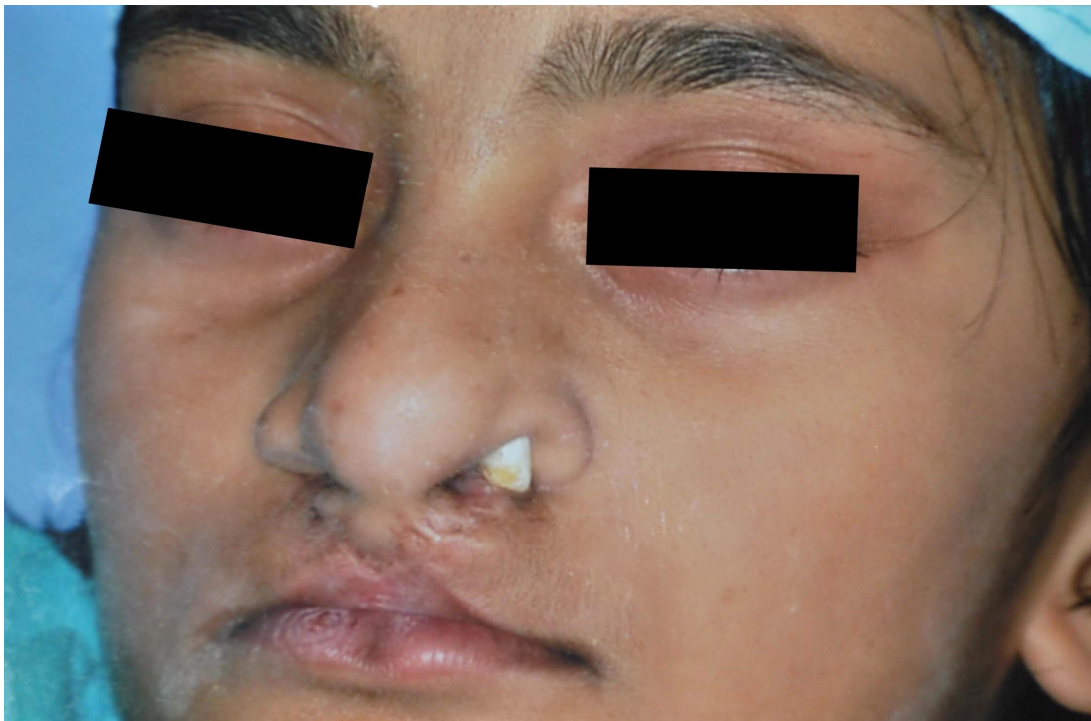

Figure 1: Pre-operative Extra oral view

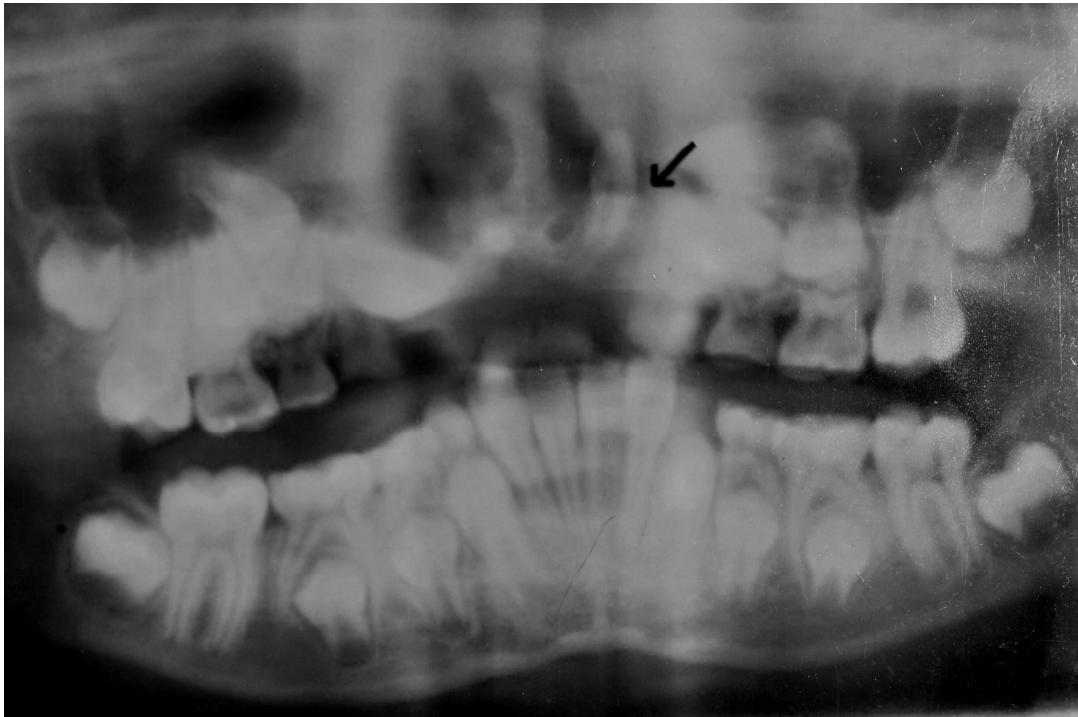


Figure 2: Orthopantomogram

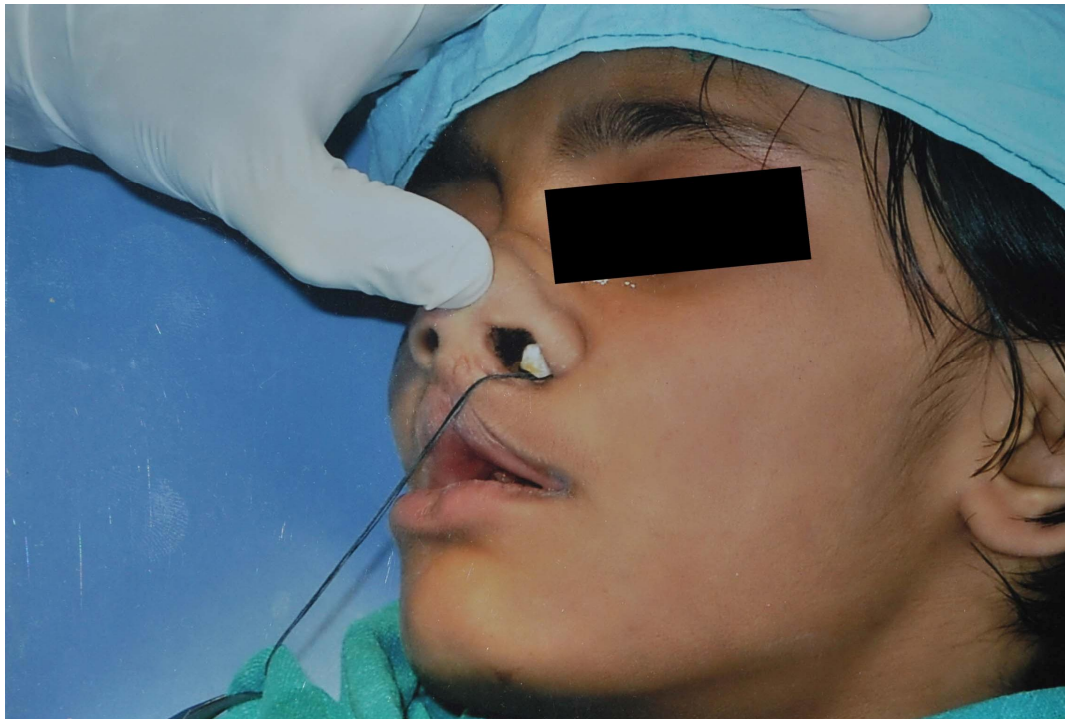

Figure 3: Pre extraction procedure

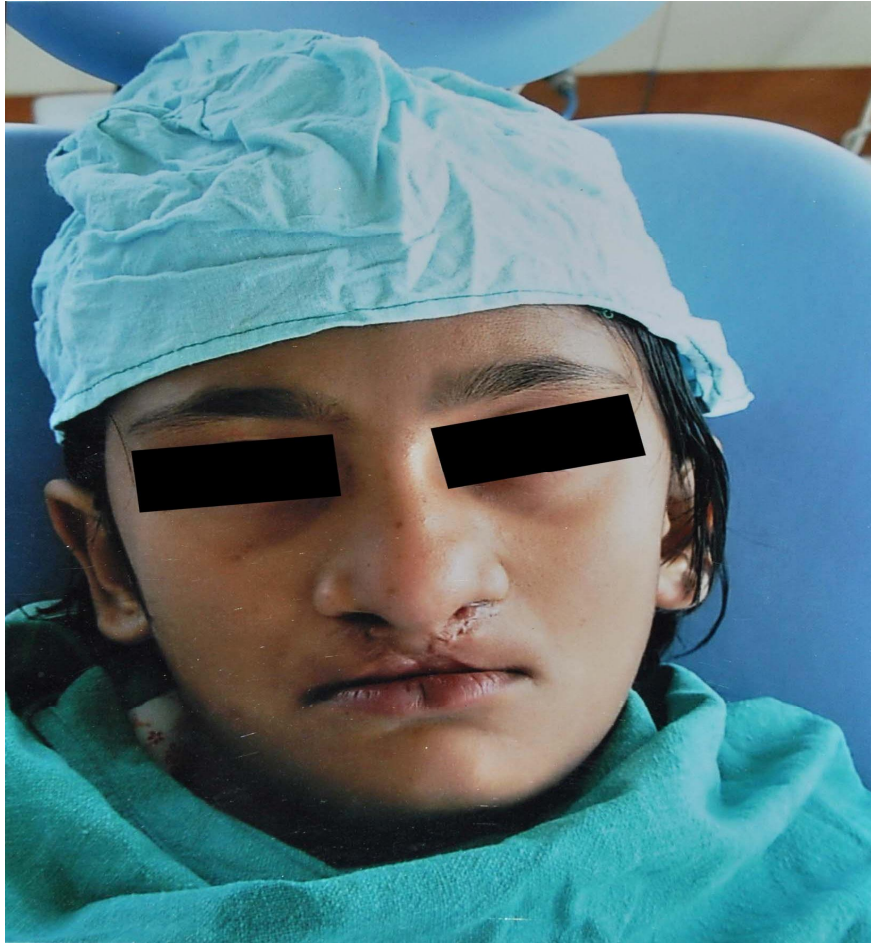

Figure 3: Post operative extra oral view