

Myringotomy as a Diagnostic and Therapeutic Tool in a Case of Otitis Media in a Guinea Pig (*Cavia porcellus*)

Householder HM, Berger DJ, Noxon JO and Zaffarano BA*

Department of Veterinary Clinical Sciences, Iowa State University, 1800 Christensen Drive, Ames, IA 50011, USA

Abstract

A 1.5 year old male adult guinea pig (*Cavia porcellus*) presented with acute vestibular disease, consisting of a right head tilt, circling, and ataxia. The head tilt was non-responsive to initial empirical antimicrobial therapy for presumptive otitis media. Video otoscopy and a myringotomy were performed under general anesthesia. A large amount of purulent debris was flushed from the middle ear and submitted for culture. Treatment with appropriate systemic and topical antibiotics was pursued for 4 weeks. Near complete resolution of clinical signs was achieved by the end of treatment with only a minor residual head tilt. This is the first described use of a diagnostic and therapeutic myringotomy for the treatment and resolution of otitis media in a guinea pig. Based on the clinical success seen in this case and the relative ease of the procedure, myringotomies should be considered for diagnosis and treatment of otitis media in guinea pigs.

Keywords: Guinea pig; *Cavia porcellus*; Myringotomy; Otitis media

Received: December 21, 2017; **Accepted:** January 08, 2018; **Published:** March 10, 2018

Case Report

Otitis media and subsequent otitis interna associated with *S. pneumoniae*, *B. bronchiseptica*, *S. zooepidemicus*, and *P. aeruginosa* have been previously reported in guinea pigs [1,2]. Otitis media is commonly associated with dental disease and oral flora is often isolated from the ear, indicating a possible opportunistic infection via the eustachian tube secondary to dental disease [3]. Clinical signs associated with otitis media and interna in guinea pigs include head tilt, ataxia and circling, torticollis, and facial nerve paralysis with secondary ulcerative exposure keratitis [3]. A full work-up including radiography or computed tomography is recommended to rule out other causes of vestibular signs such as trauma, cerebrovascular disease, toxicity, brain abscesses, and concurrent dental disease [1,3]. Common treatment protocols for otitis in guinea pigs include antibiotics, anti-inflammatories, analgesics, treatment of concurrent dental disease, and/or flushing of the external ear canal under sedation [3].

Video otoscopy is a useful tool in both the diagnosis and treatment of otic diseases in companion animals. It is particularly useful in small exotic companion mammals where conventional handheld otoscopes may be too large for the external ear canal, preventing

visualization to the level of the tympanic membrane. Video otoscopy can allow for procedures such as foreign body removal, intralesional drug administration, and sample collection via biopsy or myringotomy [4]. Myringotomies are commonly used in general small animal practice to obtain samples for cytology and culture as well as to relieve pressure and subsequent discomfort due to the accumulation of fluid and other inflammatory material within the tympanic bulla [5,6]. Possible complications following a myringotomy and ear flush include transient to permanent Horner's syndrome, facial nerve paralysis, vestibular disease, and deafness [7].

A 1.5 year old adult male guinea pig (*Cavia porcellus*) presented for an acute onset of a right-sided head tilt, circling, and ataxia. Initial physical exam revealed a head tilt to the right and mild proprioceptive deficits in the rear legs (**Figure 1**). The remainder of the physical exam was unremarkable and the guinea pig had a good body condition score of 3/5 [8]. No obvious dental abnormalities were noted in the oral cavity on an un-sedated oral examination. A complete blood count (CBC) and chemistry panel were submitted, but clotting artifact precluded the CBC results. The chemistry panel was unremarkable. Primary differential diagnoses included otitis media/interna versus primary central

*Corresponding author:

Bianca Zaffarano

✉ bazaff03@iastate.edu

Department of Veterinary Clinical Sciences, Iowa State University, 1800 Christensen Drive, Ames, IA 50011, USA.

Tel: 515-294-4900

Citation: Householder HM, Berger DJ, Noxon JO, Zaffarano BA (2018) Myringotomy as a Diagnostic and Therapeutic Tool in a Case of Otitis Media in a Guinea Pig (*Cavia porcellus*). J Vet Med Surg. Vol. 2 No. 1:18.



Figure 1 Clinical photograph, right tympanic membrane with opaque discoloration.



Figure 2 Clinical photograph, left tympanic membrane.

nervous system disease. Diagnostic imaging was recommended, but declined in favor of empirical treatment for otitis media. The patient was started on sulfamethoxazole-trimethoprim (Aurobindo, East Windsor, New Jersey, 08520, 15 mg/kg PO, BID for four weeks).

The patient was presented for reevaluation three weeks later. There was no change in the previously noted head tilt and ventromedial strabismus of the right eye was now present (**Figure 2**). The remainder of the physical exam was unremarkable. A brief otic exam with a video-otoscope (Hopkins II Karl Storz Endoskope Video Otoscope, Tuttlingen, Germany) was performed revealing a clear intact tympanic membrane on the left side, while a bulging, opaque, erythemic tympanic membrane was appreciated on the right. Otic cytology was performed and revealed low numbers of *Malassezia* spp. bilaterally. Further diagnostic options including a CT scan and/or a myringotomy were recommended, but the owner elected to pursue only myringotomy due to financial constraints. Systemic antibiotic therapy was discontinued for 5 days prior to the procedure to reduce the risk of a false negative culture and the patient was started on meloxicam for pain (Metacam, Boehringer Ingelheim, Ridgefield, Connecticut, 06877, 0.5 mg/kg PO, SID).

The patient represented for a myringotomy under general anesthesia. Anesthesia was induced with midazolam (West-Ward, Eatontown, New Jersey, 07724, 1.0 mg/kg IM), ketamine (Vet One, Boise, Idaho, 83705, 3.0 mg/kg IM) and butorphanol (Zoetis Inc., Parsippany, New Jersey, 07054, 1.0 mg/kg IM) and the patient was maintained on flow-by oxygen. The patient was placed in sternal recumbency with the head slightly elevated to facilitate respiration and tilted to allow easier access into the external ear canal. A video otoscope was passed into the external aural canal of the left ear and the canal was lightly flushed and cleaned with sterile saline using a 20 cc syringe and tomcat catheter via the working port. The tympanum was visualized and determined to be intact (**Figure 3**). The patient was repositioned and the right aural canal was evaluated in a similar manner to the left. After flushing with sterile saline to remove debris, the right tympanic membrane was visualized to be opaque and bulging, with increased prominence of vasculature (**Figure 4**). The tip of a sterile tomcat catheter was angled using a #10 scalpel blade and introduced into the external ear canal via the working port. The sterile catheter was used to pierce the tympanic membrane and 0.5 ml sterile saline was flushed into the middle ear and then

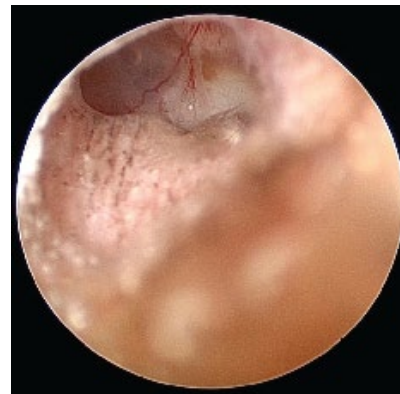


Figure 3 Clinical photograph, right ventromedial strabismus.

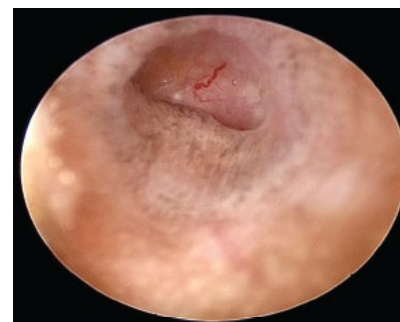


Figure 4 Clinical photograph, right sided head tilt in a guinea pig (*Cavia porcellus*).

aspirated along with the middle ear contents. Upon puncturing the tympanic membrane, purulent exudate was observed exuding from the middle ear. A drop of the aspirated sample was placed on a slide for cytological evaluation and the remainder was submitted for culture and sensitivity. Cytology of the fluid from the middle ear revealed numerous degenerate neutrophils along with intracellular and extracellular Gram-positive coccoid shaped bacteria. Flushing of the external ear canal and middle ear was continued until clear fluid was observed coming from the middle ear. An additional 60 mLs of sterile saline was used to flush the ear. Following cleaning, the saline was evacuated from the aural canal and middle ear via suction and a topical solution of enrofloxacin (Baytril, Bayer, Whippany, New Jersey, 07981,

0.25 ml) and dexamethasone SP (Vet-One, Boise, Idaho, 83705, 0.25 ml) was infused into the middle ear. The patient recovered from anesthesia without complication.

Topical therapy via instillation of 0.1 mLs of enrofloxacin/silver sulfadiazine otic drops (Baytril Otic, Bayer 0.1 ml AD, SID) was started pending the bacterial culture and sensitivity results. The meloxicam was continued for post-procedure analgesia for five days. The bacterial culture revealed a heavy growth of *Streptococcus pneumoniae* from the middle ear. Based on the sensitivity results, the patient was started on marbofloxacin (Iowa State University, Ames, IA 50011, 4 mg/kg PO, SID for four weeks) and the topical drops were continued. A recheck exam 10 days post-procedure revealed marked improvement in the inflammation of the external ear canal and a moderate amount of waxy build up over the tympanum. The head tilt was subjectively more severe, but the right sided ventromedial strabismus was no longer present. A recheck exam 24 days post-procedure revealed near resolution of the head tilt and the guinea pig had resumed all normal behaviors per the owner. Long-term follow-up via conversations with the owner revealed continued relief of clinical signs and no observed complications.

This report describes the first documented case of a myringotomy utilized as a diagnostic and therapeutic procedure in a guinea pig. Myringotomies have been previously described in guinea pigs used as an animal model in evaluation of therapeutics for human medicine. Myringotomies are routinely used in canine and feline patients for diagnostic and therapeutic purposes. In this case, a large amount of purulent material was removed from the middle ear and post-procedure the patient seemed more comfortable and had an improved appetite. The head tilt never fully resolved in this patient, but the neurologic signs associated with otitis media and otitis interna are often the last clinical signs to resolve and on occasion may be permanent [5]. Diagnostic imaging could have been useful in this case to rule out other pathology beyond the middle ear that may have been contributing to the neurologic signs. Given the response to therapy and continued resolution of clinical symptoms in this case, a second disease process is unlikely.

S. pneumoniae affects a wide variety of animals, but guinea pigs are particularly susceptible to clinical infections [9]. Clinical infections with *S. pneumoniae* in guinea pigs have been documented in upper respiratory tract infections, meningitis, otitis, metritis, and bronchopneumonia [9]. Treatment must be carefully considered in guinea pigs due to their susceptibility to antibiotic induced

bacterial overgrowth and subsequent dysbiosis [9]. The use of culture and sensitivity driven antibiotic therapy is important in guinea pigs due to the limited number of antibiotics available for oral use. A myringotomy is a straight forward procedure that can be performed in guinea pigs to allow sample collection.

In summary, this procedure was simple and efficient to perform under general anesthesia and yielded useful diagnostic samples while providing symptomatic relief. As a result, myringotomies should be considered in cases of otitis media in guinea pigs to help obtain diagnostic samples and hasten clinical resolution. While no direct complications as a result of this procedure were noted during follow-up, further evaluation of this procedure in the guinea pig is needed to determine if they have similar complication rates to other veterinary patients.

References

- 1 Minarikova A, Hauptman K, Knotek AJE, Jekl V (2015) Diseases in pet guinea pigs: a retrospective study in 1000 animals. *Vet Rec*, pp: 177-200.
- 2 Barthold SW, Griffey SM, Percy D (2016) Guinea Pig Bacterial Infections. In: *Pathology of Laboratory Rodents and Rabbits*. Ames (IA): Wiley-Blackwell, United States.
- 3 Hawkins MG, Bishop CR (2012) Disease Problems of Guinea Pigs. In: Quesenberry KE, Carpenter JW (eds.), *Ferrets, Rabbits and Rodents Clinical Medicine and Surgery*. Elsevier, St. Louis, MO, USA.
- 4 Jekl V, Hauptman K, Knotek Z (2015) Video Otoscopy in Exotic Companion Mammals. *Veterinary Clinics of North America: Exotic Animal Practice* 18: 431-445.
- 5 Shell LG (1988) Otitis Media and Otitis Interna: Etiology, Diagnosis, and Medical Management. *Veterinary Clinics of North America: Small Animal Practice* 18: 885-899.
- 6 Cole LK, Podell M (2008) Diseases of the Middle and Inner Ear. In: Morgan RV (ed.), *Handbook of Small Animal Practice*, Elsevier, St. Louis, MO, USA.
- 7 Cole LK (2004) Otoscopic evaluation of the ear canal. *Veterinary Clinics of North America: Small Animal Practice* 34: 397-410.
- 8 Ara GM, Jimenez Huaman CA, Cercelen CF, Diaz CD (2012) Development of a body condition score in guinea pigs: relationships between body condition and quantitative estimates of body fat. *Revista de Investigaciones Veterinarias del Perú* 23: 420-428.
- 9 Harkness JE, Turner PV, VandeWoude S, Wheler CL (2010) *Streptococcus pneumoniae* Infections in Rodents. In: *Harkness and Wagner's Biology and Medicine of Rabbits and Rodents*. Ames (IA): Wiley-Blackwell, United States.