

Impact of supplemental zinc on pathology of heart in broiler chicks

Sabina Khanam*¹, Vijay Laxmi Saxena¹ and Amita Dixit²

¹*Department of Zoology, D.G. College, Kanpur*

²*Department of Zoology, D. A. V. College, Kanpur*

ABSTRACT

This experiment was conducted to evaluate the impact of zinc supplementation on pathology of heart in broiler chicks. Twenty broiler chicks were taken for the experiment. One control group and three treated groups. All the treated groups were supplemented with 300mg/kgb.w. (Low dose), 600mg/kgb.w. (Intermediate dose) and 900mg/kgb.w. (High dose) of Zinc for 21 days. Heart was selected for the histopathological study and effects of different levels of zinc were studied in heart tissue. Sections of the heart and blood vessels from the Zn-treated broiler chicks did not differ from their controls and there was no any change was found in the heart of all.

Key words: Zinc, Histopathology, Heart, Broiler chicks.

INTRODUCTION

Little information is available regarding establishment of normal and toxic zinc (Zn) concentrations in birds. However, the upsurge in Zn poisonings in pet birds over the past years has created a need to establish a database in order to interpret Zn analysis accurately. The higher number of Zn poisoning in birds may reflect the more common use of galvanized cages and aviaries, as well as an increased awareness by veterinarians and pet bird owners. Documented causes of avian Zn toxicosis include ingestion of items such as cage coatings, accessories, hardware, [1, 2] and metallic toys [3]. Aside from exposure to toxic Zn concentrations in source material, no cause of elevated serum/plasma or liver Zn concentrations has been documented.

Zinc is required for various physiological processes and is present in over 200 metalloenzymes [4]. These enzymes are involved in bone formation, keratogenesis, reproduction, growth, wound healing, brain development, normal functioning of the central nervous system, and many other physiological processes [5].

Metal ions are generally toxic at a high-dose level; therefore, to study the therapeutic potential of novel metal-based compounds; the acute toxicity level must first be evaluated. Moreover, the compounds containing piperazine moiety were reported to have shown various biological activities in many studies [6] and, specifically, the Schiff bases derived from piperazine compounds have been described to demonstrate various biological activities. Zn intake can have drastic effects, and Zn toxicoses have been reported in numerous animal species [7, 8] and in humans [9].

MATERIALS AND METHODS

Twenty broiler chicks (*Gallus gallus*) of weight ranging from 25-30 gm. were used in the experiments. Broiler chicks were purchased from Gajaria farm, Lucknow. Broiler Chicks were quarantified for 10 days and it was confirmed that they were free of pathogen and any other disease.

Broiler Chicks were kept in conventional condition (open system) and housed in stainless steel cages (800×14cm²) in animal house with room temperature $22\pm 3^{\circ}\text{C}$, relative humidity 50-70%, photo period of 12 hrs. Light and 12 hrs. dark. They were provided with commercial broiler chick starter diet and water *ad libitum*.

The chicks were randomly and equally distributed into four equal groups. The control group received feed without zinc. The second low dose group was given zinc at 300mg/kgb.w., the third intermediate dose group were given zinc at 600mg/kgb.w, and the fourth high dose group were given zinc at 900mg/kgb.w.in the feed for 21 days. At the end of the experiment the heart of broiler chick were selected for further analysis. Heart after being removed from broiler chick was rinsed in saline solution for 2-3 times to remove any blood debris attached on the external surface. Then the heart tissue was cut into small pieces of approximately 4-5mm and was collected in formal saline solution. Paraffin embedded tissue was sectioned to 5 μ thickness and stained by haematoxylin and eosin for histopathological examination.

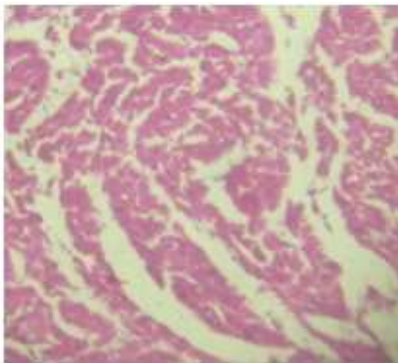


PLATE1a: Heart of control group showing normal architecture. H&E, 100X.

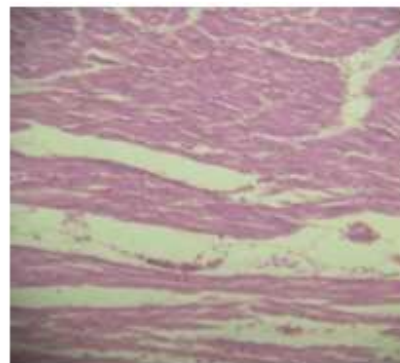


PLATE1b: Heart of Zn (Low dose) treated broiler chicks showing normal architecture, HXE, 100X.

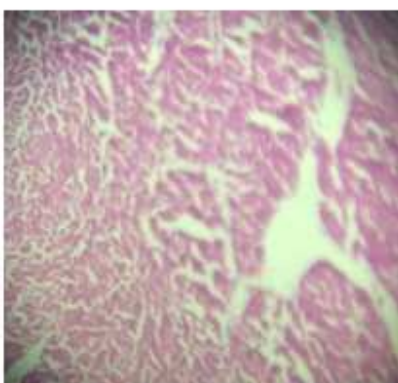


PLATE1c: Heart of Zn (Intermediate dose) treated broiler chicks showing normal architecture, HXE, 100X.

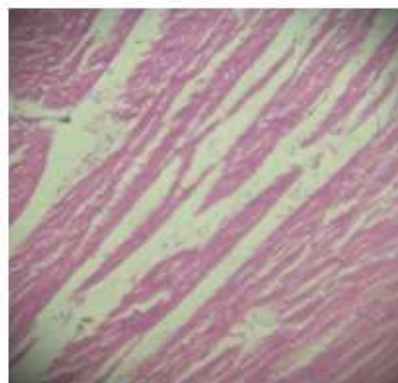


PLATE1d: Heart of Zn (High dose) treated broiler chicks showing normal architecture, HXE, 100X.

RESULTS AND DISCUSSION

Heart of control birds showed normal structure of endocardium, myocardium, epicardium, heart muscles and purkinje fibres(Plate-1a). There was no cardiovascular symptom was observed in all the treated groups.

In low dose (300mg/kg b.w.)(Plate-1b), intermediate dose (600mg/kg b.w.)(Plate-1c) and in high dose (900mg/kg b.w.)(Plate-1d) treated groups there was no change was found in the heart of birds it showed normal structure of endocardium, myocardium, epicardium, heart muscles and purkinje fibres as compared to their respective controls. Contrary to our results some researchers studied the effect of zinc phosphide on the heart muscles of peafowl and found that multifocal mild to moderate degeneration of myofibres with infiltration by small numbers of mononuclear cells was present in all birds [10]. Selenium toxicity has been reported in Tissues of the heart of birds, is particularly susceptible to lipid peroxidation and may be affected during embryonic development [11].

REFERENCES

- [1] Van Sant F: *Proc Annu Conf Assoc Avian Vet*: **1991**, 255–259.
- [2] Zdziarski JM, Mattix M, Bush RM, Montali RJ: *J Zoo Wildl Med* **1994**, 25:438–445.
- [3] Clubb S.: *J Avian Med Surg* **1997**, 11:115–118.
- [4] Prasad AS: Discovery and importance of zinc in human nutrition. *Fed Proc*, **1984**, 43:2829–2834.
- [5] Underwood EJ: Zinc. *In: Trace elements in human and animal nutrition*, ed. Underwood EJ, 4th ed., **1977**, pp. 196–242. Academic Press, New York, NY.
- [6] Keypour, H.; Rezaeivala, M.; Valencia, L.; Perez-Lourido, P. *Polyhedron*, **2008**, 27, 3172–3176.
- [7] Ackerman N, Spencer CP, Sundlof SF, Partridge HL: *Vet Radiol* **1990**, 31:155–157.
- [8] Breitschwerdt EB, Armstrong PJ, Robinette CL, *et al.*: *Vet Hum Toxicol* **1986**, 28:109–117.
- [9] Brown MA, Thom JV, Orth GL, *et al.*: *Arch Environ Health* **1964**, 8:657–660.
- [10] Shivaprasad H. L. and Galey F. *Avian Pathology*, **2001**, 30: 599-603.
- [11] Rani, P. and K. Lalitha. *Biol Trace Elem Res.* **1996**, 51(3): 225-234.